

Small Blue Round Cell Tumor Of The Kidney In Childhood - A Diagnostic Dilemma

V Vennila, R Kalahasthi, M Krishna Boghi, S Veeragandham

Citation

V Vennila, R Kalahasthi, M Krishna Boghi, S Veeragandham. *Small Blue Round Cell Tumor Of The Kidney In Childhood - A Diagnostic Dilemma*. The Internet Journal of Pathology. 2014 Volume 16 Number 1.

Abstract

Neuroblastoma, monophasic Wilms' tumor (blastemal dominant) and rhabdoid tumor are the common renal round cell tumors of early childhood. The treatment modalities of these malignancies are very different. Neuroblastoma arising from the kidney may easily be misdiagnosed as a case of Wilms' tumor. We report a case of small round cell tumor of the right kidney and based on clinical examination, imaging examination and H&E stain we consider it as monophasic Wilms' tumor/rhabdoid tumor. Immunohistochemistry (IHC) confirmed the diagnosis of neuroblastoma resolving the diagnostic dilemma of round cell tumor of the kidney.

INTRODUCTION

Pediatric renal tumors often present in an advanced stage at first clinical examination. The primary differential diagnosis of a large palpable mass related to kidney in a young child includes Wilms' tumor, rhabdoid tumor and neuroblastoma. The location of the mass may prove

useful in preoperatively identifying the origin of these lesions. A mass localized to kidney most common is Wilms' tumor. Intrarenal neuroblastoma is very rare and originates from either adrenal rests found within the renal tissue or from intra renal sympathetic ganglia. Here we report a case of intra renal neuroblastoma (stage 1).

CASE PRESENTATION

An 18 months old female child presented to the paediatric surgery outpatient clinic with chief complaint of low grade fever and mass in the abdomen. No haematuria. Imaging examination showed a heterogeneous mass arising from the upper pole of the kidney. Perinephric tissue was free. Right nephrectomy was done and perirenal fat was excised. Grossly the nephrectomy produced a specimen measuring 12.5x8.5x7cm with a tumor on the upper pole, which was grey brown and bosselated (Fig-1A). Tumor was 8x7x7cm, solid, soft, relatively circumscribed, grey white with reddish brown in color and with haemorrhagic, necrotic areas and gritty cut surface (Fig-1B). Histologically the tumor shows diffuse growth pattern of monophasic small round cells with hyperchromatic nuclei, inconspicuous

nucleoli and scant cytoplasm (Fig-2A). There are areas of attempted rosette formation around central neuropil as well as blood vessels (Fig-2 B&C). Some areas were showing spindle nuclei. The tumor was vascular with extensive areas of necrosis and haemorrhage (Fig-2.A).

Immunohistochemical studies with immunomarkers NSE, Chromogranin A, synaptophysin, GFAP, Vimentin, EMA, Cytokeratin, S-100 & Desmin were done for further categorization of the tumor. Immunohistochemistry of the tumor were strongly positive for NSE, Chromogranin A & Synaptophysin and focally positive for GFAP (Fig-3A,B &C). The tumor cells were negative for Vimentin, EMA, Cytokeratin and Desmin & S-100 protein (Fig-4 A,B,C,D&E). All these features suggest a diagnosis of intra renal neuroblastoma of the right kidney and ruled out a Wilms' tumor and rhabdoid tumor.

Figure 1

A-Tumor kidney with circumscribed and bosselated appearance. B. well demarcated grey white tumor with haemorrhage.

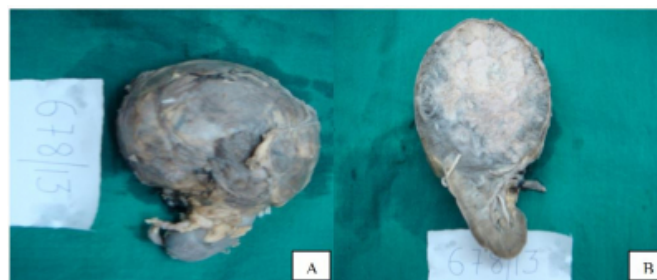


Figure 2

A. Diffusely monotonous small round cells with haemorrhagic and necrotic areas. B and C. Attempted rosette formation of small round cells around neuropil & around blood vessels.

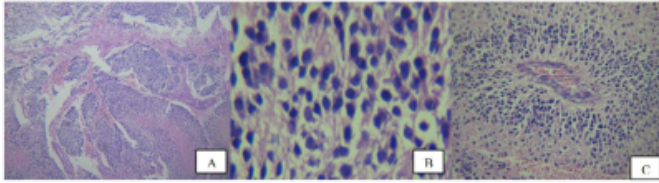


Figure 3

IHC positivity-A: NSE,B. Chromogranin A. C.Synaptophysin

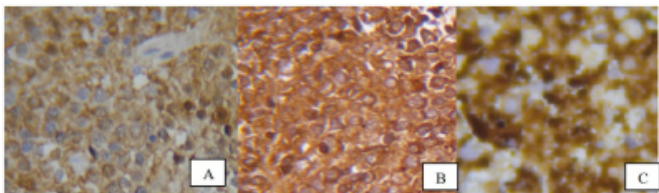
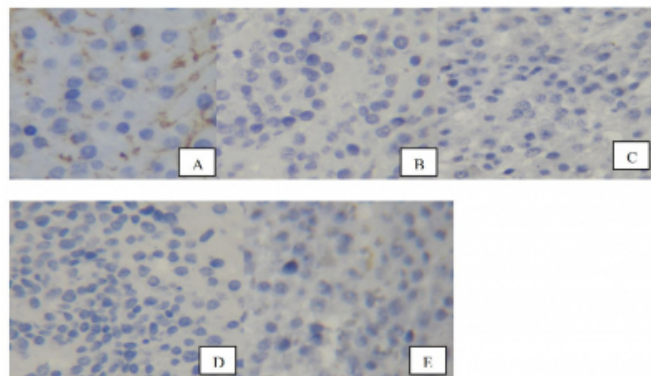


Figure 4

Tumor cells negative for IHC staining - A. Vimentin, B. EMA, C. CK, D. Desmin and E. S-100



DISCUSSION

Primary intrarenal neuroblastoma is a rare clinical entity. It mimics monophasic Wilms tumor (blastemal dominant) or rhabdoid tumor clinically, radiologically and on routine H&E section studies. Each year two to three tumors are registered by National Wilms' Tumor Study Group (NWTSG) as blastemal type and are identified after central review as poorly differentiated or undifferentiated stroma-poor neuroblastoma [1]. The majority of these masses are clinically confined to the kidney, and the correct diagnosis is documented only following nephrectomy [1]. Intrarenal neuroblastoma is believed to originate from either sequestration of adrenal medullary tissue in the kidney

during the fetal development, or from intrarenal sympathetic ganglion or extension of aggressive adrenal neuroblastoma into the kidney. Neuroblastoma is the most common extra-cranial solid tumor of childhood and accounts for 50% of neonatal malignancies. Half of these tumors present before 2 years of age, and 75% before 4 years. It is rare in children older than ten years. Neuroblastoma can occur anywhere along the neuroectodermal sympathetic chain, from head to pelvis, with adrenal medulla being the commonest site (50-70%). Neuroblastoma is an aggressive malignancy as compared to Wilms' tumor and usually presents with secondaries at the time of initial presentation in approximately 75% of the patients. Renal invasion by neuroblastoma occurs by direct penetration through the renal capsule and or lymphatic perivascular spread. When the lesion is localized, it is generally curable with favorable histological features. The ratio of adrenal to extra-adrenal primary site is approximately 1.5 to 2:1. In about 10% of cases it is not possible to establish the primary site of origin with certainty [2]. Six of such cases were identified in the National Wilms' Tumor Study Pathology Centre in 1993 [3]. Ultrasonogram and computed tomography determines its position in relation to adrenal, kidney, and other intraabdominal and retroperitoneal organs. MRI and bone scans are helpful to detect metastases.

Urinary catecholamines may be negative and the imaging modalities may at times be unable to differentiate between neuroblastoma and Wilms' tumor / rhabdoid tumor. However, there is always a risk of 5-10% of misdiagnosis on these imaging modalities. In our case also urinary catecholamines were negative and imaging examination was unable to differentiate the tumor. Review of literature suggested that intrarenal origin or extension of neuroblastoma from adrenal gland may be confused with Wilms' tumor [4,5,6,7]. In such situations radiological correlation, urinary catecholamines levels, immunohistochemistry, cytogenetics studies would be helpful in establishing the diagnosis [4,5,6,7]. In our case, though genetics was not performed and catecholamines were negative, negativity for vimentin, cytokeratin, EMA, S-100 protein and Desmin & NSE, Synaptophysin and Chromogranin A positivity on immunohistochemistry clinched the diagnosis of neuroblastoma. Lall et al studied in three children between two months and four years diagnosed as intrarenal neuroblastoma and found that differentiation between Wilms' tumor and intrarenal neuroblastoma is imperative as the correct preoperative diagnosis would be important in the management of these cases [8].

With the advent of CT and MRI, the differentiation of neuroblastoma from Wilms' tumor has improved dramatically. Application of immunohistochemistry and detection of N-myc amplification and 1p deletion has greatly facilitated in differentiating neuroblastoma from other small round cell tumor of childhood. Intrarenal neuroblastoma is usually associated with a poor prognosis as the tumor presents with secondary metastasis at the time of the initial presentation.

The treatment of Wilms' tumor is successful with remission in 80% of children, with less than 20% experiencing serious morbidity at twenty years from diagnosis [9]. Outcomes remain poor in neuroblastoma despite intensive treatment. The bortezomib-doxorubicin combination is effective for neuroblastoma [10,11]. Neuroblastoma, because of its unique biology, continues to be a challenging tumor to treat, and many times these tumors are refractory to standard chemotherapeutic regimens. Trichostatin A (TSA) and Interferon-beta has a significant antitumor activity against neuroblastoma[12]. A high proportion of intrarenal neuroblastoma are of unfavorable histology as defined by the International Neuroblastoma Pathology Classification and have a higher incidence of anaplasia (32%) when compared to both their adrenal counterparts and to Wilms' tumor. The factors that affect survival are age and health of child, extent of the disease, size, type and location of the tumor, metastasis, tumors response to therapy and overall child's tolerance to medications. Clinical, radiological and pathological correlation is very essential for diagnosis and appropriate management of this type of unusual cases.

CONCLUSION

To conclude, in this case of small round cell tumor arising from the right kidney, immunohistochemistry played a pivotal role in confirming the diagnosis of neuroblastoma thereby, resolving the diagnostic dilemma of small round cell tumor of right kidney.

ABBREVIATIONS

NSE:Neuron Specific enolase; EMA:Epithelial membrane antigen; GFAP: Glial fibrillary acidic protein; NWTSG:National Wilms' Tumor Study Group.

References

1. Murphy MW, Grignon JD, Perlman JE: Tumors of the Kidney, Bladder and related urinary structures. Fourth series, Fascicle 1. American Registry of Pathology 2004:28-29.
2. Delellis AR, Mangray S: The adrenal gland. In: Stacey E. Mills, Darryl Carter, Victor E. Reuter, Joel K. Greenson, Marck H Stoller, Harold A. Oberman. Sternberg's diagnostic surgical pathology. 4th ed.Lippincott Williams &Wilkins; 2004:621-667.
3. Parham DM: Neuroblastoma: In: Eble J. N., Sauter G., Epstein J. I., Sesterhem. I. A., eds. Pathology and Genetics of Tumours of the urinary system and male genital organs. IARC Press Lyon; 2004:84-85.
4. Rosenfield NS, Leonidas JC, Barwick KW: Aggressive neuroblastoma simulating Wilms tumor. Radiology1988, 166:165-167.
5. Dickson PV, Sims TL, Streck CJ, McCarville MB, Santana VM, McGregor LM, Furman WL, Davidoff AM: Avoiding misdiagnosing neuroblastoma as Wilms tumor. Pediatr Surg 2008, 43:1159-1163.
6. Hyun JP, Sang DL, Chang HL: Intrarenal neuroblastoma mimicking Wilms tumor. Korean J Urology 2003, 44:380-382.
7. Serrano R, Rodriguez-Peralto JL, De Orbe GG, Melero C, de Agustin P: Intrarenal neuroblastoma diagnosed by fine needle aspiration: a report of two cases. Diagn Cytopathol 2002, 27:294-297.
8. Lall A, Bajpai M, Gupta DK: Intrarenal neuroblastoma a diagnostic dilemma: a report of three cases. J Ind Assoc Pediatr Surg 2002, 7: 276-279.
9. Kaste SC, Dome JS, Babyn PS, Graf NM, Grundy P, Godzinski J, Levitt GA, Jenkinson H: Wilms tumor:prognostic factors, staging, therapy and late effects. Pediatr Radiol 2008, 38:2-17.
10. Armstrong MB, Schumacher KR, Mody R, Yanik GA, Opiari AW Jr, castle VP: Bortezomib as a therapeutic candidate for neuroblastoma. J Exp Ther Oncol 2008, 7:135-145.
11. Spreafico F, Bellani FF: Wilms' tumor: past, present and (possibly) future. Expert Rev anticancer Ther 2006, 6:249-258.
12. Hamner JB, Sims TL, Cutshaw A, Dickson PV, Rosati S, McGee M., et al.: The efficacy of combination therapy using adeno-associated virus-interferon beta and trichostatin A in vitro and in a murine model of neuroblastoma. J Pediatr Surg 2008, 43:177-183.

Author Information

Vijayasree Vennila

Assistant Professor, Dept. of Pathology, Kamineni Institute of Medical Sciences (KIMS)
Sree Puram, India
vijayasree_vennila@yahoo.co.in

Raghu Kalahasthi

Associate Professor, Dept. of Pathology, Kamineni Institute of Medical Sciences (KIMS)
Sree Puram, India
kalahastiraghu@gmail.com

Murali Krishna Boghi

Assistant Professor, Dept. of Pathology, Kamineni Institute of Medical Sciences (KIMS)
Sree Puram, India
coolkris1@gmail.com

Sathyanarayana Veeragandham

Professor & HOD, Dept of Pathology, Kamineni Institute of Medical Sciences (KIMS)
Sree Puram, India
drsatya196veeragandham@gmail.com