

# Role Of Coracoid Morphometry In Subcoracoid Impingement Syndrome

S Rajan, S Ritika, K J.S., S R Kumar, S Tripta

## Citation

S Rajan, S Ritika, K J.S., S R Kumar, S Tripta. *Role Of Coracoid Morphometry In Subcoracoid Impingement Syndrome*. The Internet Journal of Orthopedic Surgery. 2014 Volume 22 Number 1.

## Abstract

**INTRODUCTION :** Subcoracoid impingement syndrome is a less common cause of shoulder pain. It occurs when the subscapularis tendon impinges between coracoid and lesser tuberosity of the humerus. The variations in height and length of the coracoid process are held responsible for altering the shape of the space between coracoacromial arch and rotator cuff. Apart from these, other morphometric parameters of the coracoid process may also play some role.

**MATERIALS AND METHODS:** The study was conducted on 100 dry scapulas (R:L = 50:50) obtained from The Department of Anatomy, Government Medical College, Amritsar. Different parameters such as length, breadth, height, thickness of the coracoid process, height of the supraglenoid tubercle to the under surface and superior surface of the coracoid process as well as coracoglenoid distances were measured. The mean values were calculated and compared with the earlier studies. An attempt has been made to discuss the role of these parameters in causation of subcoracoid impingement syndrome.

**RESULTS:** The mean values for different parameters as observed in the present study were mean length = 40.43 mm, breadth = 13.77 mm, height = 15.62 mm, thickness = 7.83 mm, height of supraglenoid tubercle from under surface of the coracoid process = 15.18 mm, height of supraglenoid tubercle from superior surface of the coracoid process = 21.59 mm and coracoglenoid distance = 27.05 mm.

**CONCLUSION:** Our study provides a base line data for different morphometric parameters of the coracoid process and discusses the role of these parameters in the aetiology of subcoracoid impingement syndrome which will be helpful in the management of the same to the orthopaedician.

## INTRODUCTION

The geometric anatomy of the scapula is of fundamental importance in the pathomechanics of rotator cuff disease, total shoulder arthroplasty and recurrent shoulder dislocation<sup>1</sup>. The mechanical impingement on the rotator cuff by the overlying acromial arch and the possibility of rotator cuff impingement by its anteromedial part i.e. the coracoid process was postulated as early as 1909<sup>2</sup>. The coracoacromial anatomy includes the acromion, the coracoacromial ligament, and the tip of the coracoid process<sup>3</sup>. It is the variation in the height and length of the coracoid process which is responsible for altered size and shape of the space between the coracoacromial arch and the rotator cuff<sup>4</sup>. It has also been suggested that the problem is functional with anterior instability leading to a narrowing of the coracohumeral distance<sup>5</sup>.

The subcoracoid space is occupied in vivo by several soft

tissue structures, such as the articular capsule of the glenohumeral joint, the subscapularis tendon and the subacromial bursa. The thickness of these tissues may vary but variations are small and do not affect the width of the subcoracoid space unless there is local pathology. The shape and size of this space depends on its limiting skeletal structures<sup>2,6</sup>. Therefore, anatomical morphometric studies of these structures may provide information as to the aetiology of the subcoracoid impingement syndrome.

The coracoid process also forms an important part of the scapular glenoid construct and is involved in many surgical procedures on the glenohumeral joint<sup>7</sup>. Its detailed morphometry is useful in surgical procedures such as hardware fixation, drill hole placement and prosthetic positioning<sup>8</sup>. Congenital variations and minimal traumatic/iatrogenic changes in this orientation can predispose to subcoracoid dislocation<sup>7</sup>.

### MATERIALS AND METHODS

The material for the present study comprised of 100 adult scapulae of unknown sex and age, obtained from the department of Anatomy, Government Medical College, Amritsar, Punjab, India. These were labelled from 1-100 with suffix R (right) or L (left). Of the 100 bones, 50 were of the right side and 50 were of the left side. All the bones were free from any physical deformity or abrasion and were complete in all respects. The following parameters were measured on the coracoid process:

a) Maximum length: It was measured with the help of vernier calipers from most anterolateral to most posteromedial extension of the coracoid process<sup>9</sup> (AB in Fig.1).

b) Maximum breadth: It was measured with the help of vernier calipers as the maximum width from lateral border to the medial border of the coracoid process<sup>10</sup> (CD in Fig.1).

c) Height of the coracoid process: It was measured with vernier calipers as the distance between supraglenoid tubercle to the top of the ascending portion of the coracoid process along the glenoid axis<sup>11</sup> (AB in Fig.2).

d) Thickness: It was measured with the vernier calipers in the superoinferior direction 1 cm posterior to the tip of the coracoid<sup>7</sup>.

e) Coracoglenoid distance (termed as Co-gle by Gallino et al<sup>12</sup>): It was measured with the vernier calipers as the distance between the tip of the coracoid process to the medial anterior point of the circumference of the glenoid cavity<sup>12</sup> (AB in Fig.3).

f) Height from supraglenoid tubercle to:

i) Under surface of coracoid process: It was measured with the vernier calipers as the distance between upper part of supraglenoid tubercle to the mid point of undersurface of the coracoid process (AC in Fig.2).

ii) Superior surface of coracoid process: It was measured with the vernier calipers as the distance between upper part of supraglenoid tubercle to the midpoint of superior surface of the coracoid process (AD in Fig.2).

**Figure 1**

AB : Maximum length of the coracoid process CD : Maximum breadth of the coracoid process

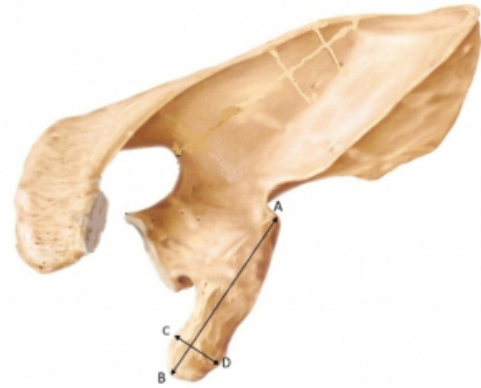


Fig 1

AB : Maximum length of coracoid process  
CD : Maximum breadth of coracoid process

Figure 2

AB : Height of the coracoid process AC: Height of supraglenoid tubercle to under surface of the coracoid process AD: Height of supraglenoid tubercle to superior surface of the coracoid process



Fig -2

AB : Height of coracoid process  
AC: Height of supraglenoid tubercle to undersurface of coracoid process  
AD: Height of supraglenoid tubercle to superior surface of coracoid process

Figure 3

AB : Coracoglenoid Distance



Fig-3

AB : Coracoglenoid Distance

RESULTS

Table 1 depicts the mean value and range of different parameters as observed in the present study and compares the same with the earlier studies.

Table 1  
Showing Comparisons Of Different Parameters Of Coracoid Process

[ Mean (Range)] All values in mm.

Author	ChadKang <sup>10</sup>	Gallino et al <sup>12</sup>	Geminet al <sup>13</sup>	Van Schroeder et al <sup>14</sup>	Pivarnik et al <sup>15</sup>	Coskun et al <sup>16</sup>	Present Study
Population(s)	Korean(185)	Egyptian(266)	Italian(204)	Canadian(10)	Thai(97)	Turkish(90)	North Indian(100)
							Right Left
Length		41.10 (16.3-54.4)		45.30 (35-54)	37.80 (33.3-51.3)	19.40 (10-77.5)	40.43(29.8-51.07) 40.70(29.8-51.03) 40.16(31.52-51.07)
Breadth					13.5 (10.8-18.1)		13.77(9.6-18.04) 13.08(9.0-18.04) 13.47(9.98-17.73)
Height	12.8				8.8 (2.0-19.0)	14.6 (9.5-21.2)	15.62(8-24) 15.70(8-24) 15.53(10-20)
Thickness			7.19 (5-10.2)	10.6 (8-12)	6.8 (4.8-10)	7.83 (5.61-10.79)	7.83(5.61-10.79) 7.85(5.64-10.79) 7.85(5.64-10.79)
Coracoglenoid Distance		21	16.23 (11.8-22.1)	56.7 (40-58)	14.8 (10.4-21.0)		27.05(18.84-33.98) 27.53(18.84-33.97) 26.56(21.13-33.98)
Height of supraglenoid Tubercle to undersurface of coracoid process							19.14(9.23-22.53) 14.08(9.23-20.13) 18.31(11.88-22.53)
Height of supraglenoid tubercle to superior surface of coracoid process							21.59(13.35-31.33) 21.46(15.24-31.33) 21.72(13.35-27.36)

DISCUSSION

A true coracoid process is present only in humans and in the non-human primates as a result of the adaptation of moving

the upper limbs in a wide range of usually anterior motion. The coracoid process is usually absent in most quadrupeds, reduced to a simple thickening of the supraglenoid tubercle. A representation of the coracoid as an uncinat process is present in most rabbits and rodents, which maintain a certain degree of upper limb mobility in the forward position and in powerful gripping. In all these animals the origin of the short head of the biceps is missing<sup>15</sup>. From this perspective the coracoid assumes a biomechanical function of a shelf-structure, which is one arm of the lever through which the muscular action of the coracobrachialis, biceps and pectoralis minor muscles exerts a force on the glenoid. Numerous paths of open surgical or arthroscopic access to the shoulder refer to the coracoid<sup>16</sup> which has been aptly defined by Matsen et al<sup>17</sup> as “the lighthouse of the shoulder”. It has been observed that the position of the apex of the coracoid process varies from one individual to another<sup>18</sup>.

### 1. Maximum length of the coracoid process

The mean length of the coracoid process was observed to be 40.43 mm (Range = 29.80-51.07 mm). On the right side, it was 40.70 mm (Range = 29.80-51.03 mm) whereas on the left side, it was 40.16 mm (Range = 31.52-51.07 mm). Thus, the values for the right side were slightly more than the left side.

Earlier Gallino et al<sup>12</sup>, Von Schroeder et al<sup>8</sup>, Piyawinijwong et al<sup>10</sup> and Coskun et al<sup>14</sup> have measured this parameter (see Table 1). It is evident that our results are close to those of Gallino et al<sup>12</sup>.

**Clinical Implication:** While Codman<sup>19</sup> expressed doubt about existence of idiopathic subcoracoid impingement syndrome, Gerber et al<sup>20</sup> blamed a long coracoid process for the same. It was further supported by Dines et al<sup>21</sup> who treated all seven patients of coracoid impingement by surgical excision of the coracoid tip.

### 2. Maximum breadth of the coracoid process

The mean breadth of the coracoid process was found to be 13.77 mm (Range = 9.60-18.04 mm). On the right side, it was 13.68 mm (Range = 9.60-18.04 mm) whereas on the left side, it was 13.87 mm (Range = 9.98-17.73 mm). On comparing the two sides, it was seen that there was slight difference between the values of both the sides with slightly higher value for the left side.

Piyawinijwong et al<sup>10</sup> had also measured this parameter

before and found the value to be 13.5 mm (Range = 10.8-18.1 mm) which is almost similar to the one found in the present study.

### 3. Height of the coracoid process

The mean height of the coracoid process was 15.62 mm (Range = 6.0-24.0 mm). On the right side, it was 15.71 mm (Range = 6.0-24.0 mm) whereas on the left side, it was 15.53 mm (Range = 10.0-20.0 mm). Thus, it was seen that there was slight difference between the values of both the sides with slightly higher value for the right side.

Earlier Cho and Kang<sup>11</sup>, Piyawinijwong et al<sup>10</sup> and Coskun et al<sup>14</sup> had measured this parameter. It is evident from table 1 that our results are near to those of Coskun et al<sup>14</sup>.

### 4. Thickness of the coracoid process

The mean thickness of the coracoid process was 7.83 mm (Range = 5.61-10.79 mm). On the right side, it was 7.80 mm (Range = 5.61-10.79 mm) whereas on the left side, it was 7.85 mm (Range = 5.64-10.21 mm). Thus, it was slightly higher on the left side.

Table 1 compares the studies already undertaken by Gumina et al<sup>13</sup>, Von Schroeder et al<sup>8</sup> and Piyawinijwong et al<sup>10</sup>. Our results were in consonance with those of Gumina et al<sup>13</sup>.

### 5. Coracoglenoid distance

The mean value for coracoglenoid distance was 27.05 mm (Range = 18.84-33.98 mm). On the right side, it was 27.53 mm (Range = 18.84-33.37 mm) whereas on the left side, it was 26.56 mm (Range = 21.13-33.98 mm). Thus, it was higher on the right side than the left side.

Table 1 compares our study with those performed earlier. While Gumina et al<sup>13</sup> and Piyawinijwong et al<sup>10</sup> found it to be 16.23 mm and 14.8mm, Von Schroeder et al<sup>8</sup> found it to be 50.7 mm. Such a wide variation in the value of this parameter in these two studies is unexplainable. However, our values fall in between these two studies (vide supra).

Gallino et al<sup>12</sup> reported that surgical techniques that recommend transporting the coracoid to the anterior rim of the glenoid fossa to stabilize the glenohumeral joint in recurrent dislocation<sup>22,23</sup> are successful. Because the distance from the apex of the coracoid and the mid-anterior point of the glenoid rim is on average 2.10 cm with a minimum of 1.09 cm in the smallest scapula. In such

interventions the point of application of the force of the coracobrachialis and biceps muscles would be significantly nearer to the geometric center of the joint and would thus create more stability. However, the mean value of this distance in the present study was found to be on a higher side as compared to theirs. Also the minimum distance on smallest scapula was larger than that.

### 6. Height from supraglenoid tubercle to

#### i. Undersurface of the coracoid process:

The mean height from the supraglenoid tubercle to the undersurface of the coracoid process was found to be 15.18 mm (Range = 9.23-22.53 mm). On the right side, it was 14.06 mm (Range = 9.23-20.13 mm) whereas on the left side, it was 16.31 mm (Range = 11.68-22.53 mm). On comparing the two sides, it was seen that the mean value on left side was higher than the right side.

#### Clinical Implication:

(a) Gumina et al<sup>13</sup> had blamed severe narrowing of coracoglenoid space as a risk factor for development of idiopathic subcoracoid impingement syndrome. Thus a knowledge of this distance is important for assigning the risk of this syndrome to any patient.

(b) Renoux et al<sup>4</sup> opened that it is the height and length of the coracoid process which is responsible for altering the size and shape of space between the coracoacromial arch and rotator cuff. If these are diminished, the chances of idiopathic subcoracoid impingement syndrome increase and vice versa.

#### ii. Superior surface of the coracoid process:

The mean height of the supraglenoid tubercle to the superior surface of the coracoid process was found to be 21.59 mm (Range = 13.35-31.33 mm). On the right side, it was 21.46 mm (Range = 15.24-31.33 mm) whereas on the left side, it was 21.72 mm (Range = 13.35-27.36 mm). When comparing the two sides, it was also found to be increased on the left side.

Thus the study provides a baseline data for the various morphometric parameters of the coracoid process. Also an attempt has been made to discuss their clinical importance in causation of idiopathic subcoracoid impingement syndrome. These values of different parameters of coracoid process may be useful for the orthopaedicians dealing with this entity.

## CONCLUSIONS

To summarise, the present study discusses the role of various parameters of the coracoid process in the aetiology of subcoracoid impingement syndrome and also provides a base line data for the same. These findings could be of great value in the further exploration of their role in causation and surgical management of this syndrome.

## References

1. Mallon WJ, Brown HR, Vogler JB 3rd, Martinez S. Radiographic and geometric anatomy of the scapula. *Clin Orthop Relat Res* 1992; (277): 142-54.
2. Goldthwait JE. An anatomic and mechanical study of the shoulder joint, explaining many of the cases of painful shoulder, many of the recurrent dislocations, and many of the cases of brachial neuritis. *Am J Orthop Surg*. 1909; 6: 579-606.
3. Roche SJ, Kennedy MT, Butt AJ, Kaar K. Coracoid impingement syndrome: A treatable cause of anterior shoulder pain. *Ir J Med Sci Jul-Sep*. 2006; 175(3): 57-61. [Pubmed]
4. Renoux S, Manet J, Pupin P, Collin M, et al. Preliminary note on biometric data relating to the human coracoacromial arch. *Surg Radiol Anat*. 1986; 8: 189-195. Doi: 10/13/13.
5. Radas CB, Pieper HG. The coracoid impingement of the subscapularis tendon: a cadaver study. *J Shoulder Elbow Surg*. 2004; 13(2): 154-159. Doi: 10/13/13
6. Meyer AW. Chronic functional lesions of shoulder. *Arch Surg* 1937; 35: 646-74.
7. Bhatia DN, de Beer JF, du Toit DF. Coracoid process anatomy : implications in radiographic imaging and surgery. *Clin Anat* 2007; 20(7): 774-84.
8. Von Schroeder HP, Kuiper SD, Botte MJ. Osseous Anatomy of the Scapula. *Clin Orthop Relat Res* 2001; (383): 131-9.
9. Corruccini RS, Ciochon RL. Morphometric affinities of the human shoulder. *Am J Phys Anthropol* 1976; 45(2): 19-38.
10. Piyawinijwong S, Sirisathira N, Chuncharunee A. The Scapula: Osseous Dimensions and Gender Dimorphism in Thais. *Siriraj Hosp Gaz* 2004; 56(7): 356-65.
11. Cho BP and Kang HS. Articular facets of the coracoclavicular joints in Koreans. *Acta Anat (Basel)* 1998; 163(1): 56-62.
12. Gallino M, Santamaria E, Doro T. Anthropometry of the scapula: Clinical and surgical considerations. *J Shoul Elb Surg* 1998; 7(3): 284-91.
13. Gumina S, Postacchini F, Orsina L, Cinotti G. The morphometry of the coracoid process – its aetiologic role in subcoracoid impingement syndrome. *Int Orthop* 1999; 23(4): 198-201.
14. Coskun N, Karaali K, Cevikol C, Demirel BN, Sindel M. Anatomical basics and variations of the scapula in Turkish adults. *Saudi Med J* 2006; 27(9): 1320-25.
15. Barone R. *Anatomia comparata degli animali domestici*. Bologna: Edagricole 1981: 381-95. Cited by Gallino M, Santamaria E, Doro T. Anthropometry of the scapula : Clinical and surgical considerations. *J Shoul Elb Surg* 1998; 7(3): 284-91.
16. Randelli M, Gambrioli PL, Minola R, Odella F. *Technique chirurgiche della spalla*. Bologna: Aulo Gaggi 1992: 66-7. Cited by Gallino M, Santamaria E, Doro T. Anthropometry of the scapula : Clinical and surgical considerations. *J Shoul Elb Surg* 1998; 7(3):

284-91.

17. Matsen FA, Thomas SC, Rockwood CA. Anterior glenohumeral instability. In: The shoulder. Rockwood CA, Matsen FA, editors. Philadelphia. WB Saunders; 1990. p. 336-67.

18. Edelson JG, Taitz C. Anatomy of the coracoacromial arch. Relation to degeneration of the acromion. J Bone Joint Surg Br 1992; 74: 589-94.

19. Codman EA. The shoulder: rupture of the supraspinatus and other lesions in or about the subacromial bursa. Kreigen Malabar, Florida. 1984.

20. Gerber C, Terrier F, Ganz R. The role of the coracoid process in the chronic impingement syndrome. J Bone Joint

Surg (Br) 1985; 67: 703-8.

21. Dines DM, Warren RF, Inglis AE, Pavlov H. The coracoid impingement syndrome. J Bone Joint Surg [Br] 1990; 72: 314-6.

22. Helfet AJ. Coracoid transplantation for recurring dislocation of the shoulder. J Bone Joint Surg [Br] 1958; 40B: 198-202.

23. Latarjet M. A propos du traitement des luxations recidivantes de l'épaule. Lyon Chirurgie 1954; 49: 994-1003. Cited by Gallino M, Santamaria E, Doro T. Anthropometry of the scapula : Clinical and surgical considerations. J Shoul Elb Surg 1998; 7(3): 284-91.

**Author Information**

**Sharma Rajan**

Assistant Professor, Department of Orthopaedics, Sri Guru Ram Das Institute of Medical Sciences and Research  
Punjab, India

**Sharma Ritika**

Assistant Professor, Department of Anatomy, Chintpurni Medical College  
Punjab, India

**Kullar J.S.**

Associate Professor, Department of Anatomy, Government Medical College  
Punjab, India

**Singla Rajan Kumar**

Additional Professor, Department of Anatomy, Government Medical College  
Punjab, India

**Sharma Tripta**

Professor and Head, Department of Anatomy, Punjab Institute of Medical Sciences  
Jalandhar, India