

# Autoimmune Hepatitis And Primary Sclerosing Cholangitis – Overlap Syndrome

Y Dawkins, M Mills, T Murphy, M G Lee, B Hanchard

## Citation

Y Dawkins, M Mills, T Murphy, M G Lee, B Hanchard. *Autoimmune Hepatitis And Primary Sclerosing Cholangitis – Overlap Syndrome*. The Internet Journal of Gastroenterology. 2014 Volume 14 Number 1.

## Abstract

Autoimmune hepatitis (AIH) usually exists as a single entity but rarely occurs in combination with either primary sclerosing cholangitis (PSC) or primary biliary cirrhosis (PBC) as a part of an overlap syndrome. Each of these overlap syndromes has its own characteristic features. We report on a case of autoimmune hepatitis with subsequent development of primary sclerosing cholangitis and ulcerative colitis. Identification of patients with overlap syndrome is important as they typically have a poorer response to steroid therapy, enter remission less frequently and fail therapy more commonly.

## INTRODUCTION

Autoimmune hepatitis (AIH) is an autoimmune disease associated with chronic inflammation of the liver of unknown etiology, characterized by autoantibodies, hypergammaglobulinemia and interface hepatitis. AIH is associated with dramatic response to immunosuppression and good prognosis with remission and prevention of cirrhosis in most patients. It usually exist as a distinct entity but rarely occurs in combination with either primary sclerosing cholangitis (PSC) or primary biliary cirrhosis (PBC) as a part of an overlap syndrome 1. Each of these overlap syndromes has its own characteristic features. Treatment of these overlap syndromes usually involves the use of high dose ursodeoxycholic acid and some patients may also respond to immunosuppressive agents such as azathioprine or cyclosporine 2. However, PSC does not usually respond to immunosuppressive therapy 3. Malignancy of the biliary tree is more common in this population of patients 2.

We report on a case of autoimmune hepatitis with subsequent development of primary sclerosing cholangitis and ulcerative colitis or overlap syndrome.

## CASE PRESENTATION

A 41 year old female of African descent was diagnosed with Autoimmune Hepatitis Type 1 for the past ten years. She had presented with a history of diarrhea, jaundice, joint pains and intermittent fever. On examination she was anicteric with a liver span of 12 cm. Investigations revealed positive anti-

smooth muscle antibody and hypergammaglobulinemia, predominantly immunoglobulin G. The liver biopsy revealed structural alterations, which were indicative of chronic active hepatitis. These include portal tract expansion due to fibrosis and mononuclear inflammatory cell infiltration with piecemeal necrosis as well as the lobular parenchyma showed evidence of regeneration with thickening of liver cell plates and cytoplasmic pallor (Fig 1A). The anti-nuclear antibody was reactive. She was treated with prednisone with clinical and biochemical remission. However, therapy was complicated by steroid induced diabetes mellitus.

She presented to the outpatient Gastroenterology clinic at the University Hospital of the West Indies (UHWI) for a regular follow-up visit and complained of a four month history of cutaneous ulcers to her left flank, epigastrium and left thigh with poor response to prescribed antibiotics. At that time she also gave a thirteen year history of intermittent non-bloody diarrhea. Her blood investigations on admission are as follows: Hb 10.9g/dl, platelet 213 x10<sup>9</sup>/L, WBC 6.8x10<sup>9</sup>/L, ESR 16mm/hr, total protein 67g/L, albumin 38 g/L, globulin 29 g/L, Alkaline phosphatase 120 IU/L, GGT 555 IU/L, AST 67 IU/L, direct bilirubin 6 and total bilirubin 7umol/L. Skin biopsy confirmed pyoderma gangrenosum. Flexible sigmoidoscopy revealed superficial ulcers and erythema of the descending, transverse and sigmoid colon and biopsy confirmed chronic active ulcerative colitis.

Her clinical course was complicated by worsening of the liver function tests with a predominantly cholestatic pattern with serum alkaline phosphatase 162 IU/L, GGT 1399 IU/L

and AST 72 IU/L. Abdominal ultrasound revealed that the liver was mildly enlarged and heterogenous in echopattern. She was found to have a positive Perinuclear Anti-Neutrophil Cytoplasmic Antibodies (p-ANCA). Endoscopic retrograde cholangiopancreatography demonstrated normal common bile duct but marked pruning or ductopenia of the intrahepatic ducts (Fig 1). These features on cholangiogram were consistent with a diagnosis of primary sclerosing cholangitis (PSC). In light of her history of autoimmune hepatitis and evidence of PSC and ulcerative colitis, she was assessed as having an overlap syndrome consisting of autoimmune hepatitis and PSC.

Steroids and azathioprine were continued and ursodeoxycholic acid added. After one month she improved clinically with complete resolution of the pyoderma gangrenosum, the liver enzymes returned to her baseline level and symptoms of ulcerative colitis was significantly improved.

### DISCUSSION

Autoimmune hepatitis is associated with a female preponderance 3,4. It is classified into two major types, based on the presence of autoantibodies 5. Type 1 is characterized by the presence of anti-smooth muscle antibodies and anti-nuclear antibodies may also be positive. Type 2 is usually defined by the presence of anti-liver-kidney-microsomal antibody type 1. A third type of AIH has also been described. Confirming the diagnosis of autoimmune hepatitis can be difficult as liver histology is not pathognomonic. Although the presence of autoantibodies is one of the distinguishing features of AIH, there is no single autoantibody with diagnostic significance and specificity for autoimmune hepatitis 5.

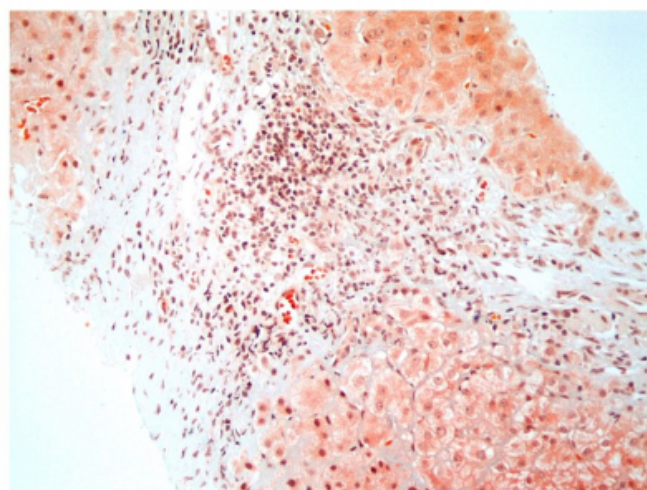
AIH is infrequently associated with other autoimmune conditions such as inflammatory bowel disease, with ulcerative colitis being more common, autoimmune thyroiditis, primary biliary cirrhosis and primary sclerosing cholangitis 2, 3. Since the 1990s, there has been mainly anecdotal reports describing patients with features of both AIH and PSC 3. This combined pathology is referred to as overlap syndrome. The most common forms of overlap syndrome include AIH with PBC or AIH with PSC, with or without ulcerative colitis 6. Our patient has AIH with PSC and ulcerative colitis.

Autoimmune hepatitis typically presents with a predominantly hepatocellular injury pattern of elevated serum transaminases. A predominantly cholestatic picture in

a patient who previously demonstrated a hepatocellular pattern of liver injury, should prompt a search for autoimmune cholangiopathies. Therefore, the overlap syndrome should be suspected when a patient with AIH develops clinical, laboratory or histological features of cholestasis or respond poorly to corticosteroids. The serum alkaline phosphatase level is useful to distinguish classical AIH from its overlap syndromes as a level of more than four-fold above the upper limit of normal do not occur in AIH 7. Interestingly, the time period during which patients present with the various components of an overlap syndrome is quite variable and can occur over decades 2. In our patient PSC was diagnosed some ten years after AIH. The development of an autoimmune cholangiopathy has prognostic implications for patients with established autoimmune hepatitis as they typically have a poorer response to steroid therapy, enter remission less frequently and fail therapy more commonly 7. Therefore, identification of patients with overlap syndrome especially with primary sclerosing cholangitis is important as these patients may have a poorer outcome than patients with AIH.

### Figure 1

Portal tract lymphocytic infiltrate, with active interface hepatitis and bridging necrosis. Regenerative changes with rosettes at lower right. (Masson's trichrome stain)



### References

- 1 Muratori L, Muratori P, Granito A. Current Topics in Autoimmune Hepatitis. *Dig Liver Dis* 2010;42(11):757-764.
- 2 Saich R, Chapman R. Primary sclerosing cholangitis, autoimmune hepatitis and overlap syndromes in inflammatory bowel disease. *World J Gastroenterol*. 2008; 14:331–337.
- 3 Vergani D, Mieli-Vergani G. Autoimmune Hepatitis and PSC Connection. *Clin Liver Dis* 2008;12:187-202.
- 4 McFarlane IG. Definition and Classification of Autoimmune Hepatitis. *Semin Liver Dis*

2002;22(4):317-324.

5 Zachou K, Rigopoulou F, Dalekos GN. Autoantibodies and autoantigens in autoimmune hepatitis: important tools in clinical practice and to study pathogenesis of the disease. J Autoimmune Dis 2004;1:2.

6 Czaja AJ. Frequency and nature of the variant syndromes of autoimmune

liver disease. Hepatology 1998;28:360-365.

7 Czaja AJ. Difficult treatment decisions in autoimmune hepatitis. World J Gastroenterol. 2010;16(8):934–947.

**Author Information**

**Yvonne Dawkins, DM**

Department of Medicine, The University of the West Indies  
Jamaica

**Mike Mills, DM, FACP**

Department of Medicine, The University of the West Indies  
Jamaica

**Trevor Murphy, DM, FACG**

Department of Medicine, The University of the West Indies  
Jamaica

**Michael G Lee, DM,FRCPC,FACP,FACG**

Department of Medicine, The University of the West Indies  
Jamaica

**Barrie Hanchard, FRCPC**

Department of Pathology, The University of the West Indies  
Jamaica