

The Variational Anatomy of the Trapezius Muscle: A Review of the Literature

G Noussios

Citation

G Noussios. *The Variational Anatomy of the Trapezius Muscle: A Review of the Literature*. The Internet Journal of Human Anatomy. 2014 Volume 3 Number 1.

Abstract

The trapezius muscle belongs to the muscles of the trunk and is located at the upper dorsal part of the thorax. It presents with anomalies rarely, discovered either clinically, intraoperatively or after anatomical examination of cadavers. This paper includes recent studies and reports about the variations of the trapezius muscle that have been reported in literature. The research was undertaken electronically using Medline and Embase and all related articles found were carefully assessed. The search produced many articles. 15 articles were finally chosen for discussion in this review study due to their interest. The variations that we discovered in bibliography were: absence of a part of the muscle, aplasia of the whole muscle, appearance of accessory parts on the muscle and variations in its innervations.

INTRODUCTION

The trapezius muscle is a flat triangularly shaped muscle. Its base is found across the spinal cord (origin of the muscle) and its top is located at the upper part of the shoulder (insertion)¹. The trapezius muscle appears with a long origin from the skeleton that concludes the base of the cranium and the vertebrae from C1 to T12 (Fig.1,2). From the C1 to the T7 vertebra, the muscle originates from the cervical ligament². The trapezius muscle inserts into the skeletal part of the shoulder across a semicircular line of insertion, orientated at the horizontal level with the lowest part of the curve, when turned laterally. The right and left trapezius muscles form a shape that looks like a trapezium, hence the name (Fig.3). The trapezius muscle is a strong elevator of the shoulder and it turns and elevates the shoulder, simultaneously¹.

It receives motor innervation from the spinal accessory nerve (cranial nerve XI) originating from the cervix to the deepest surface of the muscle. Proprioceptive nerve fibres arise from the muscle (nerves that carry information about movements and location of the body) and connects to the cervical plexus and spinal cord at the C3 and C4 myelotomes².

The literature review intends to identify variations and anomalies of the muscle.

Figure 1

Left Normal Trapezius Muscle.

{http://en.wikipedia.org/wiki/Trapezius_muscle}

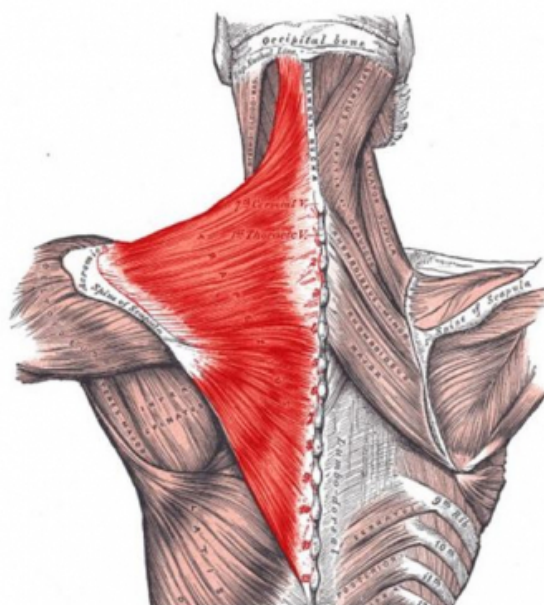


Figure 2

Left Normal Trapezius Muscle. (appears with a long origin from the skeleton that concludes the base of the cranium and the vertebrae from C1 to T12)
{http://en.wikipedia.org/wiki/Trapezius_muscle}

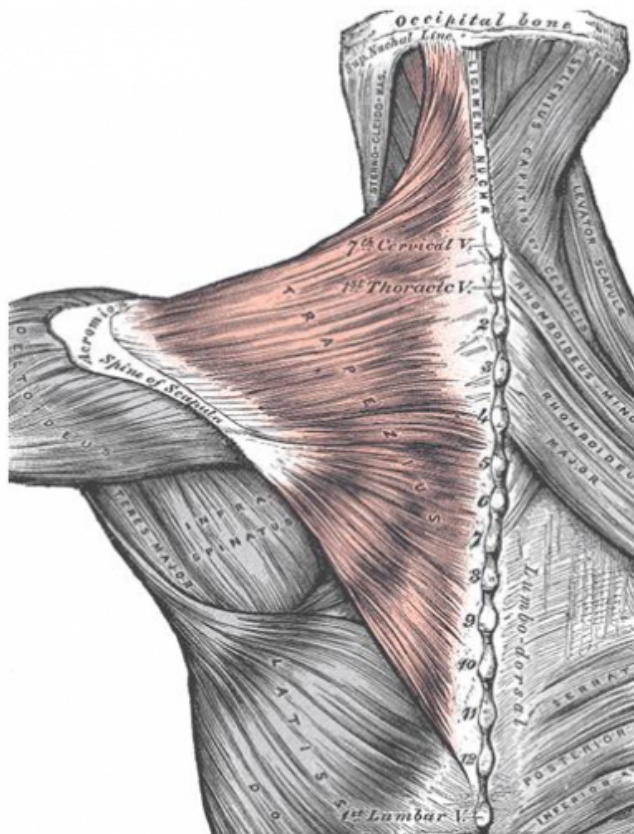
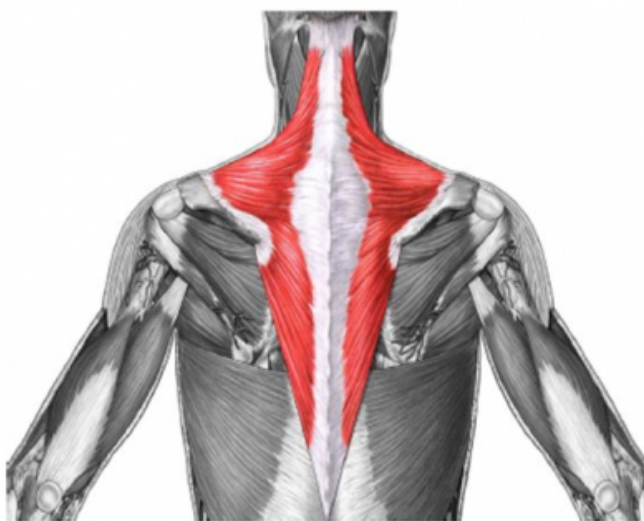

Figure 3

Left and Right Normal Trapezius Muscles. {
<http://imgarcade.com/1trapezius-muscle-origin-and-insertion>}



MATERIALS AND METHODS

The research was undertaken electronically using Medline and Embase and all related articles from 1932 to 2011 found were carefully assessed. The search produced many articles. 15 articles were finally chosen for discussion in this review study due to their interest. The variations that we discovered in bibliography were: absence of a part of the muscle, aplasia of the whole muscle, appearance of accessory parts on the muscle and variations in its innervations.

MORPHOLOGICAL VARIATIONS OF THE TRAPEZIUS MUSCLE - REVIEW OF THE LITERATURE.

Emsley and Davis³ reported a morphological anomaly, detected in the trapezius muscle of a cadaver, during a typical anatomical dissection. The cadaver was an 89 year old man who died from pneumonia due to multiple organ failure. Researchers found that the left trapezius muscle was significantly smaller than the right trapezius, especially in the lower part. They also noted that fibres of the left trapezius muscle (located inferiorly to the scapula) were one to two-third thick when compared with fibres on the other side. Also, the surface area of the left trapezius was only 50% of the right trapezius, as indicated from the morphometric analysis. Moreover, along the left and right side, an important difference was found in fibre orientation. After examining the innervations of both sides, the authors concluded that this absence was due to an anomaly during development.

Allouch et al.⁴ reported total absence of the left trapezius muscle in an 87 year old Caucasian man who died from cardiopulmonary arrest. Unilateral agenesis of the trapezius muscle was accompanied by absence of the left spinal accessory nerve, absence of arterial blood supply on the left side and duplication of the palmaris longus muscle in the left upper extremity. The authors stressed the fact that there were no signs of surgery or previous injury. The congenital absence of total innervation of the left spinal nerve should lead to pathological function of the sternocleidomastoid muscle because it is supplied by the same nerve. This hypothesis was rejected because of the presence of a normal left sternocleidomastoid muscle in the cadaver.

Hug et al.⁵ reported the study of a rare variation of the trapezius muscle. The reason for this publication was a 48 year old man who presented with pain and sensory deformities radiating from his neck to the thumb and forefinger of his right hand, when he lifted objects and when he turned or tilted his head. The symptoms originated from an anomalous accessory part of the trapezius muscle that

crossed the upper part of the brachial plexus. The symptoms vanished when the anomalous muscle was removed and the clavicular part of the sternocleidomastoid released from pressure.

The study of Kwak et al.⁶ presents a variation of the trapezius muscle identified in the cadaver of an adult female from Korea, during anatomical dissection. In this particular case, $\frac{3}{4}$ of the lateral upper part of the descending portion of the trapezius muscle were separated from the rest of the muscle. This isolated part fused above the insertion point of the middle of the clavicle, as a different tendon. The descending part of the muscle inserted into the clavicle scapula normally.

Newman et al.⁷ studied variation in a 5 year old child and his father in Portugal. The boy was referred to a neurological clinic for suspected myopathy. The boy's parents reported that the strength of his hands was normal and that there was no limitation in daily activities. They also mentioned that he could not lift his arms above his head. During physical examination, it was observed that the boy's shoulders were slanting down and were displaced anteriorly, forming a neck that appeared web-shaped thereby causing asymmetry of the features of the face. Despite this fact, there were no limitations in the passive movements of his shoulders. The pectoralis muscles presented with normal strength just like the flexors, extensors of the neck and the sternocleidomastoid muscles. The deltoid, bicep and tricep muscles on both sides of the body appeared to be of normal strength, at grade 5 in MRC scale (Medical Research Council scale). Camptodactyly was observed bilaterally in 2 to 5 fingers and was more intensive in the fourth finger on the right side. Strength and movement in the lower extremities was normal. Radiological examination {Magnetic Resonance Imaging(MRI)} revealed that the symptoms were caused by bilateral aplasia of the trapezius muscles. The boy's father was found with unilateral partial hypoplasia of the trapezius muscle, a right scapula that was displaced laterally with slight camptodactyly in both hands. Despite these anomalies, he did not have any functional disorder. The authors underlined the fact that congenital aplasia of the trapezius muscle is a very rare condition and that bilateral aplasia has only been reported in 5 cases⁷.

In their study, Garbelotti et al.⁸ presented a case of unilateral absence of the trapezius muscle. They observed partial unilateral absence of the left trapezius muscle during anatomical dissection of the back, in an adult black male cadaver. The skin of the man's back was intact, without any

sign of injury or surgical operation. The descending fibres of the left trapezius and the upper part of the middle fibres were normal, concerning their position and attachments. The descending part of the muscle, measured from the posterior to the anterior position, had the following thickness: 32 mm at its lateral part, 59 mm at its central part and 62 mm at its medial part. The middle part of the muscle had the following thickness: 43 mm at the level of C6 nerve in the neck and 35 mm at the level of the base of the skull. The ascending part of the muscle and the descending fibres of the middle part were totally replaced by a large aponeurosis 2 mm thick and was characterized as trapezius aponeurosis. The rhomboid major and minor muscles were normal and sited under the aponeurosis, thereby replacing the trapezius muscle.

Nooij and Oostra⁹ reported the case of a trapezius muscle agenesis. The cadaver was a 67 year old Dutch Caucasian woman. During anatomical dissection, Nooij and Oostra observed that the descending and transverse part of the left trapezius muscle were totally absent. Only a few muscular fibres were located at the ascending part of the muscle. There were no other accessory anomalies in the cadaver, neither locally at the trunk nor generally. There were no signs of previous injury or surgical operation in the area of the trapezius muscle.

Stacey et al.¹⁰ reported that the accessory nerve (sp.XI) failed to supply the trapezius muscle, which was entirely innervated from the cervical plexus. This finding supports the hypothesis that the cervical plexus may contain fibres for motility and explains why complete paralysis of the trapezius is not always produced when the accessory nerve is sacrificed during radical neck dissection.

Gross-Kieselstein and Shalev¹¹ reported a study of two relatives who suffered from complete absence of the trapezius muscle. The first case was that of a 17 year old Jew from North Africa, who presented with a hollow posterior in the area of the trapezius muscle and anterior in the area of the pectoralis muscle. The patient could not lift his arms above his head. Tests of the muscles show absence of the trapezius muscle on the right and smooth weakness of the pectoralis and other thoracic muscles. In addition, the mass of the muscle, its strength and the reflexes of the tendons were normal. The second case concerned the older brother of the first subject, a 28 year old male who had slow psychomotor development and attended a special school for children with learning disabilities. After clinical examination, the authors noted absence of the trapezius and pectoralis muscles on the right side of the subject. Moreover,

he could not lift his hands over his head and his shoulders were also bent forward, despite muscle mass and strength being normal. Some authors believe that this muscular anomaly may be caused by an injury during the 6th or 7th month of intrauterine life, while others attribute it to a slow development due to anomalies in the vessels of the embryo.

DISCUSSION - CONCLUSIONS

Variations and anomalies rarely occur in the trapezius muscle. Although rare, there are some reported cases of variations observed in vivo and in cadavers. The variations that we can find in bibliography are: absence of a part of the muscle, aplasia of the whole muscle, appearance of accessory parts on the muscle and variations in its innervations. The two main explanations for these variations are genetic morphology^{11,12} and embryological distributions of the muscle¹³. With regard to absence of the trapezius muscle, it can occur solely or coexist with absence of other muscles like the sternocleidomastoid or thoracic muscles^{11-15,17}. There are some reports about the partial or complete absence of the muscle. A brief review of the literature reveals 6 cases (4 men, 2 women) that were under anatomical dissection. Unilateral absence of the muscle was found in 5 of 6 cases. All the muscle parts were absent in 2 cases^{4,9}, in one case the upper (descending) part of the muscle was absent¹⁶ and the lower part (ascending) of the muscle was also absent in two reported cases^{3,8}. Only in one case was the muscle reported to be absent unilaterally¹⁴.

Muscular anomalies at the posterior cervical triangle (with origin in the trapezius muscle) are rare and occur in less than 2% of cases¹⁸. An anomaly of this kind was reported and referred to in a trapezius muscle that had an accessory part located at the upper part of the neck and caused compression of the brachial plexus⁵.

The variations of the trapezius muscle, especially its complete or partial agenesis, cause restricted motility of the upper extremities. Persons that appear with these kinds of variations are unable to lift their hands above their heads^{7,11}.

References

- 1) W. Kahle, H. Leonhardt, W. Platzer. Taschenatlas der Anatomie. Published by medical publishing corporation Litsas- Greek Edition, 1985, pp. 144-147.
- 2) H. Gray. Gray's Anatomy, New York: Churchill Livingstone, 38th edition, 1995 ; pp.835-836.
- 3) J.G.Emsley, M. D.Davis. Partial unilateral absence of the trapezius muscle in a human cadaver. *Clinical Anatomy*, 2001;14(5), 383-386.
- 4) M. Allouh, A. Mohamed, A. Mhanni. Complete unilateral absence of trapezius muscle. *McGill J. Med*, 2004; 8, 31-33.
- 5) U. Hug, D.Burg, V.E. Meyer. Cervical outlet syndrome due to an accessory part of the trapezius muscle in the posterior triangle of the neck. *Journal of Hand Surgery, (British and European Volume)*, 2000; 25(3), 311-313.
- 6) H.H. Kwak, H.J. Kim, K.H. Youn, H.D. Park, I.H. Chung. An anatomic variation of the trapezius muscle in a Korean: the cleido-occipitalis cervicalis. *Yonsei Medical Journal*, 2003; 44(6), 1098-1100.
- 7) C.J. Newman, S. Jacquemont, N. Theumann, P.Y. Jeannet. Familial aplasia of the trapezius muscle: clinical and MRI findings. *Acta Paediatrica*, 2011;100(3), 464-466.
- 8) S.A. Garbelotti Jr, C.F. de Sousa Rodrigues, E.A. Sgrott, J.C. Prates. Unilateral absence of the thoracic part of the trapezius muscle. *Surgical and Radiologic Anatomy*, 2001; 23(2), 131-133.
- 9) L.S. Nooij, R. J. Oostra. Trapezius aplasia: indications for a dual developmental origin of the trapezius muscle. *Clinical Anatomy*, 2006; 19(6), 547-549.
- 10) R. J. Stacey, S.T. O'Leary, P.J. Hamlyn. An anomaly in the nerve supply of the trapezius muscle. *Clinical Anatomy*, 1996; 9(6): 414-416.
- 11) E. GrosslKieselstein, R.S. Shalev. Familial absence of the trapezius muscle with associated shoulder girdle abnormalities. *Clinical Genetics*, 1987; 32(3), 145-147.
- 12) S. B. Adams Jr, J. M. Flynn, H. S. Hosalkar, J. Hunter, R. Finkel, H. Halsikar. Torticollis in an infant caused by hereditary muscle aplasia. *American Journal of Orthopedics (Belle Mead, NJ)*, 2003; 32(11), 556-558.
- 13) P. Debeer, P. Brys, L. De Smet, J. P. Fryns. Unilateral absence of the trapezius and pectoralis major muscle: a variant of Poland syndrome. *Genetic Counseling*, 2001; 13(4), 449-453.
- 14) D. Sheehan . Bilateral absence of trapezius. *Journal of Anatomy*, 1932; 67 (1), 180-181.
- 15) F.T. Horan, R.P. Bonafede. Bilateral absence of the trapezius and sternal head of the pectoralis major muscles. A case report. *J Bone Joint Surg Am.*, 1977 ; 59(1):133.
- 16) H.A. Rahman, T. Yamadori. An anomalous cleido-occipitalis muscle. *Cells Tissues Organs*, 1994; 150(2), 156-158.
- 17) B.R. Selden. Congenital absence of trapezius and rhomboideus major muscles. *The Journal of Bone & Joint Surgery Case Connector*, 1935; 17(4), 1058-1059.
- 18) X. Leon, E. Maranillo, M. Quer, J.R. Sanudo. Case report: cleidocervical or levator claviculae muscle. A new embryological explanation as to its origin. *Journal of Anatomy*, 1995; 187: 503-504.

Author Information

George Noussios, MD, PhD

Laboratory of Sports Medicine in Department of Physical Education and Sports Sciences (at Serres), “Aristotelian”

University of Thessaloniki

Greece