

Management Of Intestinal Atresia At The Aristide Le Dantec Hospital In Dakar, Senegal: A Preliminary Study

O Ndour, A Bouraima, A Faye Fall, N Ndoeye, P Mbaye, G Ngom, M Ndoeye

Citation

O Ndour, A Bouraima, A Faye Fall, N Ndoeye, P Mbaye, G Ngom, M Ndoeye. *Management Of Intestinal Atresia At The Aristide Le Dantec Hospital In Dakar, Senegal: A Preliminary Study*. The Internet Journal of Pediatrics and Neonatology. 2016 Volume 18 Number 1.

DOI: [10.5580/IJPN.22317](https://doi.org/10.5580/IJPN.22317)

Abstract

Goals: Report diagnostic, therapeutic aspects and outcome of intestinal atresia in our context of developing countries.

Patients and methods: This is a retrospective descriptive study from January 2009 to December 2012. We compiled 10 cases of intestinal atresia with an average age of 4.2 days and a sex ratio of 0.67. We used clinical and para-clinical, treatment and outcome.

Results: The clinical picture was that of a bowel obstruction flat stomach in eight cases and bloated stomach in two cases. Three patients had associated malformations. Radiography of the abdomen was performed in all patients showing air-fluid pictures in seven patients and a double bubble appearance in three patients. Surgical exploration found duodenal atresia, jejuno-ileal atresia, and colonic atresia. Patients who had jejunoileal atresia were treated by resection followed by end-to-end anastomosis in one case and resection stoma in six other cases. The patient who had a bowel atresia received a lateral terminal colostomy. The resumption of diet was started in average on the third postoperative day. Postoperative morbidity consisted mainly of electrolyte disturbances in seven cases and parietal abscesses in four cases.

Conclusion: The mortality of intestinal atresia remains high in our context despite surgical treatment. The improved prognosis must pass through the establishment of neonatal intensive care unit, the availability of total parenteral nutrition and strengthening the technical platform.

INTRODUCTION

Intestinal atresia represent a spectrum of isolated or syndromic congenital malformations whose consequence is an interruption in the continuity of the digestive tract with possibly a lack of certain segments of the gut [1]. The annual incidence of intestinal atresia is variable from 2 to 4 cases per year per million people [2, 3]. The diagnosis is difficult prenatally and is often done at birth [4]. This is a neonatal emergency care which requires surgical correction to provide a temporary diversion or a sleeve resection of the atretic area in the neonatal period [1]. The prognosis of intestinal atresia has improved over the years in developed countries with a survival rate which rose from 9.1% in 1951 to 90% the last two decades [5, 6]. In countries in the developing world the management of this pathology is facing multiple problems such as: late diagnosis, precarious

technical facilities, lack of unity of neonatal resuscitation, and unavailability of parenteral nutrition. These factors are real obstacles to achieve cure rates comparable to those of developed countries. [7] In Senegal, no work had so far been devoted to this subject which justifies the implementation of this retrospective study whose purpose was to report the diagnostic, therapeutic and evolutionary aspects of this pathology.

PATIENTS AND METHODS

Our work is a retrospective study of descriptive and cross-type nature. We collected the information from January 1st 2009 to December 31st 2012 and found that 10 neonates were supported for intestinal atresia in the pediatric surgery department of the Hospital Aristide Le Dantec in Dakar, Senegal. They had a mean age of 4.2 days and a sex ratio of 0.67. We have not included in this study patients with

incomplete or default or initially operated in another health facilities. We studied the clinical, therapeutic and outcome data. We used the classification of Grosfeld to determine the anatomical type of the atresia. Analysis of data was performed using Microsoft Office Excel 2007 software.

RESULTS

Clinical signs were dominated by signs of intestinal obstruction (Table 1). Rectal probe was negative in two children with abdominal distension. Examination of the anal margin was normal in all patients. We noted a case of Prune Belly Syndrome in a neonate with ileal atresia.

Thoraco-abdominal radiography was performed in 10 neonates. The air-fluid levels were found in the photographs of seven newborns of which in four cases it was of colonic nature and three cases at the level of the small bowel. The classic image of "double stomach" or "double bubble" was found in three infants with duodenal atresia and jejunal atresia respectively.

In our series, six pregnancies were properly followed with regular antenatal and prenatal ultrasound. No prenatal diagnosis of atresia was made.

Anemia was found in three patients with ileal atresia. They presented with hemoglobin rates of 7.4; 8.3 and 10.2 g / dl. Seven patients had electrolyte disorders with an average serum sodium of 122,3meq / l and an average serum potassium of 2.41 meq / l.

As part of the search for associated malformations Doppler echocardiography was performed in two newborns. This examination revealed a large patent foramen ovale and patent ductus arteriosus in one of the newborn. We also found situs solitus with a patent ductus arteriosus in a newborn with Prune Belly syndrome. Both children had an ileal atresia.

All patients received intravenous antibiotics. They received a combination of cefotaxime (50-100mg / kg / day) and gentamicin (3-5mg / kg / day). All patients had received intravenous infusions with paracetamol 15 mg / kg / 6 hours. They also received resuscitation facilities based fluid input in form of 100-120ml / kg / d of 10% SG and electrolytes in an amount of 3-5 meq / kg / day for the NaCl and 2- 3meq / kg / day for KCl. The introduction of the nasogastric tube was done routinely in our series.

We found 1 case of duodenal atresia, 2 cases jejunal atresia, 5 cases of ileal atresia (Figure 1) and one case of colon atresia. The newborn had Prune Belly syndrome and a heart defect also had intestinal malrotation position of the common mesentery (Table 2).

Nine patients with intestinal atresia were treated surgically. One newborn with duodenal atresia was treated with a duodenal diamond-shaped duodenostomy. Out of the two cases of jejunal atresia, one received a resection anastomosis end-to end and the other a resection stoma. The restoration of digestive continuity was performed one week after the first surgery. A stoma resection was performed in five infants with ileal atresia. The restoration of digestive continuity was performed at 14 days after the newborns survived the initial response. Side colostomy terminalization was performed in neonates with atresia of the colon.

The average time was 5.8 days (3-9 days) for the removal of the nasogastric tube, 4 days (3-5days) for the resumption of transit, and 6.4 days (4-10 days) for the initiation of food. The average hospital stay was 14.5 days (1-51 days). It was 5 days for duodenal atresia and 16.85 days for the jejuno-ileal atresia. For the two patients who survived, the operating setbacks were 12 and 15 months. It was 12 months for a newborn who presented an ileal atresia type III according to the classification of Grosfeld with malformations (heart defects and intestinal malrotation) who received a stoma resection with restoration of continuity after one week. It was 15 months for a newborn with duodenal atresia type III who received a duodéno- duodenostomy diamond-shaped suregry.

Early complications were marked by six cases of electrolyte disturbances, two cases of retraction of the stump of the stoma, a case of necrosis, and four cases of parietal abscesses. We have not found of late complications in our study.

We recorded one death in our series preoperatively (ileal atresia autopsy Type IIIa) and four deaths in the immediate postoperative period. For the latter, it was a case of atresia coli, a case of jejunal atresia and two cases of ileal atresia who all received a stoma. Long-term outcome was marked by three other deaths including a case of jejunal atresia and two cases of ileal atresia. A total of eight out of 10 children have died in our series.

DISCUSSION

The diagnosis of intestinal atresia can be done prenatally through the use of imaging techniques including prenatal ultrasound [4, 8]. In developing countries, the diagnosis is often made after birth [9]. In our study no prenatal diagnosis had been made due to the lack of experienced sonographers in the neonatal surgical field. The value of prenatal diagnosis is to enable better management of the newborn, conduct

birth in a specialized center with a neonatal surgery expertise. At birth, intestinal atresia carries an array of neonatal intestinal obstruction. [11] The symptoms vary depending on the site of obstruction. The main signs found postnatally in our study were the signs of bowel obstruction. Our results were comparable to those of several authors (Table 3). Thoraco-abdominal radiography provides highly suggestive indications for the diagnosis or the level of obstruction in the digestive tract by showing pictures hydroaeric (atresia of the small intestine or colon) or double bubble (duodenal or jejunal atresia proximal). In our series, radiological examination was the only diagnostic imaging tool used. However, other imaging modalities such as ultrasound or œsogastroduodénal transit (TIGD) examinations were performed by some authors [7, 9, 12]. In the literature, intestinal atresia is associated in 25-50% of the cases with other defects as well as chromosomal abnormalities [8, 11]. The malformations vary by the site of atresia and are more common seen in duodenal atresia [8, 9, 11, 12]. Our study had less defects associated with intestinal atresia in comparison to those of other authors [8, 11]. This is probably related to the small size of our series and the fact that the search for any abnormalities was not systematic. There are tests that are sent to France at high costs (120,000 CFA francs) and this is why we did not request them. The same situation is found in most developing countries. However, some authors practiced karyotyping and found certain chromosomal abnormalities [9, 11].

The surgical procedure in intestinal atresia is variable depending on the site of the atresia and the anatomical findings after laparotomy and associated malformations [8]. Duodenal atresia and duodenal stenosis were initially supported using a duodeno-jejunostomy. Most authors now recommend duodenal diamond-shaped duodenostomy [11], a technique we used while some African authors performed a duodeno-jejunostomy [7, 9, 12]. In case of jejunal ileal atresia the choice of surgical procedure depends on the associated malformations (malrotation, volvulus, meconium peritonitis, gastroschisis, omphalocele) and the length of the remaining [11] intestine. When the length of the intestine is appropriate a resection of the atretic area followed by end to end anastomosis is performed. [13] In the presence of a short intestine, in cases of meconium peritonitis resulting from a perforation, or when the viability of the intestine is questionable a temporary stoma is done. The treatment of atresia of the jejunum in our study included resection anastomosis end to end in one case and resection stoma in

the other while that of ileal atresia in five newborns was made by a resection combined with stoma. Some African authors conducted jejunal or ileal atresia resection followed by end to end anastomosis [7, 9, 72]. The choice of treatment in one or two stages of atresia coli depends for most authors on two main parameters: the general condition of the newborn and the topography of the atresia [14]. A first surgery can quickly remove the obstacle and delay the cure of the atresia for a later time (two to three months) before a severe deterioration of general condition occurs [15]. The treatment is performed in a single session in pre angulo spleen atresia with a newborn in good condition. [16] Resection of the ileocecal valve is not desirable because of its role in the motility of the small intestine and the ileal content protection against contamination by colonic bacteria [17]. However, in recent years some authors have advocated the use of a resection with primary anastomosis, regardless of the location of the atresia whenever the general condition of the patient permits. [16] The treatment of atresia coli was done in this study as a first step using a terminalized side colostomy. We preferred this method because the patient's general condition was not good.

Survival of patients undergoing intestinal atresia also depends on nutritional support. Parenteral nutrition plays an important role in the nutritional management of neonates with short bowel after surgery [9]. Dalla Vecchia et al [11] promote the early use of growth factors to maximize intestinal adaptation and dietary changes can improve the condition of patients with short bowel syndrome. The mean duration of parenteral nutritional support in the study of Bouchard [18] was 20 days. This period may be even longer in severe cases of atresia or malformations including gastroschisis. The average time from onset of feeding was five days in Gouli et al [7], seven days in Chirdan et al [12] and 13 days for Merkel. [8] In our study, the average time from start of feeding was 6.4 days. Our results are comparable to Gouli and Chirdan that feed patients early because of the lack of effective resuscitation.

The hospital stay is variable according to the literature and it depends on the location and type of atresia, associated malformations, and the type of surgery [7, 8, 9, 12, 18]. To avoid early complications it is important that the newborns received a stoma resection [19]. Complications mainly consist of gutting and infections that can range from the parietal suppuration peritonitis to dehiscence digestive problems. Late complications are dominated by the rupture and occlusion flange [8, 11]. In our study and those of

Chirdan [12], Gouli [7], and Merkel [8], early complications were dominated by electrolyte disorders and parietal suppuration. In studies by Merkel and Dalla Vecchia early complications were more frequent in jejunal and ileal atresia whereas in duodenal atresia late complications were ore likely [8, 11].

The overall mortality of intestinal atresia depends on several factors that may be prematurity, congenital anomalies, the site of atresia, and also diagnostic delay [7, 9, 12]. In 1951, Evans et al reported a survival rate of 9.3% among patients with intestinal atresia [20]. In the last two decades, most studies from developed countries reported survival rates approaching or being greater than 90% for patients with jejunal or ileal [3] atresia. The prognosis of colonic atresia is usually good [17]. The prognosis of intestinal atresia is better in developed countries (Table 4) that in developing countries where there are survival rates barely reaching 50% [9, 72]. In our study, overall mortality was 80%. The improved prognosis in developed countries is largely due to a better understanding of the causative factors of intestinal atresia, changes in surgical procedures, improving anastomotic suture techniques, improving various aspects of neonatal care and anesthesia and the development of total parenteral nutrition. The high mortality in developing countries is due to several factors including associated malformations, the unavailability of neonatal intensive care unit, the unavailability of total parenteral nutrition, complications related to surgical techniques including ostomy and low social level with economic problems for the parents who do not allow them to meet certain medical requirements. According to Dalla Vecchia and Shakya, the mortality also depends on the site of the atresia [11, 21]. It is much higher for ileal and jejunal atresia while it is almost zero for colonic atresia. In our study, only seven patients who presented with jejunal or ileal atresia survived after 12 months.

CONCLUSION

In our context the diagnosis of intestinal atresia is done when post natal intestinal obstruction occurs. Surgical mortality remains high in developing countries. Improvement of prognosis could be achieved through the establishment of neonatal intensive care units, the availability of total parenteral nutrition, and strengthening of the technical platform for diagnosis and treatment.

Figure 1

Image showing intraoperative ileal atresia type IIIa according to the classification of Grosfeld

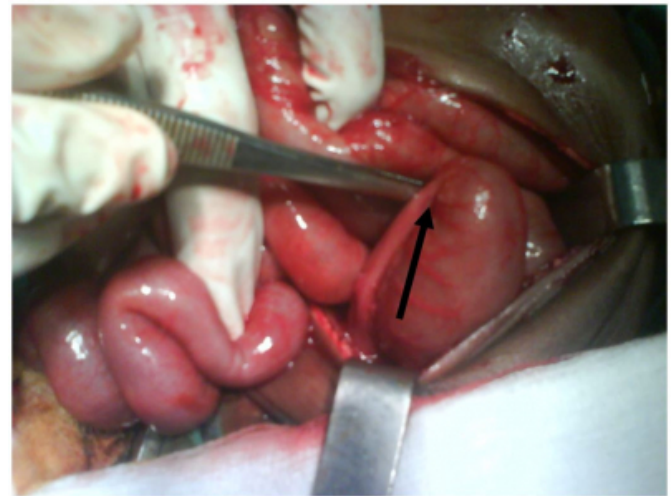


Table 1

Distribution of patients according to clinical signs

Clinical signs		Number
Vomiting	bilious	7
	alimentary	1
No emission meconium		10
Abdominal distension		2
Impaired general condition		9
Fever		1
Polypnea		2
Collateral venous circulation		2

Table 2

Distribution of operative findings as the seat of the atresia and associated malformations

Seat of atresia	Type of atresia	Number	Associated malformations
Duodenum	III	1	Annular pancreas
Jejunum	II	1	0
	III a	1	0
Ileum	III a	1	0
	III a	1	Intestinal malrotation
	III b	1	Prune Belly + intestinal malrotation
	III b	2	0
Colon	III b	1	0
	III b	1	0

Table 3

Distribution of clinical signs that some African Studies

Authors	Country	Size range	Vomiting	No emission meconium	Abdominal distension
Chirdan [12]	Nigeria	24	24	7	16
Gouli [7]	Côte d'Ivoire	26	25	16	20
Williams [9]	Nigeria	30	22	12	10
Our Study	Senegal	10	8	10	2

Table 4

Evolution survival rates of intestinal atresia in the literature

Seat of atresia	Authors	Survival rate
Duodenum	De Lorimier et al, 1969	60%
	Nixon and Tawes, 1971	60%
	Stauffer and Irving, 1977	69%
	Kullendorf, 1983	90%
	Grosfeld and Rescorla, 1993	95%
	Mooney et al, 1987	95%
	Laura K. Dalla Vecchia, 1998	86%
	Our study	1 of 1 survivors
	Louw, 1967	94%
	De Lorimier et al, 1969	64%
Jejuno ileum	Nixon and Tawes, 1971	62%
	Martin and Zarella, 1976	64%
	Cywes et al, 1980	88%
	Grosfeld and Rescorla, 1985	87%
	Laura K. Dalla Vecchia, 1998	84%
	Our study	1 of 8 survivors
Colon	Coran and Eraklis, 1969	67%
	De Fore et al, 1976	70%
	Grosfeld and Rescorla, 1985	100%
	Davenport et al, 1990	91%
	Laura K. Dalla Vecchia, 1998	100%
	Our study	0 of 1 survivors

References

1. Boureau M. Urgences chirurgicales néonatales. Pédiatrie pratique : Périnatalogie. Paris : Maloine 1985; pp 992 - 993.
2. Ameh EA, Chirdan LB. Neonatal intestinal obstruction in Zaria, Nigeria. East Afr Med J 2000; 77:510-513.
3. Ameh EA, Nmadu PT. Intestinal atresia and stenosis: a retrospective analysis of presentation, morbidity and mortality in Zaria, Nigeria. West Afr J Med 2000; 19:39-42.
4. Bangy F, Baudoin S. Urgences chirurgicales du nouveau-

né et du nourrisson. Encycl méd chir péd, Elsevier, Paris; 4-002-S-75, 1999; 10p.

5. Goujard J. Enregistrement des malformations congénitales à Paris : bilan et perspectives de l'étude placée sous l'égide de la C.E.E. J. Gyn Obs Biol Repr 1983; 12 : 805-817.

6. Osifo OD, Okolo JC. Neonatal intestinal obstruction in Benin, Nigeria. Afr J Paediatr Surg 2009; 6(2): 98-101.

7. Gouli JC, Odehouri KTH, Tembely S, Dieth AG, et al. Atrésie intestinale au CHU de Yopougon. J Afr Chir Digest 2006; 6(2): 573 – 578.

8. Merkel M. Postoperative Outcome after Small Bowel Atresia. Thèse Med: Medizinischen Universität Graz: 2011; n°0633182.

9. Williams, Osuoji, Ajai, Olayiwola, Bankole MA. Intestinal Atresia: A Four-Year Review of Cases in Ikeja-Lagos. J Nepal Paediatr Soc 2012; 32(1): 28-32.

10. Bargy F et Beaudoin S. Urgences chirurgicales du nouveau-né et du nourrisson. Encycl Méd Chir Elsevier, Paris, 1998 ; (8-0405) : 4- 6.

11. Dalla Vecchia LK, Grosfeld JL, West KW, Rescorla FJ, et al. Intestinal Atresia and Stenosis A 25-Year Experience With 277 Cases. Arch Surg 1998; 133(5):490-496.

12. Chirdan LB, Uba AF, Pam AED. Intestinal atresia: management problems in a developing country. Pediatr Surg Int 2004; 20(11-12): 834-837.

13. Juskiewenski. Occlusions duodénales néonatales, atrésies et sténoses du côlon et du rectum. In : Technique de Chirurgie pédiatrique. Paris : Masson 1978. pp 394-399.

14. Etensel B, Témir G, Karkiner A. Atresia of the colon. J Pediatr Surg 2005; 40: 1258-68.

15. Watts AC, Sabharwal AJ, Mackinlay CA, Munro FD. Congenital colonic atresia : should primary anastomosis always be the goal? Pediatr Surg Int 2003; 19: 14-7.

16. Rodriguez SS, Hurtado CM, Ossorio JS. Congenital colonic atresia: surgery correction in one or two stages? Chir Pediatr 2005; 18: 42- 5.

17. Estel B. Atresia of the colon. JPS 2005; 40: 1258- 68.

18. Burjonrappa SC, Crete E, Bouchard S. Comparative outcomes in intestinal atresia: clinical outcome and pathophysiology analysis. Pediatr Surg Int 2011; 27: 437–442.

19. Chadha R, Sharma A, Roychoudhury S, Bagga D. Treatment strategies in the management of jejunoileal and colonic atresia. J Indian Assoc Pediatr Surg 2006; 11(2): 79-84.

20. Evans CH. Atresias of the gastrointestinal tract. Surg Gynecol Obstet 195; 92: 1- 8.

21. Shakya VC, Agarwal CS, Shrestha P, et al. Management of jejunoileal atresias: an experience at eastern Nepal Vikal C. BMC Surgery 2010; 10: 3-6.

Author Information

Oumar Ndour

Associate Professor, Paediatric Surgeon, Paediatric Surgery Department, Aristide Le Dantec Hospital
Dakar, Sénégal
roundrouma@yahoo.fr

Abdul Djamal Bouraima

Doctor, Paediatric Surgery Department, Aristide Le Dantec Hospital
Dakar, Sénégal

Aimée Lakh Faye Fall

Paediatric Surgeon, Paediatric Surgery Department, Aristide Le Dantec Hospital
Dakar, Sénégal

Ndeye Aby Ndoeye

Paediatric Surgeon, Paediatric Surgery Department, Aristide Le Dantec Hospital
Dakar, Sénégal

Pape Alassane Mbaye

Paediatric Surgeon, Paediatric Surgery Department, Aristide Le Dantec Hospital
Dakar, Sénégal

Gabriel Ngom

Professor, Paediatric Surgeon, Paediatric Surgery Department, Aristide Le Dantec Hospital
Dakar, Sénégal

Mamadou Ndoeye

Professor, Paediatric Surgeon, Paediatric Surgery Department, Aristide Le Dantec Hospital
Dakar, Sénégal