

Malposition Of Central Venous Catheter Into Contralateral Internal Jugular Vein

R S Kaushik, U Madhusudhan

Citation

R S Kaushik, U Madhusudhan. *Malposition Of Central Venous Catheter Into Contralateral Internal Jugular Vein*. The Internet Journal of Anesthesiology. 2014 Volume 34 Number 1.

DOI: [10.5580/IJA.22589](https://doi.org/10.5580/IJA.22589)

Abstract

Central venous cannulation although a popular and safe technique is known to be associated with complications. Malposition of central venous catheter is one such complication which can occur.¹ This is a case report on a misdirected central venous catheter into opposite internal jugular vein (IJV) following subclavian vein cannulation.

INTRODUCTION

Central venous cannulation is a popular and widely practiced technique used for various purposes in anaesthesia and intensive care. Widely regarded as a safe technique it can yet be associated with many complications. Malposition of central venous catheter (CVC) is a (not unusual) known complication.¹ There are many case reports on malposition of CVC into ipsilateral internal jugular vein(IJV) following subclavian vein cannulation and is regarded as a common complication.² However the misplacement of CVC into contralateral IJV is extremely rare. We report a case of malposition of CVC tip into left IJV following right subclavian vein cannulation.

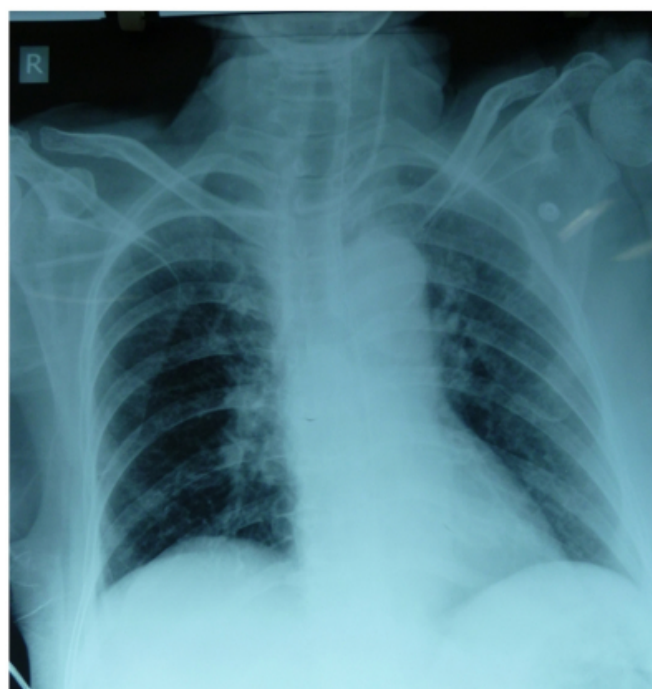
CASE PRESENTATION

A 70 year old woman with acute intestinal obstruction (due to rectosigmoid growth) presented to operating room for emergency transverse colostomy. On examination she was grossly dehydrated, Pulse-140bpm, BP-140/70mmHg, cold peripheries. Central venous cannulation was considered as the peripheral veins appeared collapsed and were inaccessible. Under aseptic precautions, the right subclavian vein was successfully cannulated with 7 French triple lumen CVC (B Braun) by infraclavicular approach using Seldinger's technique. No abnormal resistance was offered to the insertion of guide wire, nor the catheter. Catheter was fixed after confirmation of free aspiration of venous blood in all the ports as well as free flow of normal saline. Rapid sequence induction was followed and the surgery was commenced. Intraoperative period was uneventful.

Postoperatively a check chest X-ray revealed the catheter tip position in the contralateral (Left) IJV. (Figure1)

Figure 1

Chest X-Ray showing malpositioned central venous catheter present in left IJV



DISCUSSION

Central venous catheter is utilized for numerous purposes including central venous pressure(CVP) monitoring, for infusion of fluid, drugs, blood and blood products, chemotherapy, total parenteral nutrition, and many more. Its

insertion can be associated with numerous complications. These include pneumothorax, hemothorax, chylothorax, arterial puncture, damage to vein and nerves, sepsis, air embolism, arrhythmia, thrombosis, malposition, folding of the catheter, cardiac tamponade.^{2,3}

For accurate central venous pressure measurement, the tip of the catheter should be located ideally at the junction of the superior vena cava and right atrium, but many a times this desired level may not be achieved.^{4,5} Although the incidence of catheter malposition is low (3-4%), it is a well known complication following central venous cannulation.⁶ The commonest site of a misdirected CVC following subclavian vein cannulation is into ipsilateral internal jugular vein.³ This can be detected by immediate check chest X-ray or ultrasound. Other uncommon sites include contralateral subclavian vein, azygous vein, thymic vein, large venous tributaries of the superior vena cava, minor intrathoracic veins and inadvertent arterial cannulation.⁷

Chauhan A reported two incidences of malpositioning of central line into contralateral subclavian vein, one was a peripherally inserted central catheter (PICC) and another subclavian CVC.⁸ Misplaced catheter tips are usually associated with a few complications; these include inaccurate measurement of CVP, catheter blockade due to clotting, thrombophlebitis, vein perforation, cardiac tamponade.^{9,10}

Pikwer A et al. conducted a prospective study on a total of 1619 central venous cannulations to detect the radiographic catheter tip position by various routes and identification of complications related with the use of malpositioned catheter. Results showed that the overall incidence of radiographic catheter tip malposition was 3%, which included both extrathoracic or ventricular positioning. Risk of malposition was higher following right subclavian vein cannulation as compared to right IJV cannulation (9.1% vs 1.4%). There were no cases of vascular perforation, local venous thrombosis or embolism in association with the malpositioned catheter tips. It was concluded that the incidence of malpositioned CVC is low and its clinical use is associated with few complications.¹¹

Hence in our case, the malpositioned CVC (in the left IJV)

was left in situ, as its indication was for the purpose of volume replacement. Also the IJV being a large vessel, complications like vascular perforation, thromboembolism are less likely compared to malpositioned CVC tip in one of the smaller tributaries of a central vein.

We conclude that although malpositioned CVCs can be associated with complications, the overall incidence is low and its clinical use is very much encouraged unless the indication is for CVP monitoring. Also the use of chest radiographs to confirm the correct placement of central lines should be routinely practiced.¹²

References

1. Sanchez R, Halck S, Walther-Larsen S, et al. Misplacement of subclavian venous catheters: importance of head position and choice of puncture site. *Br J Anaesth* 1990; 64: 632-3
2. Gladwin MT, Slonim A, Landucci DL, Gutierrez DC, Cunnion RE: Cannulation of the internal jugular vein: is post procedural chest radiography always necessary? *Crit Care Med* 1999, 27:1819-1823
3. D Malhotra, S Gupta, S Gupta, B Kapoor. Malposition Of Internal Jugular Vein Cannula Into Ipsilateral Subclavian Vein In Reverse Direction- Unusual Case Report. *The Internet Journal of Anesthesiology*. 2008 Volume 22 Number 1
4. McGee WT, Ackerman BL, Rouben LR, et al. Accurate placement of central venous catheters: a prospective, randomized, multicenter trial. *Crit Care Med* 1993; 21: 1118-23.
5. Asudani D, Wretzel S, Patel R, Stayman A. The Clinical Picture: A judgment call. *Cleveland Clin J Med*. 2008;75:690-5.
6. Moeinipour Aa et al. A Rare Central Venous Catheter Malposition: A Case Report. *Anesth Pain Med*. 2014;4(1):e16049
7. Currarino G. Migration of jugular or subclavian venous catheters into inferior tributaries of brachiocephalic veins or into the Azygous veins, with possible complications. *Pediatr Radiol* 1996; 26:439-49.
8. Chauhan A. Malpositioning of Central Venous Catheter: Two Case Reports. *Indian J Anaesth* 2008; 52: 337-9.
9. Abbas H, Arshad Z, Saxena S, Bogra J, Kazim A. Unusual malposition of central venous catheter-A Case Report. *Natl J Med Res*. 2013; 3(1): 96-97
10. Collier PE, Blocker SH, Graff DM, Doyle P. Cardiac tamponade from central venous catheters. *Am J Surg* 1998; 176: 212-4.
11. Pikwer A, Baath L, Davidson B, Perstoft I, Akesson J. The incidence and risk of central venous catheter malpositioning: a prospective cohort study in 1619 patients. *Anaesth Intensive Care*. 2008;36(1):30-7.
12. Deitel M, McIntyre JA. Radiographic confirmation of the site of central venous pressure catheters. *Can J Surg* 1971;14:42-52

Author Information

Rao S, Kaushik, MD Anaesthesia, Senior Resident

Department of Anaesthesia, Kasturba Medical College, Manipal University
Mangalore, Karnataka, India

Upadya Madhusudhan, M.D Anaesthesia, Professor

Department of Anaesthesia, Kasturba Medical College, Manipal University
Mangalore, Karnataka, India