

# Omohyoid Muscle's Interesting Anatomical Variations – Review of the Literature

G Noussios

## Citation

G Noussios. *Omohyoid Muscle's Interesting Anatomical Variations – Review of the Literature*. The Internet Journal of Human Anatomy. 2015 Volume 3 Number 1.

DOI: [10.5580/IJHA.24221](https://doi.org/10.5580/IJHA.24221)

## Abstract

The omohyoid muscle is one of the muscles of the hyoid bone and consists of an upper and a lower belly, joined by an intermediate tendon. The upper belly is located in the anterior cervical triangle and the lower belly crosses the posterior cervical triangle. It presents with anomalies regarding upper belly size and number, origin and insertion sites, as well as the binding of bellies with the sternohyoid muscle quite often. This paper includes studies and reports about the variations of the omohyoid muscle that have been reported in literature since 1881. The research was undertaken electronically using Medline and Embase. The search produced many articles. 13 articles were finally chosen for discussion in this review study due to their interest. The omohyoid muscle is an important landmark of the neck and its anatomical variations are very important and must be kept in mind by neck surgeons to avoid complication.

## INTRODUCTION

It took several centuries to introduce the concept of normality, abnormality and variation of the human body. All this knowledge came from the works of many biologists, clinicians and anatomists, who flourished from the late 19th century till date. They have published many books and articles on the anatomical variations of the human body. However, to recognize anatomical variations, it is necessary to understand human anatomy. A precise knowledge of anatomical variations is essential to improve diagnostic and treatment modalities. New imaging techniques, as well as analysis of case report findings provide a plethora of data regarding variations of anatomical structures. Lack of knowledge of anatomical variation causes approximately 10% of clinical malpractice.

In this paper, a literature review of omohyoid muscle variations since 1881 are presented.

## ANATOMY OF THE OMOHYOID MUSCLE

The omohyoid muscle is one of the muscles of the hyoid bone and consists of an upper and a lower belly, joined by an intermediate tendon<sup>1,2</sup> (Fig.1). The muscle runs from the lower portion of the posterior cervical triangle, to the anterior cervical triangle, through the sternocleidomastoid<sup>3,4</sup> (Fig.2). This muscle is surrounded by cervical fascia and as

it ascends, it crosses the posterior cervical triangle from outside inwards<sup>5</sup>. The omohyoid muscle originates just medial to the shoulder, a little farther from the scapular incision and finally, the lower rim of the body of the hyoid bone<sup>6</sup>. The two bellies of the muscle are linked by a tendon anchored on the clavicle fascia<sup>7</sup>.

The upper belly is located in the anterior cervical triangle, while the lower belly crosses the posterior cervical triangle, subdividing it into a small subclavian triangle downwards and a much greater occipital triangle upward. The omohyoid is innervated by branches of the cervical loop (anterior branches of C1 to C3 roots) and functions as a depressor of the hyoid bone<sup>5,6</sup>.

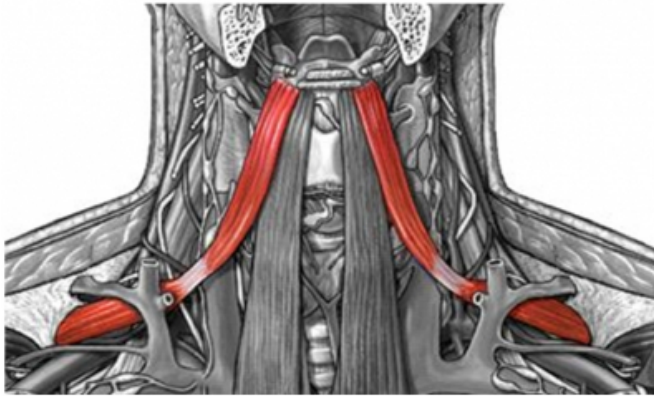
By pulling the hyoid bone downwards, the muscle assists in blood flow through the jugular vein. The jugular vein could be internal or external. The external jugular vein is formed by the contribution of the posterior auricular vein. It runs downward, over the sternocleidomastoid muscle and empties into the subclavian vein. The internal jugular vein drains blood from the correlating veins of the head and neck. It runs along the neck and is connected to the subclavian vein, to form the ipsilateral anonymous vein<sup>3,5</sup> (Fig.3).

The muscle is an important guide during dissection of the neck, since it defines the surgical site for level III and IV

lymph node metastases<sup>8,9</sup>. Since contraction of the omohyoid muscle may cause dilation of the neck veins, it may be responsible for creating an air embolism, after trauma or surgery to the area.

**Figure 1**

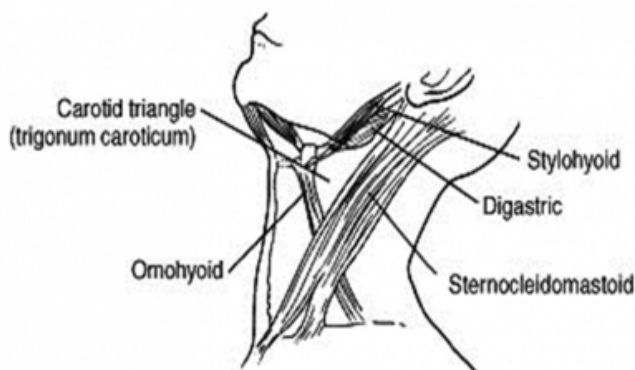
Left and Right Normal Omohyoid Muscles



{<http://studydroid.com/imageCards/05/er/card-5729629-front.jpg>}

**Figure 2**

Schematic of the Left Carotid Triangle

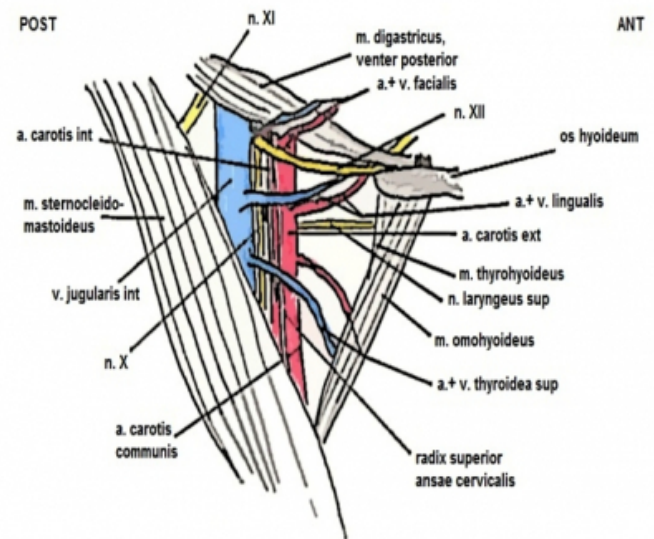


{[http://www.ufrgs.br/immunovetmolecular\\_immunology/circulation.html](http://www.ufrgs.br/immunovetmolecular_immunology/circulation.html)}

**Figure 3**

Schematic of the Carotid Triangle where are shown the exact relations of its several anatomical elements

### TRIGONUM CAROTICUM



{<http://kirkae.blog.cz/1102topografie-hlav-y-a-krku-trigonum>}

## REVIEW OF THE LITERATURE

The incidence of abnormalities in the omohyoid muscle is high regarding origin and insertion sites, as well as the number of bellies. Many abnormalities regarding upper belly size and number, origin and insertion sites, as well as the binding of bellies with the sternohyoid muscle have been reported<sup>6,10-12</sup>.

Anderson et al.<sup>6</sup> at 1881, were the first to deal with variations of the omohyoid muscle. After a surgery, they found double bellies (upper and lower) of the omohyoid muscle on the left side of an adult man. They also reported that the upper part of the muscle belly is from the muscles of the hyoid bone, while the lower belly probably has a common embryology with the subclavian muscle.

After dissecting 36 cadavers, Buntine<sup>7</sup> at 1970, found a thick piece of muscle in one of them, width of 1.5 cm, attached to half the posterior surface of the clavicle. The abnormal muscle passed upwards and inwards, a levator of deep fascia and beneath the hanger around the intermediate omohyoid muscle tendon. It did not present an intermediate tendon and was connected to the hyoid bone superiorly, to the rest of the omohyoid muscle. This unusual muscle covered the anterior scalene and some other related structures in the root of the neck. The muscle fibers were separated from those of the sternohyoid muscle but because of proximity, the muscle could be regarded as an

independent part of the sternohyoid and not part of the omohyoid muscle. However, the muscle in this study was classified as part of the omohyoid muscle.

Fukuda et al.<sup>13</sup> noticed an unknown muscle connected to the caudal end of the clavicle in a 56-year old man, who was treated for squamous cell carcinoma in the right lateral border of his tongue. The muscle runs upward to the hyoid bone. The omohyoid muscle with intermediate tendon was located laterally to the unknown muscle. Finally, the end of both muscles were conjoined near the hyoid bone by the same tendon. The muscle found in this patient cannot be classified into any of the omohyoid muscle variants reported by E. Loth<sup>14,15</sup>. Omohyoids with both the intermediate tendon, and the clavicle-hyoid muscle were found in the patient. According to Loth's classification, this variant of the muscle is closer to the type 2, except that in this case, the muscle had tendon incision. The third category of Loth could not be applied in this case, because the patient had the clavicle-hyoid muscle. For these reasons, the variation observed in this patient appears to be between type 2 and type 3 of Loth's classification<sup>15,16</sup>.

In a completely different case, Shih et al.<sup>17</sup> at 1998 observed an 11-year old boy with a swollen mass on the left side of his neck for six months. A mild decrease in the movement range of the neck was observed, since the mass gradually increased. There was no history of trauma, congenital lesion or injury to the neck. Imaging tests show a solid mass of 3 cm, located behind the left sternocleidomastoid muscle which extends down to the hyoid bone. During surgical exploration, the sternocleidomastoid muscle was observed to have a normal morphology. A hard mass (3.0 X 2.5 X 2.5 cm) was rejected at the upper belly of the left omohyoid muscle, which reduced the muscle belly size and pulled the hyoid bone toward the shoulder. After surgery, the hyoid bone returned to its normal position in six months. According to the researchers, a bumpy omohyoid can cause torticollis under many conditions. Fibrosis of cervical muscles has never been reported, except the sternocleidomastoid muscle fibrosis. The turning of the neck was not significantly affected, since this function is mainly controlled by the sternocleidomastoid. The etiology of omohyoid muscle fibrosis cannot be determined from only this case. Fibrosis of the omohyoid muscle should be included in the differential diagnosis of torticollis.

Tubbs et al.<sup>10</sup> found an unusual variant regarding the origin of the omohyoid muscle in a 59-year old man, during an anatomy course at the University of Alabama in

Birmingham. The lower belly of the muscle is connected to the inner rim of the suprascapularis incision but not on the ligament. However, the superior belly of the muscle, originated from the transverse process of C6, anterior to the middle scalene muscle in the shoulder. The omohyoid muscle showed physiological connections with the hyoid bone and shoulder. The intermediate tendon is attached to the carotid artery, and there is a distinct ridge in the upper belly of the muscle. The researchers emphasized the importance of recognizing muscle variations inside the throat, which can lead to serious problems due to their small size and complex structural arrangement. An abnormality of the muscles in the inner region of the neck, can be easily misdiagnosed as a cyst, aneurysm, lymph adenopathy, or metastasis.

Hatipoglu et al.<sup>18</sup> found an unknown muscle in the left anterior cervical region of a 57-year old male cadaver. They stated that the origin and insertion sites of the unknown muscle was considered to be the clavicle-hyoid muscle. The clavicle-hyoid originated from the distal clavicle end and is connected to the hyoid bone. The omohyoid muscle was present normally on the side with the intermediate tendon. Both muscles were conjoined, near the hyoid bone and connected with the same tendon. On the medial side, the sternohyoid muscle was observed and abnormalities or lesions of cervical soft tissues were absent.

Sukekawa et al.<sup>19</sup> at 2006 observed in 34 cadaveric specimens that the upper belly of the omohyoid muscle had a vertically long triangular shape with the apex, at the lower part of the intermediate tendon and the base along the upper side of the hyoid bone. The length of the belly was approximately 7 cm, while the width of the central region was about 2 cm. In 43 specimens, a normal morphology was observed. In six specimens, an abnormal morphology of the muscle was observed on both sides of the cleido-hyoid muscle and on one side, there was an intermediate tendon. The upper belly of the omohyoid muscle is connected to the sternohyoid muscle while adhesion was observed at the end of both sides in the upper belly of the sternohyoid through the supernumerary muscle bellies. The remaining 18 specimens were considered as intermediate morphologies and classified into four types based on the degree of development and number of muscle bellies.

During surgery of a 55 year old man with cancer of the tongue, Kasapoglu et al.<sup>9</sup> found that the lower belly of the omohyoid muscle passed deep into the sternocleidomastoid muscle normally but unexpectedly appeared behind the inner

jugular vein, before resulting in an intermediate tendon. Since all the variations of the omohyoid muscle have been found, this variant was not reported again. This variation is of great clinical interest and may increase the risk of iatrogenic rupture of the internal jugular vein. Injury of the internal jugular vein may lead to higher morbidity and mortality in the lower part of the vein and the omohyoid muscle is key to its detection. This anatomical variation is therefore very important and must be kept in mind by neck surgeons, to prevent a serious and potentially fatal complication.

The embryological origin of the omohyoid muscle is different from other neck muscles. Many variants have been reported to be caused by aplasia, different origin and insertion sites, as well as neurite insertion or multiple bellies<sup>6,20-22</sup>. However, variations in the lower belly of the muscle is very rare. Kim et al.<sup>22</sup> were the first to observe and report the combined variation of omohyoid and levator muscles in the thyroid gland. These investigators found a variant omohyoid muscle during the surgery of a 51-year old Korean woman. On the right side, they found a double omohyoid muscle, while on the left side a levator muscle was found in the thyroid gland. The levator muscle originates from the lower limit of the thyroid cartilage and enters the edge of the thyroid gland. The upper omohyoid muscle had a normal appearance presenting two bellies and an intermediate tendon. The lower omohyoid muscle presented the classical origin site but the connecting intermediate tendon was absent. The variations presented in this study are of high clinical interest to physicians during endoscopic diagnosis and surgery because of the increased risk of iatrogenic artery and nerve injury. The embryological origin of the omohyoid and levator muscles of the thyroid gland may be similar based on findings from relevant literature.

In an anatomical operation, Rai et al.<sup>14</sup> observed a double omohyoid muscle in the right side of a 53-year old male cadaver. This abnormal muscle originated from the inner transverse ligament of the shoulder, and after a course of 2.1 cm, it divided into the upper and lower omohyoid muscles. The upper omohyoid muscle had a normal morphology, with an upper and a lower belly and the intermediate tendon in between. The lower omohyoid muscle was considered as an independent part of the sternohyoid, while the lower tendon slot of the muscle was absent. Several variations have been reported for omohyoid muscle in the medical literature, but a complete double omohyoid muscle, from the shoulder to the

hyoid bone, as in this case, is a rare event. Therefore, knowledge of these omohyoid muscle abnormalities is important, in order to minimize complications during surgery of the cervical region.

At 2008, Rai et al.<sup>8</sup> conducted one of the largest studies in 35 male cadaveric specimens, where after removing the anterior and posterior triangle of the neck, they observed the omohyoid muscle, focusing on the differences in number, connections and position of the muscle. Among the 35 studied cadavers, a double omohyoid was observed in one specimen. The senior omohyoid had normal upper and lower bellies joined by an intermediate tendon. In contrast, the lower omohyoid merged with the sternohyoid muscle. In three subjects, an abnormal insertion site was reported behind the sternocleidomastoid muscle and in two subjects, the omohyoid was significantly smaller. In the remaining samples, normal morphology and course of the omohyoid muscle was observed. Miura et al.<sup>23</sup> reported similar results to that obtained from Rai et al.'s study<sup>8</sup>. They found an abnormal muscle on the right anterior cervical region of a 68 year old Japanese man. The investigators observed a case of double superior omohyoid muscle belly, with a portion entering the hyoid bone while the other part joined the sternohyoid muscle. They proposed that this muscle may be a vestigial structure in humans, also occurring in lower vertebrates such as reptiles, etc.

Ashwini et al.<sup>24</sup> at 2012, leading a course of pre-degree medical students, observed a muscular deviation of the omohyoid muscle at the right side of the neck of a 55 years old male cadaver. The superior belly (venter superior) of the muscle was absent, whilst the inferior belly arised from it's normal position, the superior border of the scapula. The inferior part of the muscle passed through the anterior triangle and then posteriorly of the Sternocleidomastoid muscle (SCM). The length of this part of the omohyoid was 6,5 cm and it was near the upper trunk of the brachial plexus. In it's upper way the omohyoid's muscle fibers were heavily knotted with the deep fascia of the SCM in it's posterior surface. By the cause of the absence of venter superior, the main trunk of the muscle was insufficiently deviated inside the anterior triangle of the neck. The researchers pointed that the close contact of the intermediate tendon with the anterior wall of the internal jugular vein, has a negative result in the vein's fuction since the muscle contraction has a direct impact in the vein's sheath.

On the other hand, Mizen et al.<sup>25</sup>, after examination of 30 cadavers concluded that the position of the omohyoid muscle

is not always constant. For this reason, they consider it as an unreliable surgical landmark during surgical procedures in the cervical zone and urge surgeons to stop using it as a guide point. There is no evidence to show that the omohyoid muscle is an oncology barrier and this study emphasizes its unreliability as an anatomical landmark, since it does not separate the jugular group of nodes into three equal levels. These findings and the fact that at least 9 to 14% of patients in the study showed no pathological evidence of metastases, led researchers to propose that neck dissection for oral and oropharyngeal cancer, should include the level IV and ignore the position of the omohyoid muscle.

### **DISCUSSION**

Variants of the omohyoid muscle are very important, because of their close relationship with the great vessels and brachial plexus. Due to direct attachment of the tendon to the wall of the inner jugular vein, muscle contraction has a direct influence on it.

Anderson<sup>6</sup> at 1881 first proposed that the upper belly of the omohyoid muscle belongs to the muscles of the hyoid bone, while the lower belly probably has a common embryology with the subclavian muscle. Also, he commented that the origin of the upper belly of the omohyoid muscle differs from the lower belly<sup>10,17</sup>. Following these observations, several authors have subsequently reported and dealt with the variations of the omohyoid muscle.

From the study of literature, we understand that variations in the upper belly of the omohyoid muscle are more common, compared to the lower belly<sup>1,8,10,14,26</sup>. The action of this muscle lifts the hyoid bone and researchers believe that it also pulls the lower part of the neck of the deep fascia during prolonged inspiration, reducing the tendency of aspirating soft tissues inward. Some researchers stated that the omohyoid muscle is activated during mandibular pressure and rotation of the head<sup>10,22</sup>. Other investigators have described the omohyoid muscle implication, in expansion of inner and external jugular veins, during the opening of the mouth<sup>8,12-14,21,27</sup>. Therefore, the muscle's action facilitates the venous return to the heart. Furthermore, fibrosis and contraction of the omohyoid muscle can cause torticollis<sup>17</sup>. Researchers<sup>8,10,18,22</sup> found that the internal jugular vein is compressed by the omohyoid and speculated that this could lead to changes in intra-cerebral venous hemodynamics. They also suggested that compression of the internal jugular vein by the omohyoid, can lead to the phenomenon of regression, equivalent to venous valves,

which can play an important role in cerebral protection during processes such as laughter or forced inhalation. It is unclear, however, whether this muscle could contribute to the compression of the internal jugular vein, as it passes behind the carotid artery. Generally, the omohyoid muscle expands the cervical fascia during inhalation and thereby maintains the dilation of the internal and external jugular veins<sup>5,9,10,13,14</sup>.

On the other hand, many researchers stated that the omohyoid is the best landmark in identifying the medial jugular vein, since any change to it can increase the risk of injury and complication during surgical procedures in the lower region of the neck<sup>3,5,8,10,12,14,19</sup>. A rupture of the internal jugular vein can cause a serious complication and may prove fatal. The injury leads to high morbidity and mortality, which usually occurs in the lower part of the vein. For this reason, the omohyoid muscle is an important landmark for the detection of this level (Fig.2,3). The anatomical variations are therefore very important and must be kept in mind by head and neck Surgeons, to avoid a potentially serious and fatal complication. Mizen et al.<sup>25</sup> is one of the minority of the researchers who believes that the anatomical variations of the muscle is of great concern for a credible landmark during surgery in this area. Another problem is the variable distance between the tendon and the clavicle. If this is truly discerned then there is a lot of evidence that the connection, morphology and exact place of the muscle is also of great variable, pointing that a node lymph is going to differ a lot.

There is also a lot of indications that metastases from malignant neoplasms of oropharynx and specially from the tongue, don't have a methodical spreading and frequently is omitting to be excluded during surgery. Researchers have affirmed that lymph nodes smaller than 3 mm can be affected and have micro-metastases. There is not enough evidence pointing out that omohyoid muscle is in fact a credible oncological barrier, hence Mizen's study adds more clues for the unreliability of the muscle as an anatomical landmark. These findings in conjunction with the fact that at least 9-14 % of the patients in its study didn't show any evidence of metastases, could lead in the deduction that the neck dissection for oral and oropharyngeal cancer should include level IV surgery and can ignore omohyoid muscle.

It is interesting to note that the TNM staging of American Joint Committee on Cancer (AJCC) of Head and Neck cancer, uses the invasion of the cricoid cartilage as a IV stage and not the boundary of omohyoid muscle, although

the thinking of the committee was based primary in the difficulty of identifying the muscle's boundaries via CT and MRI rather than the great variations of its position. In the aggregate, the plethora of variations of omohyoid muscle and the Levator muscle of the thyroid gland -which are in great proximity to the hyoid bone- are of great clinical consideration<sup>25,28</sup>. Therefore, evidence based information regarding muscular diversity comes of great assistance during surgical procedures, helping to avoid iatrogenous injuries and contributes to correctly examining the area of the neck. The necessity of understanding the muscular variations are of great clinical significance on the grounds that endoscopic surgeries have been vastly increased in the past decade and Imaging Diagnosis have been pushed forward with the developing of MRI and augmenting the clarity of CT techniques<sup>22</sup>.

## References

- Gray H. Gray's Anatomy. Descriptive and Surgical. 1st Ed., Philadelphia:Running Press.,1901; p.321.
- Williams P.L., Dyson M. Gray's Anatomy. ELBS and Churchill Livingstone. 38th Ed., 2005; p.807.
- Grant J.B. A method of Anatomy. Descriptive and Deductive. 2nd Ed., Baltimore:Williams & Wilkins., 1940: pp.628-629.
- Cunningham's Textbook of Anatomy., 10 th Ed. Edited by Romanes G.J., Oxford University Press., 1964.
- Gardner E., Gray D.J., O'Rahilly R. Anatomy: A regional study of human structure. 4th Ed., Philadelphia: WB Saunders.,1975; p.704.
- Anderson R. J. The morphology of the omohyoid muscle. Dublin J. Med. Sci., 1881; 10: 1–17.
- Buntine, J.A. The omohyoid muscle and fascia: morphology and anomalies. N. Z. J. Surg., 1970; 40:86–88.
- Rai R, Ranade AV, Nayak SR, Vadgaonkar R, Pai MM, Krishnamurthy A. A study of anatomical variability of the omohyoid muscle and its clinical relevance. Clinics, 2008; 63:521-524.
- Kasapoglu F, Dokuzlar U. An Unknown variation of Omohyoid Muscle. Clin. Anat., 2007; 20:964-965.
- Tubbs R.S., Salter E.G., Oakes W.J. Unusual origin of the omohyoid muscle. Clin. Anat., 2004;17: 578–582.
- Wood J. Additional varieties in human myology. Proc. Roy. Soc. Lond., 1865; 14: 379-392.
- Macalister A. Additional observations on muscular anomalies in human anatomy (third series) with a catalogue of the principal muscular variations hitherto published. Trans. Roy. Irish. Acad., 1875; 25: 1-134.
- Fukuda H., Onizawa K., Hagiwara T., Iwama H. The omohyoid muscle: a variation seen in radical neck dissection. Br. J. Oral. Maxillofac. Surg., 1998; 36: 399–400.
- Rai R, Nayak S.R., Ranade A.V., Prabhu L.V., Vadgaonkar R. Duplicated omohyoid muscle and its clinical significance. Rom. J. Morphol. Embryol. 2007; 48:295-297.
- Loth E. Muskeln des Halses. In : Beiträge zur Anthropologie der Negerweichteile. Ed. Streker and Schroder, Stuttgart., 1912; pp.58-73.
- Loth E. Anthropologie des parties molles. Ed. Masson & Cie, Paris, 1931; pp.82-85.
- Shih TY, Chuang JH. Fibrosis of the omohyoid muscle--an unusual cause of torticollis. J. Pediatr. Surg., 1998; 33:741-742.
- Hatipoglu E.S, Kervancioglu P, Tuncer M.C. An unusual variation of the omohyoid muscle and review of literature. Ann. Anat., 2006; 188:469-472.
- Sukekawa R, Itoh I. Anatomical study of the human omohyoid muscle: regarding intermediate morphologies between normal and anomalous morphologies of the superior belly. Anat. Sci. Int., 2006; 81:107-114.
- Sañudo JR, Vázquez R, Puerta J. Meaning and clinical interest of the anatomical variations in the 21st century. Eur. J. Anat., 2003; 7: 1–3.
- Gegenbauer C. Über der Musculus Omohyoideus und sein Schlüsselbeinverbindung. Morph. Jahrb., 1876; BD 1, S 243.
- Kim I. D., Kim J. H., Park Y. J., Lee S. K. Variation of the Infrahyoid muscle: duplicated omohyoid and appearance of the levator glandulae thyroideae muscles. Yonsei Medical Journal, 2010; 51(6): 984–986.
- Miura M., Kato S., Itonaga I., Usui T. The double omohyoid muscle in humans: report of one case and review of the literature. Okajimas. Folia. Anat. Japan, 1995; 72: 81–89.
- Ashwini A. P., Naveen K., Satheesha N.B. Absence of the Superior Belly of the Omohyoid Muscle: A Case Report. Journal of Pharmaceutical and Biomedical Sciences, 2012; 23 (12):1-2.
- Mizen K.D., Mitchell D.A. Anatomical variability of omohyoid and its relevance in oropharyngeal cancer. Br. J. Oral. Maxillofac. Surg., 2005; 43:285-288.
- Tamega O.J., Garcia P.J. Soares J.C., Zorzetto N.L. About a case of absence of the superior belly of the omohyoid muscle. Anat. Anz., 1983; 154:39-42.
- Bolla S.R., Nayak S., Vollala V.R., Rao M., Rodrigues V. Cleidohyoideus. A case report. Indian Journal for the Practising Doctors, 2007; 3(6): 1-2.
- Woolgar J.A. Detailed topography of cervical lymph node metastases from oral squamous cell carcinoma. Int. J. Oral. Maxillofac. Surg., 1997; 26:3-9.

**Author Information**

**George Noussios, MD, PhD**

Laboratory of Sports Medicine in Department of Physical Education and Sports Sciences (at Serres), “Aristotelian”

University of Thessaloniki

Thessaloniki, Greece