

# Cryptogenic Enlargement Of Bilateral Superior Ophthalmic Veins

K Kragha

---

## Citation

K Kragha. *Cryptogenic Enlargement Of Bilateral Superior Ophthalmic Veins*. The Internet Journal of Radiology. 2015 Volume 18 Number 1.

DOI: [10.5580/IJRA.24453](https://doi.org/10.5580/IJRA.24453)

## Abstract

Bilateral enlargement of the superior ophthalmic veins may be seen in carotid cavernous fistula, cavernous thrombosis, Graves' orbitopathy, orbital pseudotumor, parasellar tumors, orbital varices, arteriovenous malformations, or cerebral edema. Bilateral enlargement of the superior ophthalmic veins may also be cryptogenic or idiopathic in nature.

Unilateral enlargement of the superior ophthalmic vein may be seen in carotid cavernous fistula, Graves' orbitopathy, orbital pseudotumor, parasellar tumors, orbital varices and arteriovenous malformations. Bilateral superior ophthalmic vein enlargement may rarely occur in cavernous thrombosis, Graves' disease, or carotid cavernous fistula or cerebral edema (1-3). A detailed description of carotid cavernous fistula is contained elsewhere. Briefly carotid cavernous fistula is abnormal communication between the cavernous sinus and carotid arterial system. Carotid cavernous fistula can be classified by cause (traumatic vs. spontaneous, velocity of blood flow (high vs. low flow), and anatomy (direct vs. dural, internal carotid vs. external carotid or both) (4). Carotid cavernous fistula presents as spontaneous red eye, chemosis of the conjunctiva, abducens nerve paresis or mild orbital congestion with proptosis, cranial or orbital bruit, pulsatile exophthalmos (4, 5).

The patient was not intubated during both the head CT and head CTA examinations. The patient's right superior ophthalmic vein measured approximately 6-9 mm and his left superior ophthalmic vein measured approximately 6 mm. Otherwise, the head CT and CTA of the head and neck were negative. Neurosurgery consult noted that (i) the patient's signs and symptoms were not profound, (ii) there was no evidence of carotid cavernous fistula because extra-ocular movements were not restricted and proptosis was not apparent, (iii) there was no neural deficit such as headache and elevated intracranial pressure or intradural pressure were unlikely. The patient subsequently had cerebral angiogram 5 days after admission which was negative for carotid cavernous fistula or any vascular abnormalities (Figs. 5 and 6). The patient was discharged from the hospital in less than 1 week.

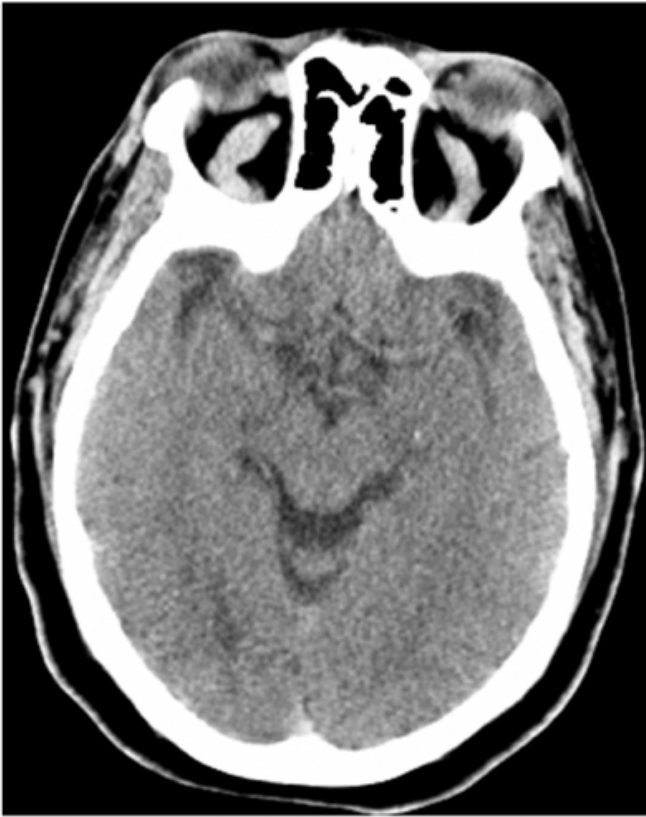## REPORT OF A CASE

A 52 year old male presented to the emergency room after falling down concrete stairs due to a push. Past medical history included hypertension and low back pain. The patient's Glasgow coma scale was 15. His physical and neurologic examinations were unremarkable.

Patient underwent non contrast head CT (Fig. 1) on arrival in the emergency room and about 5 hours later, CTA of the head (Figs. 2-4) based on the initial findings of enlarged bilateral superior ophthalmic veins so as to exclude carotid cavernous fistula. The head CTA that showed enlarged bilateral superior ophthalmic veins but no carotid cavernous

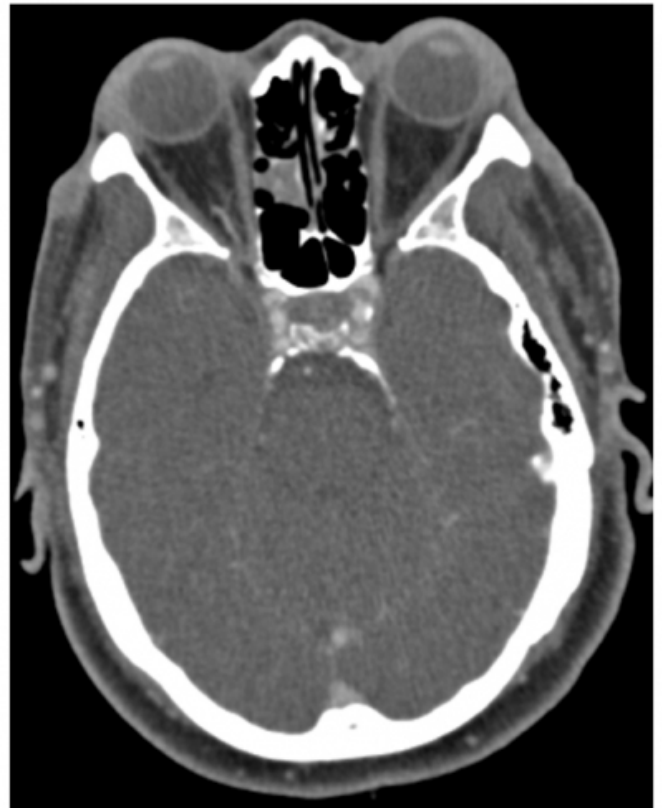**Figure 1**

Axial non contrast head CT shows enlarged bilateral superior ophthalmic veins.



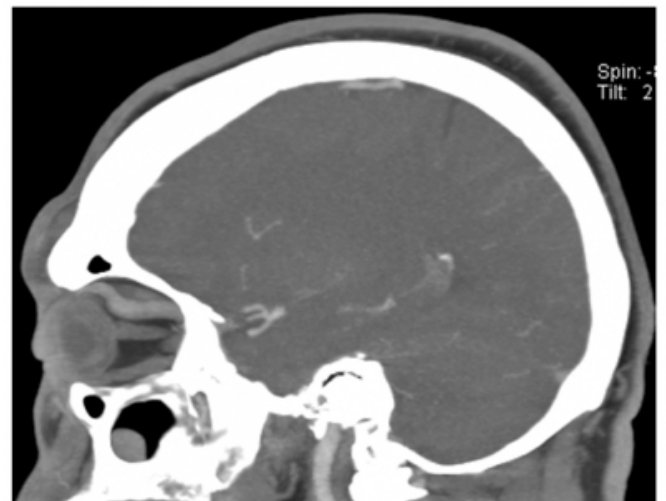
**Figure 2**

Axial contrast head CTA shows normal cavernous sinus.



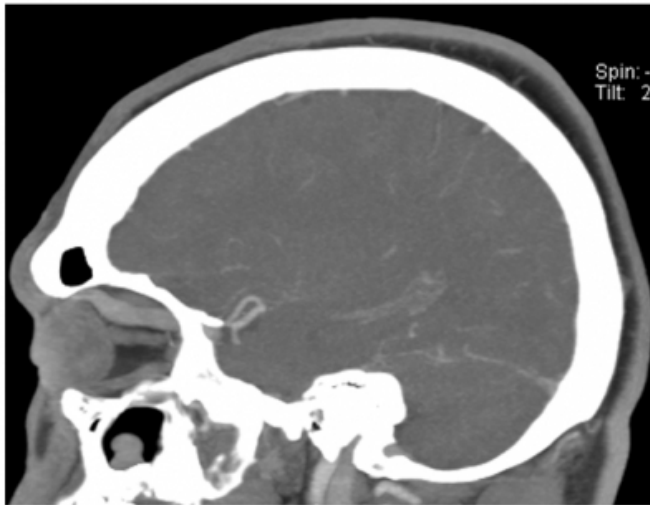
**Figure 3**

Sagittal contrast head CTA shows enlarged left superior ophthalmic vein.



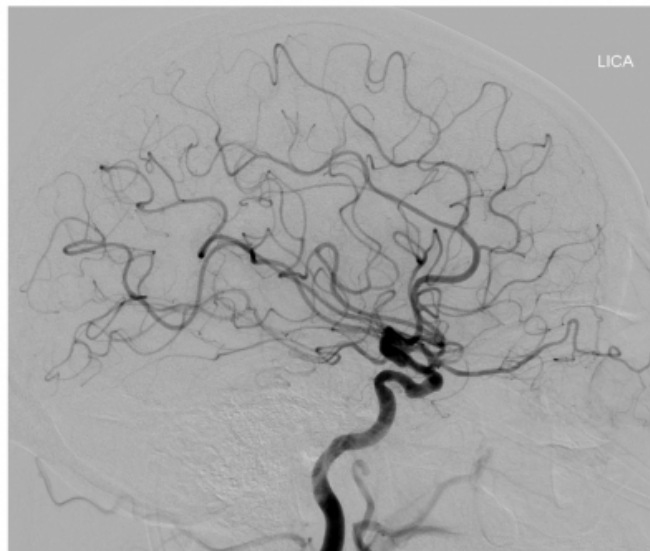
**Figure 4**

Sagittal contrast head CTA shows enlarged right superior ophthalmic vein.



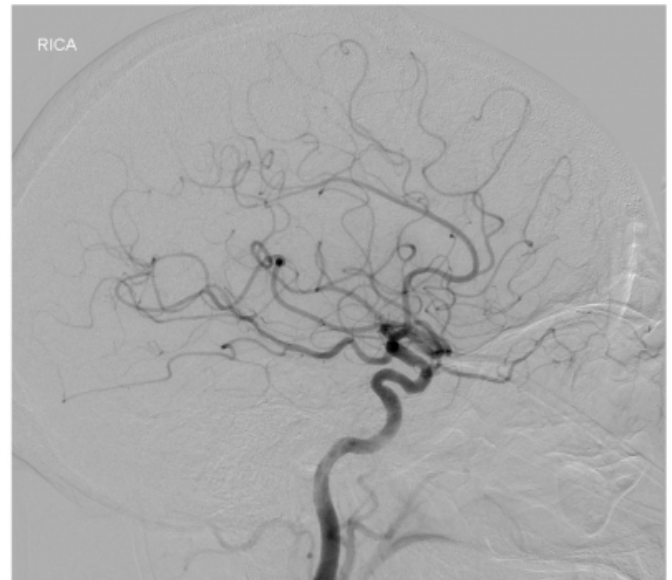
**Figure 5**

Normal angiogram (left internal carotid injection).



**Figure 6**

Normal angiogram (right internal carotid injection).



## DISCUSSION

On axial CT scan, a superior ophthalmic vein size of greater than 2-3 mm indicates possible enlargement, 3-4 mm, likely enlargement, and 4 mm or more, definite enlargement (3). The present patient's superior ophthalmic veins measures approximately 6-9 mm.

Enlargement of the superior ophthalmic vein may be seen in carotid cavernous fistula, cavernous thrombosis, Graves' orbitopathy, orbital pseudotumor, and parasellar tumors, orbital varices and arteriovenous malformations (1-3). Khana et al (3) reported 11 out of 55 with bilateral superior ophthalmic vein enlargement associated with cerebral edema that returned to normal size after cerebral edema resolved. These patients had closed head injury (2 patients), ruptured cerebral aneurysm (5 patients), ruptured large frontal and basal ganglia arteriovenous malformation (1 patient), posterior fossa ependymoma (1 patient), large basal ganglia hypertensive hemorrhage (1 patient), frontotemporal subarachnoid hemorrhage (1 patient). The present case had none of the above findings – the patient had a normal head CT, head CTA, and cerebral angiogram. The patient had no cavernous thrombosis, Graves' disease, carotid cavernous fistula, acute head bleed, closed head injury, tumor, seizure, sepsis, or intubation. It is noted that posttraumatic carotid cavernous fistula does not disappear spontaneously. The bilateral superior enlargement in this patient appears to be cryptogenic or idiopathic although intracranial pressure was not done because it was not clinically indicated.

## **SUMMARY**

Bilateral enlargement of the superior ophthalmic veins may be cryptogenic or idiopathic in nature.

## **References**

1. R. G. Peyster, P. J. Savino, E. D. Hoover, N. J. Schatz, "Differential diagnosis of the enlarged superior ophthalmic vein. J Comput Assist Tomogr", 8(1): 103-107, 1984.
2. B. R. Lima and J. D. Perry, "Superior ophthalmic vein enlargement and increased muscle index in dysthyroid optic nerve neuropathy", Ophthal Plast Reconstr Surg 29(3): 147-149, 2013.
3. R. H. Khana, C. J. Pham, G. M. Malik, E. M. Spickler, B. Mehta, M. L. Rosenblum, "Bilateral superior ophthalmic vein enlargement associated with diffuse cerebral edema: report of 11 cases", J Neurosurg 86(5P): 893-897, 1997.
4. N. R. Miller, "Dural carotid cavernous fistulas: epidemiology, clinical presentation, and management", Neurosurg Clin N Am 23: 179-192, 2012.
5. T. L. Tytle and P. K. Punukollu, "Carotid cavernous fistula", Seminars Cerebrovascular Diseases Stroke 1(1): 83-111, 2001.

**Author Information**

**K. O. Kragha, PhD, MBA, MD**

Department of Radiology University of Louisville

Louisville, KY, U. S. A.

kokragha@msn.com