

Subhepatic Appendicitis: A Diagnostic Dilemma

N Kumar, B Rehmani, A Kumar, B Chug

Citation

N Kumar, B Rehmani, A Kumar, B Chug. *Subhepatic Appendicitis: A Diagnostic Dilemma*. The Internet Journal of Surgery. 2015 Volume 32 Number 1.

DOI: [10.5580/IJS.27324](https://doi.org/10.5580/IJS.27324)

Abstract

Acute appendicitis is a common clinical condition, but sometimes diagnosis is delayed when appendix is at rare location. Subhepatic appendicitis is a rare condition. Diagnosis of subhepatic appendicitis is further delayed when there is cholelithiasis on Ultrasonography of abdomen. We are reporting a case of subhepatic appendicitis in young male with diagnostic difficulties and our experience.

INTRODUCTION

Subhepatic appendicitis was first described by King in 1955. [1] Atypical presentation of acute appendicitis may be due to varied position of the tip of the appendix. The location and spread of inflammation from acute appendicitis depends on the location of the appendix. Subhepatic appendicitis usually presents with right upper abdominal pain. It is clinically indistinguishable from acute cholecystitis. C T scan of abdomen is frequently required for confirmation of diagnosis in atypical cases of acute appendicitis, but when C T scan of abdomen is inconclusive then diagnostic laparoscopy is recommended. [2, 3]

CASE REPORT

A 25 year male presented in surgical emergency with acute pain in right upper abdomen. Pain was severe in nature and associated with nausea and vomiting. Clinical examination showing Pulse rate 100/minute with normal blood pressure and tender right hypochondrium. On the basis of these findings, patient was admitted with the diagnosis of acute cholecystitis. On work up, TLC was 12000/cmm with 92% polymorph and USG abdomen showing normal gall bladder. Initially the patient was managed conservatively and CECT abdomen was advised. CECT abdomen [Fig-1] was showing subhepatic appendicitis with high up ceacum and minimal free fluid in the subhepatic region. Patient was taken up for laparoscopic appendectomy. On surgery, ceacum and appendix was found at subhepatic region with inflamed and perforated appendix [Fig-2]. Appendectomy was done. Patient recovered well after surgery.

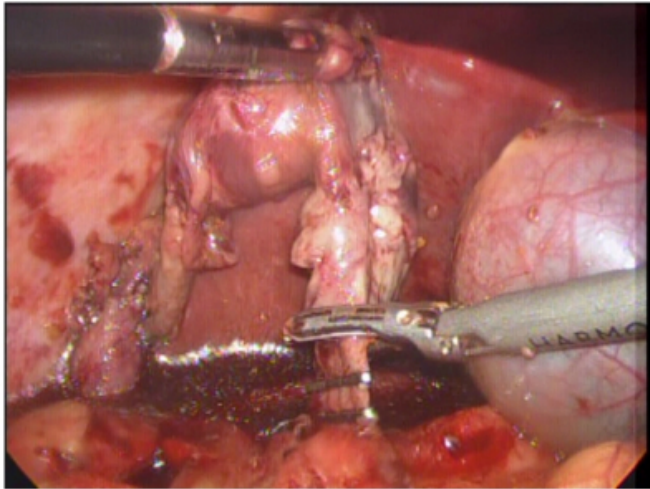
Figure 1

CECT abdomen showing subhepatic appendicitis with distended gall bladder

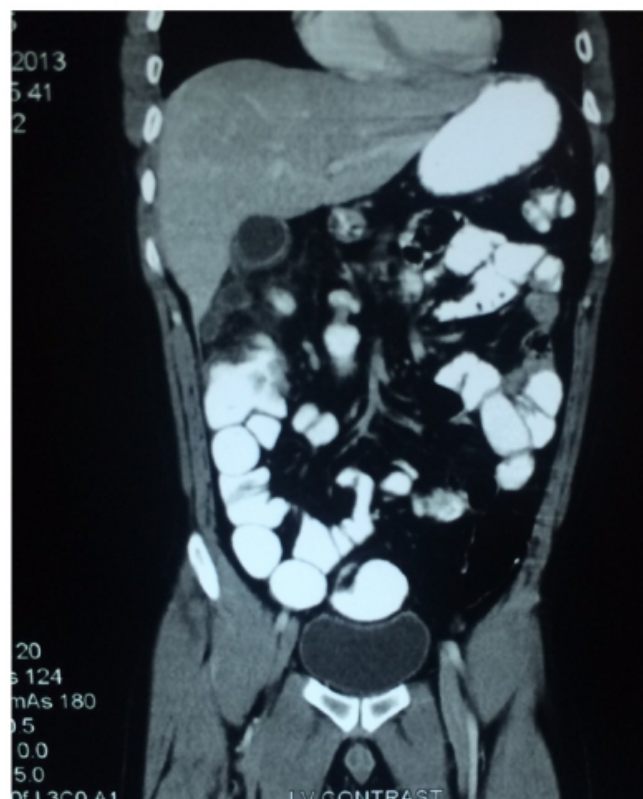

Figure 2

Laparoscopic appendectomy showing subhepatic perforated appendix and distended gall bladder



DISCUSSION

Acute appendicitis is one of the common clinical conditions of pain abdomen, but the classical clinical presentation may not be always present due to varied position of the tip of appendix. The different position of appendix are retrocecal (74%), pelvic (21%), subcaecal (1.5%), preilial (1%), and postilial (0.5%). [4]

Subhepatic appendicitis was first described by King in 1955 [1] Subhepatic appendicitis leads to delay in diagnosis and higher complication rates, including perforation and suppuration. [5,6] Diagnostic uncertainty due to non-classical evolution of acute appendicitis may occur when the appendix is anatomically mal-positioned.[3] The differential diagnosis of subhepatic appendicitis are acute cholecystitis, right ureteric colic and acute pyelonephritis etc.[7]

“During the development of the intestine, the vermiform appendix and caecum develop from the caecal bud of the post arterial segment of the midgut loop. In the initial stages of development, the caecum and the appendix are of the same diameter, but later, the appendix narrows down because of the faster growth of the proximal part of the caecal bud. The midgut herniated to the umbilical cord as a part of the physiological umbilical hernia in the sixth week of intrauterine life, and returns back to the abdomen in the tenth week of intrauterine life. When the intestine returns to the abdomen, the caecum and appendix occupy the subhepatic position. Later, in the eleventh week, they descend to the right iliac fossa”. [8, 9] “The subhepatic position of the appendix has been attributed to a failure of descent of the caecum during embryonic development”. [10]

Irrespective of age, the varied location of appendix is due to adhesions, which leads to atypical presentation, delay in diagnosis and increased adverse outcomes. [11]

Sub-hepatic appendicitis is very rare. Its incidence is 0.08% of all cases of appendicitis in one study from India. [12] Pre operative diagnosis of sub-hepatic appendicitis is difficult and usually diagnosed at laparoscopy for undiagnosed pain abdomen. Sub-hepatic appendicular abscess is the most common reported presentation. Sub-hepatic appendicitis usually mimic as acute cholecystitis. Ultrasound abdomen is usually used in suspected cases but C T scan of abdomen is more sensitive in diagnosing acute appendicitis especially in young female. [12, 13, 14] In situations where abdominal C T is inconclusive and clinical diagnosis of appendicitis is doubtful then diagnostic laparoscopy is recommended. [12]

CONCLUSION

Subhepatic appendicitis is difficult to diagnose clinically. It is diagnosed either after contrast enhanced computed tomography scan of abdomen or after diagnostic laparoscopy for acute abdomen. It is best to go for diagnostic laparoscopy in acute abdomen whenever there is diagnostic difficulty.

References

1. King A: Subhepatic appendicitis. *AMA Arch Surg* 1955, 71(2):265-267. PubMed Abstract
2. Kraemer M, Franke C, Ohmann C, Yang Q: Acute appendicitis in late adulthood: incidence, presentation, and outcome. Results of a prospective multicentre acute abdominal pain study and a review of the literature. *Langenbecks Arch Surg* 2000, 385(7):470-481. PubMed Abstract
3. de Dombal FT. Acute abdominal pain in the elderly. *J Clin Gastroenterol.* 1994;19:331-335, PubMed
4. Ronan O'Connell P. The vermiform appendix. In: Williams NS, Bulstrode CJK, Ronan O'Connell P, editors. *London (LN): Edward Arnold (Publishers) Ltd; 2008.* pp. 1204-1218
5. Kulvatunyou N, Schein M: Perforated subhepatic appendicitis in the laparoscopic era. *Surg Endosc* 2001, 15(7):769. PubMed Abstract
6. Ates M, Sevil S, Bulbul M: Routine use of laparoscopy in patients with clinically doubtful diagnosis of appendicitis. *J Laparoendosc Adv Surg Tech A* 2008, 18(2):189-193. PubMed Abstract.
7. Kim S, Lim HK, Lee JY, Lee J, Kim MJ, Lee AS. Ascending retrocecal appendicitis: clinical and computed tomographic findings. *J Comput Assist Tomogr.* 2006; 30:772-776. [PubMed]
8. Applegate KE, Anderson JM, Klatte EC. Intestinal malrotation in children: a problem-solving approach to the upper gastrointestinal series. *Radiographics.* 2006; 26:1485-1500. [PubMed]
9. Awapittaya B, Pattana-arun J, Tansatit T, Kanjanasilpa P, Sahakijrungruang C, Rojanasakul A. New concept of ileocecal junction: intussusception of the terminal ileum into the cecum. *World J Gastroenterol.* 2007;13:2855-2857.[PubMed]

10. Linder HH. Embryology of gastrointestinal tract. In: Linder HH, editor. *Clinical Anatomy*. East Norwalk (CT): Appleton & Lange; 1989. p. 275–2
11. Schumpelick V, Dreuw B, Ophoff K. Appendix and cecum. Embryology, anatomy, and surgical applications. *Surg Clin North Am*. 2000;80:295–318. doi: 10.1016/S0039-6109(05)70407-2.[PubMed]
12. Palanivelu C, Rangarajan M, John SJ, et al. Laparoscopic appendectomy for appendicitis in uncommon situations: the advantages of a tailored approach. *Singapore Med J* 2007;48:737–40
13. Patel NR, Lakshman S, Hays TV, et al. Subhepatic appendix with fecalith mimicking acute cholecystitis with gallstone. *J Clin ultrasound* 1996;24:45–7
14. Ong EM, Venkatesh SK. Ascending retrocecal appendicitis presenting with right upper abdominal pain: utility of computed tomography. *World J Gastroenterol* 2009; 15:3576-9

Author Information

Navin Kumar, Assistant Professor

Department of Surgery, Himalayan Institute of Medical Sciences
Dehradun, India
surgeon_navin@yahoo.co.in

Babar Rehmani, Associate Professor

Department of Surgery, Himalayan Institute of Medical Sciences
Dehradun, India

Abhishek Kumar, Junior Resident

Department of Surgery, Himalayan Institute of Medical Sciences
Dehradun, India

Bhavishaya Chug, Junior Resident

Department of Surgery, Himalayan Institute of Medical Sciences
Dehradun, India