

Pleomorphic Rhabdomyosarcoma Of The Urinary Bladder ?mitating A Pelvic Mass: A Case Report

C Ceylan, T A Serel, A Albayrak, O G Doluoglu

Citation

C Ceylan, T A Serel, A Albayrak, O G Doluoglu. *Pleomorphic Rhabdomyosarcoma Of The Urinary Bladder ?mitating A Pelvic Mass: A Case Report*. The Internet Journal of Urology. 2013 Volume 11 Number 2.

Abstract

Aims: Rhabdomyosarcoma of the urinary bladder is exceedingly rare in adults. The most common type is pleomorphic rhabdomyosarcoma. So far, more than a hundred of case reports were published in the literature about adult urinary rhabdomyosarcoma, but our case is the 23th pleomorphic type adult rhabdomyosarcoma in the literature. So, we wanted to share this case report with other clinicians.

Presentation of Case: In this case report, we presented a patient who admitted to urology outpatient clinic with abdominal pain, painless hematuria and lower abdominal intumescence. First, imaging techniques showed a pelvic mass. Further investigations revealed bladder rhabdomyosarcoma. The mass had originated from the right side of the bladder and was partial excised with a pelvic operation by extraperitoneal. Our case died 11 months later after the initial diagnosis and radiotherapy and chemotherapy following partial cystectomy.

Discussion: Rhabdomyosarcomas are rarely seen tumors in adults. Metastasis of the primary tumor usually to the regional lymph nodes, lungs and liver. Presenting symptoms are hematuria, dysuria, and more frequently, bladder dysfunction in clinical practice. Because of the rarity of adult rhabdomyosarcoma of the bladder, optimal therapy is not clear.

Conclusion: Bladder involvement of Rhabdomyosarcomas has been reported very rare in the literature. Local recurrence is seen frequently as well as distant metastases. The survival is very short because of the aggressive behaviour of the tumor. Rhabdomyosarcoma has a rapid progression and poor prognosis.

INTRODUCTION

Rhabdomyosarcoma is one of the most common soft tissue sarcomas in children. However, rhabdomyosarcoma of the bladder occurs in the adult population, rarely. About 15% to 20% of all rhabdomyosarcoma cases are genitourinary origin (1). Pleomorphic rhabdomyosarcomas (PRMS) are rare tumors, accounting for up to 5% of all adult pleomorphic soft tissue sarcomas. PRMS are usually detected in the extremities especially in the thigh of middle-aged adults. Bladder involvement has been reported very rare in the literature (2,3).

CASE REPORT

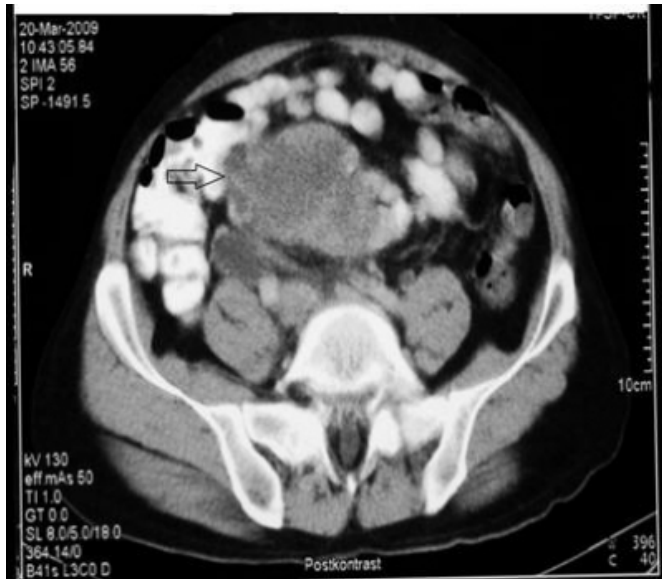A 57 year-old-man was admitted to our outpatient clinic with a 1 year history of hematuria without pain and cloth in urine. Physical examination revealed a palpable immobile mass beginning from the right bottom quadrant towards the middle of the abdomen. There was no operation history and disease. He has been smoking a package of cigarette per day for 40-years. Family history was unremarkable. There was a lot of erythrocyte at the urine analysis of the patient. The

laboratuary examination of the patient was normal.

(Hb:14.1g/dl, urea: 20 mg/dl, creatinine: 0.9 mg/dl). Urinary system ultrasonography revealed a 13x10 cm hyperechogenic calcified mass. Computerized tomography (CT) urogram demonstrated a smoothly contoured bladder filling defect. The abdominal CT showed a 13x10cm mass with the same configuration (Fig. 1).

Figure 1

A smoothly contoured bladder filling defect in CT (arrow).



The patient was hospitalized with the diagnosis of pelvic mass originating from the urinary bladder. He was consulted with general surgery department to decide whether the origin of the mass was intraperitoneal or extraperitoneal. Solid nonpapillary mass view was seen at the cystoscopy performed by general anesthesia before the operation. The mass was in the right lateral wall of the bladder in a surface of 5-6 cm². Urether orifice was normal. A biopsy was taken from the mass and the result of the biopsy was rhabdomyosarcoma. The mass had originated from the right side of the bladder and was partial excised with a pelvic operation by extraperitoneal. Approximately, 1 cm segment of the bottom of the ureter was excised. Subsequently, the ureter area which was excised previously enclosed within the primary sutures. Ureteroneocystostomy was performed to the right side. Then, a double-J (DJ) stent was located to the right side of the ureter. Some pericaval and periiliac immobile lymph nodules with the size of 1,5x1.5 cm were removed. The pathological diagnosis of the patient was reported as the pleomorphic type of rhabdomyosarcoma in the pathologic specimens. Gross examination revealed a well-demarcated tumoral mass by 13x10x8cm in size. On cross section examination, a soft, yellow colored necrotic tumoral lesion which includes some solid areas. By the light microscopy, the mass consisted of a small round-cell neoplasm with sarcomatous features. Neoplastic cells showed extensive pleomorphism and atypical mitotic figures, and some cells displayed abundant eosinophilic cytoplasm with rhabdoid appearance and the atypical mitotic figures (Fig. 2, 3 and 4). Immunohistochemistry revealed

strong cytoplasmic staining for desmin (Fig. 5) and vimentin (Fig. 6) and nuclear staining for myogenin (Fig. 7).

Figure 2

Pleomorphic rhabdomyosarcoma composed of intensely eosinophilic polygonal cells (H&E,X400).

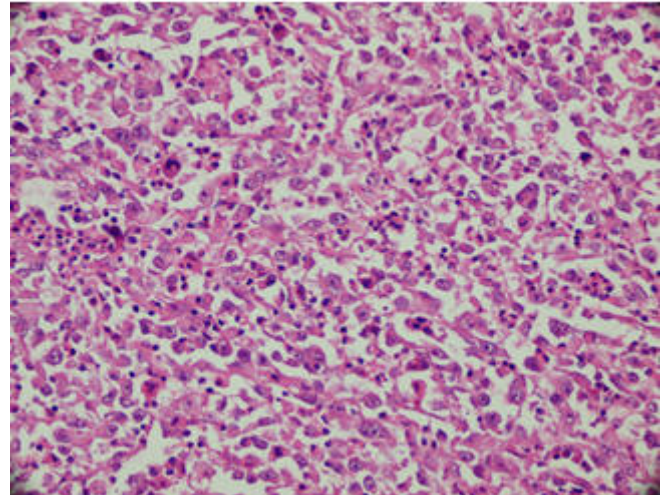


Figure 3

Rabdomyoblastic differentiation in the tumour (H&E,x400).

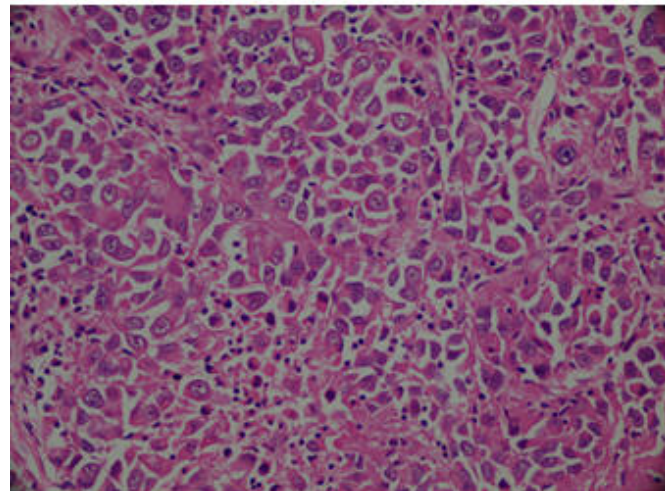


Figure 4

Note the pleomorphic tumor cells and the atypical mitotic figures (H&E,x400).

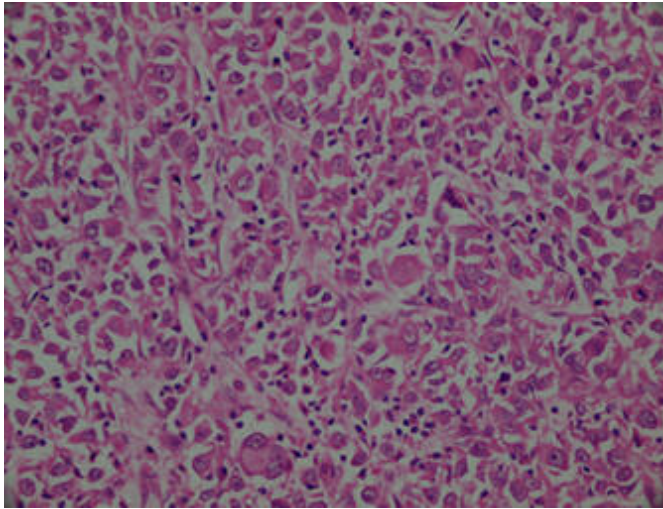


Figure 5

Strong diffuse desmin expression in pleomorphic rhabdomyosarcoma (Desmin, x400).

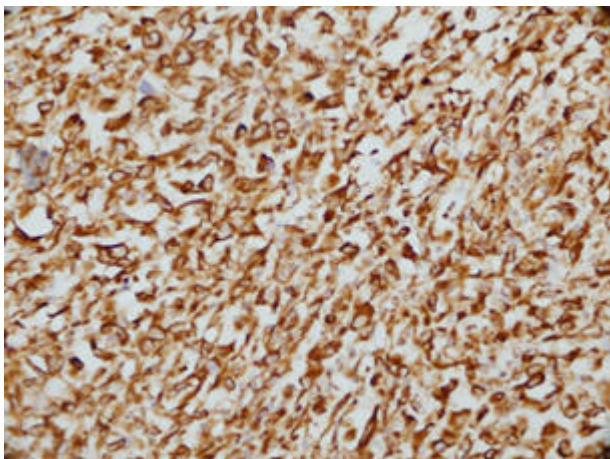


Figure 6

Diffuse, strong immunoreactivity for vimentin in an pleomorphic rhabdomyosarcoma (Vimentin,x200).

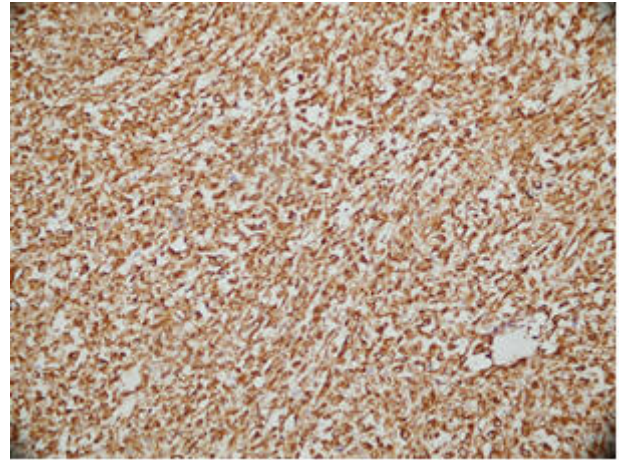
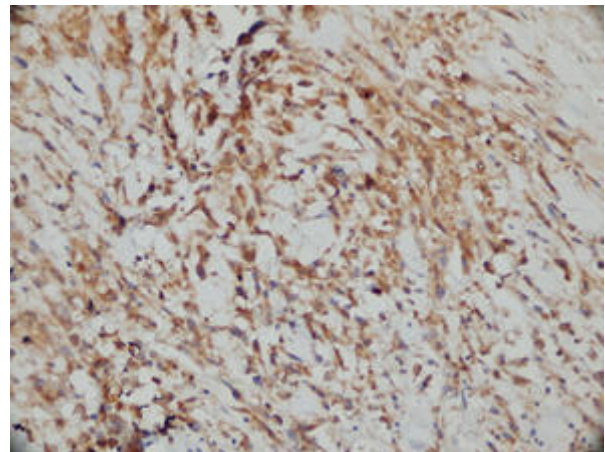


Figure 7

Nuclear staining for myogenin in an pleomorphic rhabdomyosarcoma (Myogenin,x400).



Four of the six lymph nodes were reported as positive. Pleomorphic rhabdomyosarcoma originating from the urinary bladder muscle layer without ureteral invasion, but with lymph node metastasis was detected. The postoperative course was unremarkable. He was discharged on 7th postoperative day with both urethral and ureteral catheters. The patient was referred to medical oncology and radiation oncology departments for follow-up. The patient treated with radiation therapy (25 Gy) and chemotherapy with actinomycin-D. Although the patient was treated, metastasis occurred at the patient. He died because of widespread lung and liver metastasis after a treatment of 11 months.

DISCUSSION

Rhabdomyosarcomas are rarely seen tumors in adults. The pleomorphic type is the most seen subtype in this age group

(3). To the best of our knowledge, there are few adult cases in the English literature (4-6). The tumor usually arises in the region of the trigone and invades the surrounding tissue, presenting as a mass with or without pain. The tumor usually recurs after the operation. Metastasis of the primary tumor usually to the regional lymph nodes, lungs and liver. Presenting symptoms are hematuria, dysuria, and more frequently, bladder dysfunction in clinical practice (6). Positive immunohistochemical staining with antimyoglobin antibody and antisarcomeric actin antibody, characteristic of striated muscle are very helpful in the diagnosis of rhabdomyosarcoma (7).

In our case, the pathological diagnosis of the patient was reported as the pleomorphic type of rhabdomyosarcoma. Examination of the pathologic specimen showed pleomorphic rhabdomyosarcoma composed of intensely eosinophilic polygonal cells with strong diffuse desmin expression and diffuse, strong immunoreactivity for vimentin and nuclear staining for myogenin were observed. If a tumour showing skeletal muscle differentiation, before considering the diagnosis of PRMS, differential diagnosis must be done between other pleomorphic sarcoma subtypes including differentiated liposarcomas, malignant peripheral nerve sheath tumours and metastasis from metaplastic carcinomas (8). Because of the rarity of adult rhabdomyosarcoma of the bladder, optimal therapy is not clear. The prognosis is poor in the majority of patients. Previously reported that three patients who treated by cystectomy and two by radiation therapy died 3 to 19 months later after the treatment (3). In our case, the patients treated by partial cystectomy and then, treated with radiation therapy (25 Gy) and chemotherapy with actinomycin-D. Although the patient was treated, metastasis occurred at the patient. He died because of widespread lung and liver

metastasis after a treatment of 11 months.

CONCLUSION

In conclusion, presented case who was successfully treated with partial cystectomy is a rare bladder pleomorphic rhabdomyosarcoma in the literature. In most cases, to preserve the functions of the bladder is recommended. Local recurrence is seen frequently as well as distant metastases. The survival is very short because of the aggressive behaviour of the tumor. Although chemotherapy and radiotherapy after the surgery were performed in this presented case, the prognosis was poor because of distant metastases and aggressive behaviour of the tumor and the survival was very short.

References

1. Krummerman MS, Katatikarn V: Rhabdomyosarcoma of the urinary bladder with intraepithelial spread in an adult Arch Pathol Lab Med; 1976;100: 395-97.
2. Furlong MA, Mentzel T, Fanburg-Smith JC: Pleomorphic rhabdomyosarcoma in adults: a clinicopathologic study of 38 cases with emphasis on morphologic variants and recent skeletal musclespecific markers. Mod Pathol; 2001;14: 595-603.
3. Little DJ, Ballo MT, Zagars GK, Pisters PW, Patel SR, El-Naggar AK, et al: Adult rhabdomyosarcoma. Outcome following multimodality treatment. Cancer; 2002; 95:377-88.
4. Rao MS, Radhakrishnan VV: Rhabdomyosarcoma of the urinary bladder in an adult: A case report. Indian J Cancer; 1973;10:463-467.
5. Evans AT, Bell TE: Rhabdomyosarcoma of the bladder in adult patients: Report of three cases. J Urol; 1965;94:573-575.
6. Lauro S, Lalle M, Scucchi L, Vecchione A: Rhabdomyosarcoma of the urinary bladder in an elderly patient. Anticancer Res; 1995;15:627-629.
7. Nakayama R, Nemoto T, Takahashi H, Ohta T, Kawai A, Seki K, et al: Gene expression analysis of soft tissue sarcomas: characterization and reclassification of malignant fibrous histiocytoma. Mod Pathol; 2007; 20: 749-759.
8. Nielsen TO: Microarray analysis of sarcomas. Adv Anat Pathol; 2006;13:166-173.

Author Information

C Ceylan

Department of Urology Clinic of Yuksek Ihtisas Education and Research Hospital
Ankara, Turkey

T A Serel

Department of Urology Clinic of Yuksek Ihtisas Education and Research Hospital
Ankara, Turkey

A Albayrak

Clinic of Pathology, Yildirim Beyazit Training and Research Hospital
Ankara, Turkey

O G Doluoglu

Department of Urology Clinic of Konya Numune Hospital
Konya, Turkey
drdoluoglu@yahoo.com