

# A Submucosal Colonic Lipoma With An Overlying Tubulovillous Adenoma: A Case Report

S Rait, A Goede, J Rait, N Mungalsingh

## Citation

S Rait, A Goede, J Rait, N Mungalsingh. *A Submucosal Colonic Lipoma With An Overlying Tubulovillous Adenoma: A Case Report*. The Internet Journal of Pathology. 2015 Volume 17 Number 1.

DOI: [10.5580/IJPA.29298](https://doi.org/10.5580/IJPA.29298)

## Abstract

Colonic lipomas with overlying adenomatous change are exceedingly rare with few reported cases.<sup>1, 2, 3</sup> This is a case report of a 74 year old female who was found to have a polyp on the ileocaecal valve that was not amenable to endoscopic mucosal resection. The patient subsequently underwent a successful laparoscopic right hemicolectomy. The diagnosis of a submucosal lipoma with an overlying low grade tubulovillous adenoma was made on histology.

## INTRODUCTION

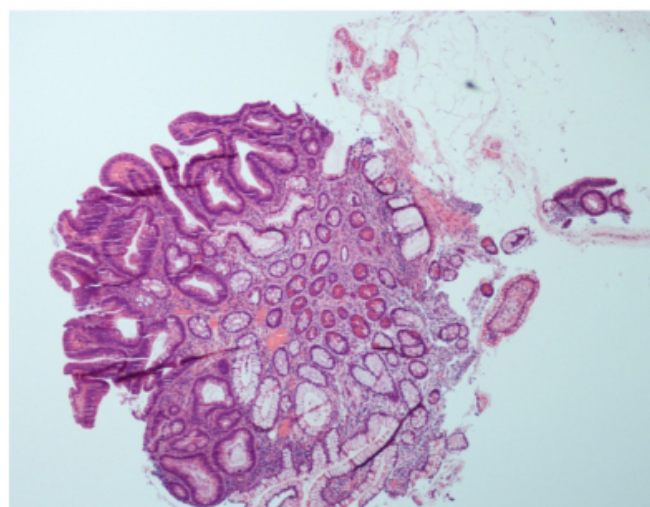
Colonic lipomas are a relatively rare phenomenon and can often be mistaken for invasive malignancy on imaging.<sup>1,2,3</sup> Important differential diagnoses in these cases include: adenocarcinoma, adenoma, lipoma and liposarcoma. We report a case of a submucosal lipoma with an overlying low grade tubulovillous adenoma diagnosed on histology after the patient underwent an uneventful laparoscopic right hemicolectomy.

## CASE REPORT

A 74 year old female with few co-morbidities had been followed since 2012 due to a change in bowel habit. At the time she had a polyp in the rectum which showed low grade dysplasia with a focus of high grade dysplasia. This was successfully removed. Given the patient's history, routine surveillance was conducted on an annual basis. A colonoscopy performed two years later revealed multiple polyps on the ileocaecal valve and was diagnosed as a low grade villous adenoma at the time (figure 1).

**Figure 1**

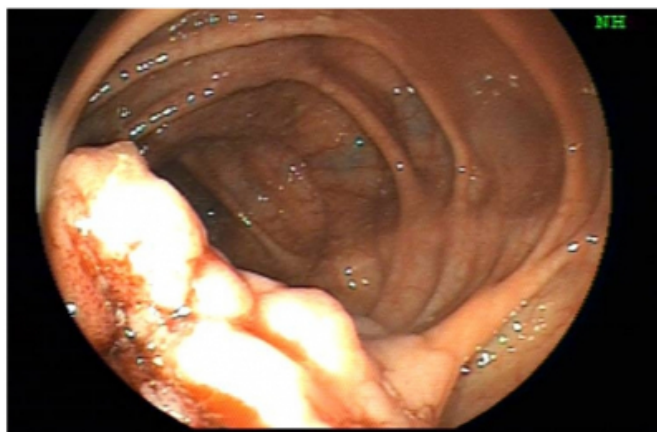
Villous adenoma



She was referred to our regional specialist endoscopy unit for endoscopic mucosal resection (EMR) (Figure 2). Complete EMR of the polyp was unsuccessful, and the options were explained to the patient. Given the size (40mm), the site (ileocaecal valve), the previous diagnosis of a low grade villous adenoma and not being amenable to EMR, a right hemicolectomy was subsequently performed.

**Figure 2**

Endoscopic image

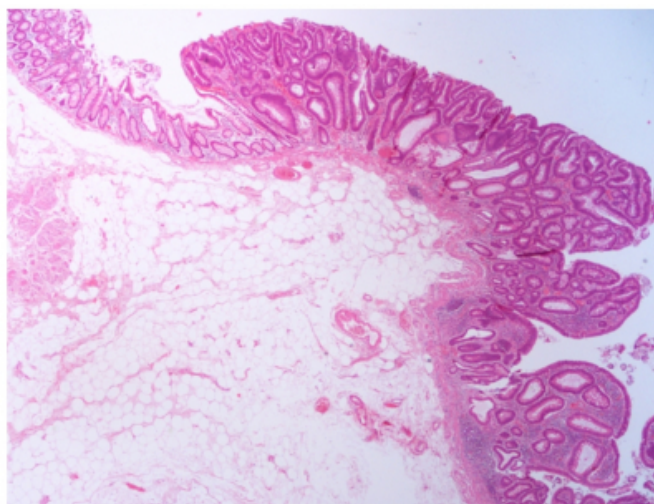


We received a right hemicolectomy specimen with attached appendix. There were no signs of perforation of the large bowel. Grossly a large sessile mass was seen at the ileocaecal valve that measured 40mm x 10mm. Slicing of the mass revealed a large soft, yellow ovoid mass underlying the colonic mucosa. The entire area was sampled for processing.

Histologically the sections showed a tubulovillous adenoma (with low grade dysplasia) in addition to a submucosal lipoma. The lipoma had a maximum diameter of 30mm. No high grade dysplasia or invasive malignancy was seen (figures 3, 4 and 5).

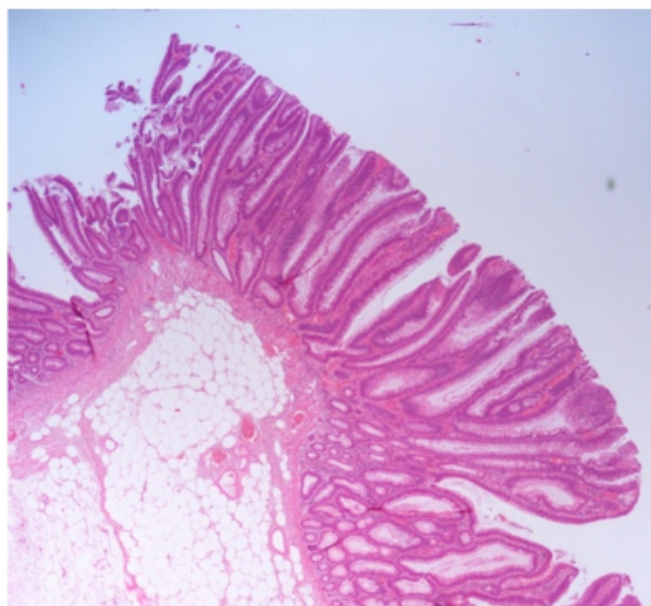
**Figure 3**

Tubulovillous adenoma with underlying lipoma



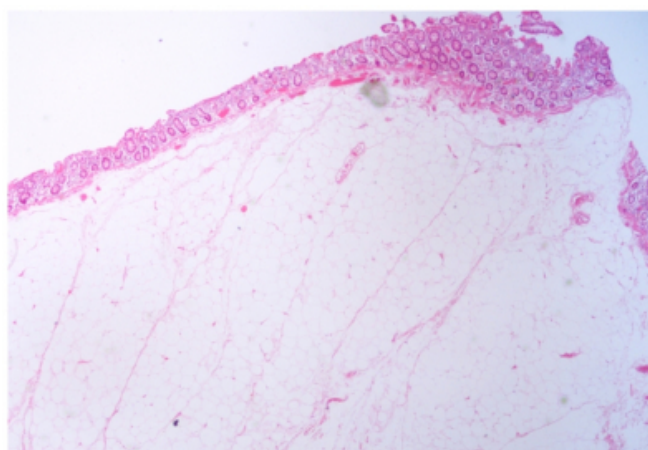
**Figure 4**

Tubulovillous adenoma with underlying lipoma



**Figure 5**

Lipoma



The background mucosa contained a hyperplastic polyp and another tubular adenoma (with low grade dysplasia). The lymph nodes examined were within normal limits and the resection margins showed no evidence of dysplasia or malignancy.

The patient fully recovered from the procedure and will undergo surveillance according to national guidelines.

## **DISCUSSION**

Lipomas are described as being well encapsulated masses of mature adipocytes that can vary in size.<sup>3,4</sup> Colonic lipomas are a relatively rare phenomenon, though they are thought to occur more frequently in women, with the most common site

being the right colon (specifically the caecum).<sup>1,3</sup> They are usually solitary and mainly arise in the submucosa. <sup>2,5</sup> Macroscopically and histologically they resemble their counterparts found elsewhere in the body. <sup>4</sup>

Lipomas of the colon can present with symptoms depending on their size.<sup>5,6</sup> They are subcategorised as giant lipomas if they are more than 40mm and are likely to be the most common benign tumours causing intussusception. <sup>1,6</sup> These lesions can cause a change in bowel habit which may lead to diagnostic difficulty as they can mimic the presentation of a possible malignancy. <sup>2</sup> Symptoms of bleeding can result if the lipoma enlarges and begins to ulcerate, again causing confusion. <sup>6</sup>

Alterations can occur in the overlying colonic mucosa such as: ulceration, necrosis, hyperplasia, atrophy and adenoma. <sup>3,6,7</sup> An adenoma of the colonic mucosa arises due to proliferation and dysplasia (which can be low or high grade) and can be further subcategorised as either tubular, villous or tubulovillous depending on the architecture. <sup>4</sup> Adenomas are neoplastic lesions that are a precursor to carcinoma as they follow the well documented adenoma carcinoma sequence. <sup>4</sup> Review of the literature identifies a weak link between the slow growing nature of a lipoma combined with the stress of the constant transit of faeces in the colon as a potential source of dysplastic change. <sup>3,7,9</sup>

Diagnosis upon endoscopic biopsy alone is fraught with difficulties. This case specifically highlights the discrepancy between the initial histology findings (a low grade villous adenoma) and those following the right hemicolectomy (a low grade tubulovillous adenoma with a submucosal lipoma). Current literature suggests that colonoscopy is still the most reliable means of diagnosis in uncomplicated cases.<sup>3,6</sup> Cases where the overlying mucosa may be ulcerated or atypical may prove more difficult in providing an accurate histological diagnosis, ultimately leading to discrepancy. <sup>6</sup>

EMR is associated with low morbidity and relatively high success rates in the removal of adenomas; it is the preferential means of removal rather than surgical

intervention.<sup>3,4,6</sup> This can however only be achieved if histologically there is no evidence of co-existent invasive malignancy. <sup>4</sup>

### **CONCLUSION**

A colonic lipoma can mimic malignancy given the age group and symptoms that the patient can present with. Removal of a small (<20mm) asymptomatic lipoma in most cases is unnecessary.<sup>2,3,6,8</sup> Surgical resection is required when the lesion is large, it is in an inaccessible site or where enlargement may go on to cause obstruction, a symptomatic patient, or the possibility of co-existent malignancy.<sup>2</sup>

With the preliminary finding of a large polypoid lesion at colonoscopy and subsequent biopsy results identifying a low grade villous adenoma, removal of the entire lesion for histological assessment was ultimately necessary. It was to ensure there was no invasive malignancy.

This was an interesting and unusual case of a submucosal lipoma with an overlying low grade tubulovillous adenoma found at the ileocaecal valve. Such cases have been rarely been seen and reported upon.

### **References**

1. Nallanathu G, Adler DG. Review Large Colonic Lipomas. *Gastroenterology & Hepatology* 2011; 7(7) 490-492.
2. Zhang X, Ouyang J, Kim Y. Large ulcerated cecal lipoma mimicking malignancy. *World Journal of Gastrointestinal Oncology* 2010; 2(7):304-306.
3. Yeom JO, Kim SY, Jang EC, Yu JY, Chang ED, Cho YS. Colonic lipoma covered by hyperplastic epithelium: Case report. *World Journal of Clinical Cases* 2013; 1(3):124-127.
4. Cotran RS, Kumar V, Collins T. *Robbins pathological basis of disease*, 6th Edition. 1999.
5. Zhang H, Cong JC, Chen CS, Qiao L, Liu EQ. Submucous colon lipoma: A case report and review of the literature. *World Journal of Gastroenterology* 2005; 11(20):3167-3169.
6. Jiang L, Jiang L, Li F, Ye H, Li N, Cheng N, Zhou Y. Giant submucosal lipoma located in the descending colon: A case report and review of the literature. *World Journal of Gastroenterology* 2007; 13(42): 5664- 5667.
7. Capra F, Zorcolo L, Scintu F, Mascia R, Casula G. Giant sigmoid lipoma covered by a villous adenoma. *International journal of Colorectal disease* 2007 22:563-564.
8. Lancet F, Alberti LE, Alberti-Flor J. Diminutive colon polyp co-existing with a large lipoma: An endoscopic 'rarity'. *Canadian Journal of Gastroenterology* 2004; 18 (3): 178.

**Author Information**

**Sabina Kaur Rait, MbChb (Hons)**

Specialist trainee, Wycombe Hospital

High Wycombe, United Kingdom

bina\_kaur@hotmail.co.uk

**Arnold Goede, MBChb, MS, FRCS (general surgery)**

Consultant surgeon, Wycombe Hospital

High Wycombe, United Kingdom

Arnold.Goede@buckshealthcare.nhs.uk

**Jaideep Singh Rait, Mbbs, Bsc**

Core Surgical Trainee, Torbay Hospital

South Devon, United Kingdom

**Narendra Shastri Mungalsingh, BM, FRCPath**

Consultant Histopathologist, Wycombe Hospital

High Wycombe, United Kingdom

Narendra.Mungalsingh@buckshealthcare.nhs.uk