

# Natal Sublingual Traumatic Ulceration (RIGA-FIDE Disease): Review And Case Report

R Shanbhog, B S Godhi, R Veena, M Dhakshayani, P Verma, N Agarwal

## Citation

R Shanbhog, B S Godhi, R Veena, M Dhakshayani, P Verma, N Agarwal. *Natal Sublingual Traumatic Ulceration (RIGA-FIDE Disease): Review And Case Report*. The Internet Journal of Pediatrics and Neonatology. 2013 Volume 16 Number 1.

## Abstract

If a tooth is found at the time of birth or too early, it leads to a plethora of reactions which are combined with a lot of misconceptions. The folklore and misconceptions surrounding natal and neonatal teeth vary in some cultures like Malaysian communities, a natal tooth is believed to herald good fortune; in others, its occurrence is considered bad omen. In China, Poland, India, and Africa, the affected children are considered to be monsters and bearers of misfortune. Natal teeth are just one of the variations observed in the newborn's oral cavity. Infants with prematurely erupted teeth must be carefully examined for further treatment planning, and parent counseling to bring about awareness is also equally important.

## INTRODUCTION

One of the major events in a baby's first year of life is the eruption of the first tooth which brings immense joy to the parents. It is associated with lots of emotions.<sup>1</sup> But when teeth are observed in oral cavity at birth or within first 30 days of life it becomes the interest, curiosity and concern of both clinician and parents because of various difficulties associated with it like pain on suckling, refusal to feed, ulceration on tongue, fear of dislodgement and aspiration and so forth. Several terms have been used to designate teeth that erupt before normal time, such as congenital teeth, fetal teeth, predeciduous teeth, precocious dentition (Mayhall and Bodenhoff), dentitia praecox and dens connatalis. Massler & Savara, considering time of eruption as a reference, defined early erupting teeth as natal teeth are those observable in the oral cavity at birth and neonatal teeth which are those that erupt during the first 30 days of life. 1, 2, 3, 4, 5

The purpose of this report is to present a case with natal teeth that caused sublingual traumatic ulceration (Riga-Fide disease) and to review the literature, epidemiology, etiology and the possible treatment.

## CASE REPORT

A one month 18 days old female baby accompanied by her mother reported with the chief complaint of early eruption of a tooth in the lower front region of mouth. The mother was also concerned about a traumatic ulcer formed on the ventral surface of the tongue. On history the mother revealed the presence of the tooth since birth in the baby's oral cavity.

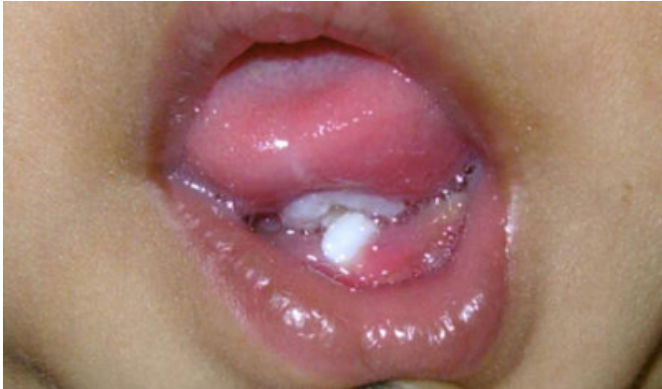The mother reported that the child exhibited pain during suckling and would not nurse properly. Past medical history and family history showed no significant finding.

Immunization status of the baby was found to be satisfactory. The baby also had received vitamin K injection after birth.

Intraoral examination revealed a tooth of incisor shape projecting 4-5 mm from the mandibular ridge in the left central incisor position (Figure 1). The tooth was chalky whitish in color and exhibited grade II mobility. The ventral surface of the tongue showed an ulceration of 10-11mm that extended from the anterior border of the tongue to the lingual frenum (Figure 2). On palpation the area elicited pain response from the patient. The ulcer was whitish pink in color with slightly raised margins with a central area of yellowish discoloration. Based on the history and clinical observation the diagnosis was made as natal teeth. The ulcer causing potential and the teeth which exhibited grade II mobility were planned for extraction.

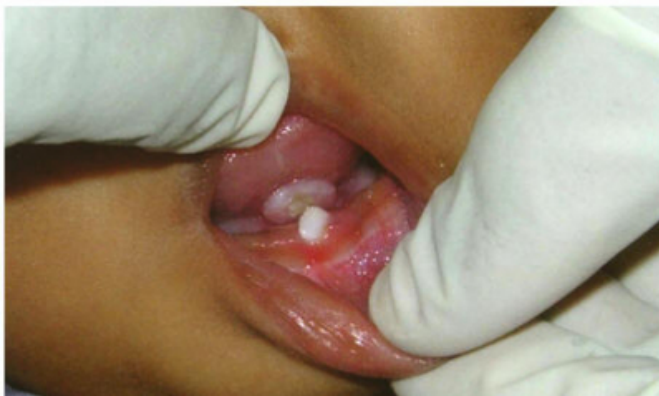**Figure: 1**

Natal teeth pre operative



**Figure 2**

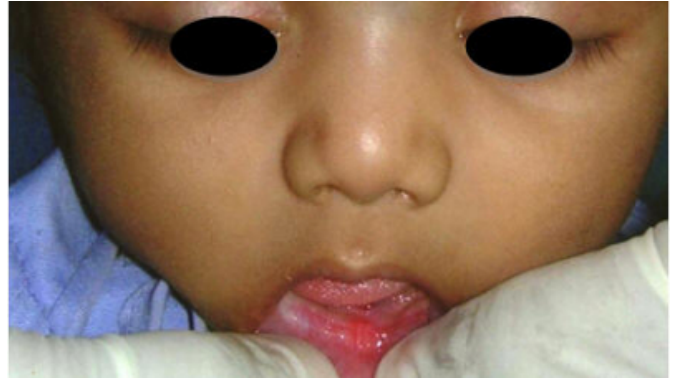Ulceration on the ventral surface of the tongue



Confirmation of vitamin K supplements and normal general physical health status of the baby was done. A pediatrician opinion regarding the infant general health was obtained. A consent from the parent was taken prior to extraction of the natal teeth. Then area was anesthetized with 2% lignocain hydrochloride topical local anesthetic gel and each tooth was gently extracted which the patient tolerated well. Pressure was applied with sterile wet cotton at the site to facilitate hemostasis (Figure 3). The extracted tooth had mesio-distal width of 3.5mm and overall length from crown to root of 8 mm (Figure 4). Mild local analgesic and anesthetic gel was prescribed for ulcer to aid in healing and to reduce discomfort during suckling. The patient was re-evaluated after 2 days and the recovery was found to be uneventful. The ventral surface of the tongue was re-evaluated after 15 days with complete healing of the ulcer with the baby having normal suckling.

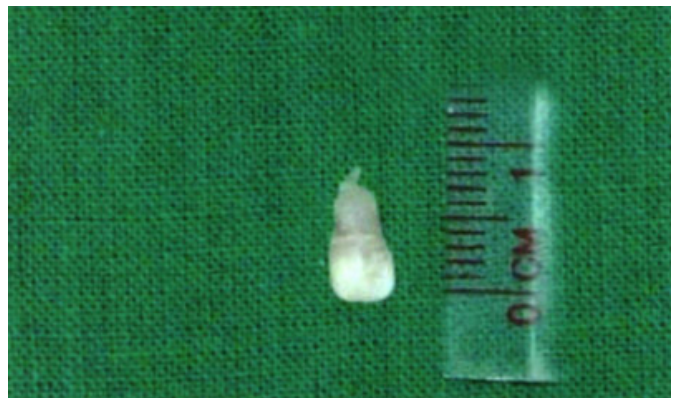
**Figure 3**

Post extraction site after achieving hemostasis



**Figure 4**

Neonatal tooth length from crown to root of 8 mm.



## DISCUSSION

Erupted teeth at or immediately after birth is a relatively isolated phenomenon, varying from 1:6000 to 1:800 cases, occurring in general with incidences of two or three teeth<sup>6</sup> (Table 1). With respect to gender there was not much difference found but Kate's reported 66% proportion for female against 31% males.<sup>5,7,8,9</sup> With respect to location the most common site being the mandibular region of central incisors (85%) usually bilateral, followed by maxillary incisors (11%), mandibular cuspids or molars (3%), and then maxillary cuspids or molars (1%).<sup>4</sup> Natal or neonatal cuspids are extremely rare.<sup>6</sup> Most commonly, these teeth are precociously erupted from the normal complement of primary teeth (90%-99%). Only 1% to 10% of natal and neonatal teeth are supernumerary.<sup>10, 11, 12</sup>

**Table 1**

Prevalence of Neonatal teeth

Author	Prevalence
Leung	1:3392
Yen	1:1442
Renmah	1:2325
Tya	1:1118

Exact etiology of natal and neonatal teeth is still unknown. However the most acceptable theory is based upon the result of a superficial localization of the dental follicles, probably related to a hereditary factor. 6, 10, 13 Bodenhoff and Gorlin have verified that 15% of children with natal and neonatal teeth had parents, siblings, or close relatives with a history of having presented with the same condition. 11A hereditary factor has been traced in 10 out of 24 cases of natal teeth studied by Massler and Savara (1950).

Endocrine disturbances are another possible cause. It is thought to be because of excessive secretion of the pituitary, thyroid or gonads. Jasmin and Clergeau-Guerithault reported that the eruption of natal and neonatal teeth could be dependent on osteoblastic activity within the area of the tooth germ. 14, 15 infection, 14 nutritional deficiency, 4, 14 febrile status, environmental factors like polychlorinated biphenyls (PCB) and dibenzofurans 16 seem to increase the incidence of natal teeth.

Natal teeth and neonatal teeth are frequently found associated with developmental abnormalities and recognized syndromes. These syndromes include Ellis-van Creveld (chondroectodermal dysplasia), pachyonychia congenita (Jadassohn-Lewandowsky), Hallerman-Streiff (oculo-mandibulo dyscephaly with hypotrichosis), Rubinstein-Taybi, steatocystoma multiplex, Pierre-Robin, cyclopia, Pallister-Hall, short rib-polydactyly type II, Wiedeman-Rautenstrauch (neonatal progeria), cleft lip and palate, Pfeiffer, ectodermal dysplasia, craniofacial dysostosis, multiple steacystoma, Sotos, adrenogenital, epidermolysis bullosa simplex, including vanderWoude and Walker-Warburg syndrome 4, 8, 17

Clinically, the natal teeth are small or of normal size, conical or of normal shape. They may reveal an immature appearance with enamel hypoplasia and small root

formation. Natal teeth may exhibit a brown-yellowish/whitish opaque color. They are attached to a pad of soft tissue above the alveolar ridge, occasionally covered by mucosa and as a result have an exaggerated mobility, with the risk of being swallowed or aspirated, in most of the cases. 6, 11 Bigeard et al. revealed that the dimensions of the crown of these teeth are smaller than those for the primary teeth under normal conditions.

Spoug and Feasby (1966) depending on maturity classified natal and neonatal tooth; 15 a mature natal or neonatal tooth is one which is nearly or fully developed and has relatively good prognosis for maintenance. The term immature natal or neonatal tooth on the other hand implies a tooth with incomplete or substandard structure; it also implies a poor prognosis.

The appearance of each natal tooth into the oral cavity can be classified into four categories as the teeth emerge into the oral cavity. 7, 15

- Shell-shaped crown poorly fixed to the alveolus by gingival tissue and absence of a root.
- Solid crown poorly fixed to the alveolus by gingival tissue and little or no root.
- Eruption of the incisal margin of the crown through the gingival tissues.
- Edema of gingival tissue with an un-erupted but palpable tooth.

Complications associated with natal and neonatal teeth

- Potential risk of the infant inhaling the tooth into his/her airway and lungs if the tooth becomes dislodged during nursing, due to its great mobility. Neonatal teeth often presents with hypoplastic enamel and under developed root that reasons to its mobility.
- Ulceration to ventral surface of tongue. Coldarllin first described this condition in 1857 in baby was found with general wasting leading to existas lethalis. Riga and Fede histologically described the lesion, which was then started to be called Riga-Fede disease 15, 25 sharp incisal edge of neonatal tooth causes constant trauma to ventral surface of tongue that results in ulceration this interferes with proper suckling and feeding that puts neonate at risk of nutritional deficiency. Curt gave a more appropriate and descriptive term called neonatal sublingual traumatic ulceration.
- Difficulty in feeding or refusal to feed due to pain. The work by Howkins (1932) and Boyd and Miles. 5 revealed histological aspect of natal teeth. Natal teeth under microscope showed a thin enamel layer, with varying degrees of mineralization, and/or hypoplastic to total absence of enamel in some regions. Friend et al.

demonstrated that the alteration in amelogenesis was detected due to premature exposure of the tooth to the oral cavity. 15

The usually increased mobility causes histological changes in the cervical dentin and cementum.<sup>10</sup> It has been further postulated that the mobility may cause degeneration of Hertwigs sheath, thus preventing root development and stabilization. 11, 15 The pulp cavity and the radicular canals are wider, although the pulp shows normal development.<sup>11</sup> Weil's zone and cell-rich zone are missing. 5 Absence of root formation, lack of cementum formation, large pulpal chamber, an irregular dentin formation was also observed. In the polarized light and micro-radiographic studies, these teeth showed enamel hypoplasia and dentinal disturbances including the formation of osteodentin and irregular dentin in the cervical portions and interglobular dentin in the coronal region. 17

#### Diagnosis and Treatment

The decision of maintaining or extracting these teeth in oral cavity depends on factors like, implantation and degree of mobility, inconvenience during suckling, interference with breast feeding, possibility of trauma, whether the tooth is a part of normal dentition or supernumerary. This can be decided by taking intraoral periapical radiograph of natal teeth. If the radiograph shows three different sets of teeth including natal teeth it is considered as supernumerary, if only two sets of teeth are visible then it will be part of primary dentition. To prevent indiscriminate extraction, clinical and radiographic findings are used to diagnose whether these teeth belong to normal dentition or supernumerary.

If the erupted tooth is a part of normal dentition maintenance is the first treatment option unless it is causing trauma. Teeth causing traumatic ulcer interfering with feeding highly mobile tooth with risk of aspiration are indicated for extraction. Prophylactic administration of vitamin K (0.5-1.0 mg, intra muscular) is advocated because of the risk of hemorrhage as the commensal flora of the intestine might not have been established until the child is 10 days old, and since vitamin K is essential for the production of prothrombin in the liver. If the tooth is a part of normal dentition with less mobility the traumatic ability of tooth can be solved by covering incisal portion of the teeth with smooth composite. But many of these teeth show evidence of hypomineralization, and there is limited surface of enamel for bonding of resin. These factors, combined with difficulty of access, adequate moisture control, and etching of enamel surface, mean that achieving adequate retention of the resin

could be questionable. Should the restoration fail, the composite resin could also be swallowed or inhaled. Both of these treatment regimes present practical difficulties considering the age of the children involved. Allwright advocated maintaining the neonatal tooth by smoothening of incisal edge with an abrasive instrument. In cases of mild-to-moderate irritation to the tongue, such treatment may suffice. If the ulcerated area is large and denuded, however, even the reduced incisal edge may still contact and traumatize the tongue during suckling to an extent enough to delay healing.

## CONCLUSION

Longitudinal and more divergent studies are also necessary to confirm the etiology and nature of natal teeth and to determine whether they are deciduous or supernumerary teeth. Pediatric dentists should make every effort to educate parents and the medical community on the preferred treatment for natal teeth. Periodic follow-up by a pediatric dentist to ensure preventive oral health care is very essential. Hence to avoid any complication, early diagnosis and adequate treatment should be of prime concern in the management of natal teeth.

## References

1. Barfiwala DR. Natal and neonatal teeth: A review of 50 cases. *J Indian Soc Pedo Prev Dent* 1996;14:21-3
2. Rusmah M. Natal and neonatal teeth: A clinical and histological study. *J Clin Pediatr Dent* 1991;15:251-3.
3. Chawla HS, Subba Reddy VV. A follow-up study of 25 cases of Natal/Neonatal teeth. *J Indian Soc Pedo Prev Dent* 1988;6:57-61.
4. Alvarez MP, Crespi PV, Shanske AL. Natal molars in Pfeiffer syndrome type 3: A case report. *J Clin Pediatr Dent* 1993;18:21-4
5. Anderson RA. Natal and neonatal teeth: Histologic investigation of two black females. *ASDC J Dent Child* 1982;49:300-3.
6. Goncalves FA, Birmani EG, Sugayai NN, Melo AM. Natal teeth: Review of literature and report of an unusual case. *Braz Dent J* 1998;9:53-6.
7. Singh S, Subba Reddy VV, Dhananjaya G, Patil R. Reactive fibrous hyperplasia associated with a natal tooth: A case report. *J Indian Soc Pedo Prev Dent* 2004;22:183-6.
8. Darwish S, Sastry RH, Ruprecht A. Natal teeth, bifid tongue and deaf mutism. *J Oral Med* 1987;42:49-53.
9. Sureshkumar R, McAulay AH. Natal neonatal teeth. *Arch Dis Child Fetal Neonatal* 2002;87:F227.
10. Available from: [www.newdao.com/natal-teeth-baby-born.html](http://www.newdao.com/natal-teeth-baby-born.html).
11. Delbem AC, Faraco Junior IM, Percinoto C, Delbem AC. Natal teeth: Case report. *J Clin Pediatr Dent* 1996;20:325-7.
12. El Khatib K, Abouchadi A, Nassih M, Rzin A, Jidal B, Danino A, et al. Natal teeth: Study of five cases. *Rev Stomatol Chir Maxillofac* 2005;106:325-7.
13. Portela MB, Damasceno L, Primo LG. Unusual case of multiple natal teeth. *J Clin Pediatr Dent* 2004;29:37-9.
14. McDonald RD, Avery DR, Dean JA. Dentistry for the

Child and Adolescent. 8 th ed. Missouri: Mosby; 2004.

15. Anegundi RT, Sudha P, Kaveri H, Sadanand K. Natal and neonatal teeth: A report of four cases. J Indian Soc Pedo Prev Dent 2002;20:86-92.

16. Alaluusua S, Kiviranta H, Leppäniemi A, Hiltunen P,

Lukinmaa PL, Lope L, et al . Natal and neonatal teeth in relation to environmental toxicants. Pediatr Res 2002;52:652-5.

17. Uzamis M, Olmez S, Ozturk H, Celik H. Clinical and ultrastructural study of natal and neonatal teeth. J Clin Pediatr Dent 1999;23:173-7.

**Author Information**

**Raghavendra Shanbhog, Dr, MDS Reader**

Department of Pedodontics and Preventive Dentistry, J.S.S Dental College & Hospital, A Constituent College of JSS University

Mysore, Karnataka, India

draghvu.kiddoc@gmail.com

**Brinda S Godhi, Dr, MDS, Lecturer**

Department of Pedodontics and Preventive Dentistry, J.S.S Dental College & Hospital, A Constituent College of JSS University

Mysore, Karnataka, India

**R Veena, Dr, MDS**

Private Practitioner

Mysore, Karnataka, India

**MR Dhakshayani, Dr, MDS, Professor**

Department of Prosthodontics, J.S.S Dental College & Hospital, A Constituent College of JSS University

**Priya Verma, Dr, M.D.S Reader**

Department of Pedodontics & Preventive Dentistry I.T.S

Muradnagar, Ghaziabad, (UP), India

**Nidhi Agarwal, Dr, MDS Professor**

Department of Pedodontics and Preventive Dentistry Career Postgraduate Institute.

Lucknow, India