

Trisomy 18 – A Case Report

K Barani, R Padmavathy

Citation

K Barani, R Padmavathy. *Trisomy 18 – A Case Report*. The Internet Journal of Pathology. 2013 Volume 15 Number 1.

Abstract

A 22 year old female came with complaints of 9 months amenorrhea. Investigations showed anomalies in the foetus which were incompatible with life. The foetus was induced. Karyotyping showed trisomy 18. We present this case, Edward syndrome, due to its rarity.

INTRODUCTION

Trisomy 18 (Edward syndrome, T18) was first described by Edwards et al in 1960[1]. It is the second most common trisomy in man[1,2]. The incidence is about 1 in 3000 live births. There is a slight female predominance[1]. It occurs due to non – disjunction during maternal or paternal germ cell development. It presents with characteristic external features along with life threatening abnormalities. Here, we present a case of Edward syndrome due to its rarity.

CASE HISTORY

A 22 year old female came with complaints of 9 months amenorrhea. She was married since one year. The marriage is of non – consanguineous type. Ultrasound examination of the foetus showed massive diaphragmatic hernia. Colour Doppler showed ventricular septal defect of the heart. The foetus was induced. Karyotyping was done which showed trisomy 18 [figure 4].

Pathologic findings: We received the foetus which was measuring about 40 cm in length [figure 1]. On dissection, most of the intestines were found in the left side of the thoracic cavity. A portion of the liver was also found in the thoracic cavity [figure 2]. Rent in the diaphragm was made out. Left lung was found to be hypoplastic. Insitu dissection of the heart showed ventricular septal defect [figure 3]. Thus, the pathological findings were found to be consistent with Edward syndrome.

Figure 1

Foetus which was measuring about 40 cm in length

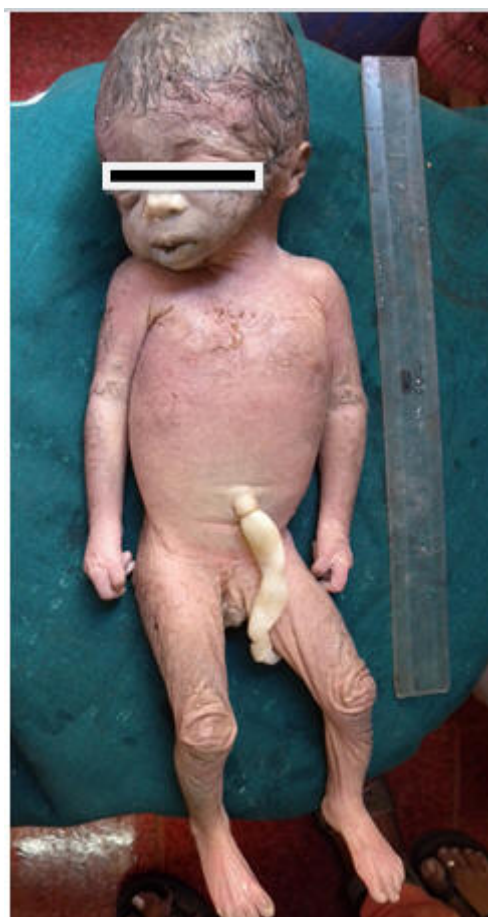

Figure 2

On dissection, most of the intestines were found in the left side of the thoracic cavity. A portion of the liver was also found in the thoracic cavity

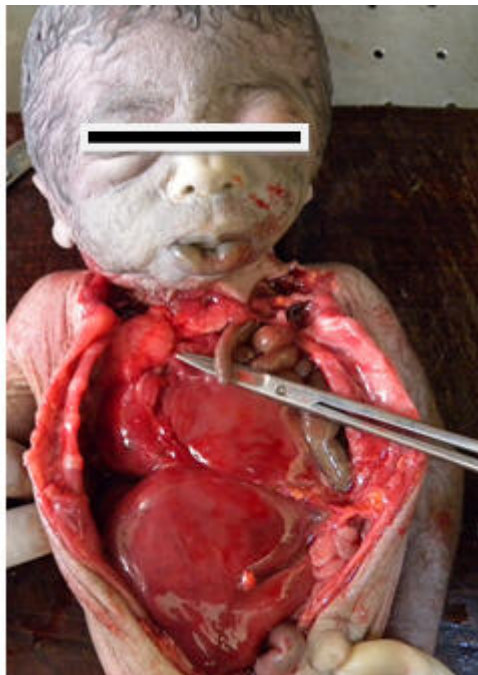


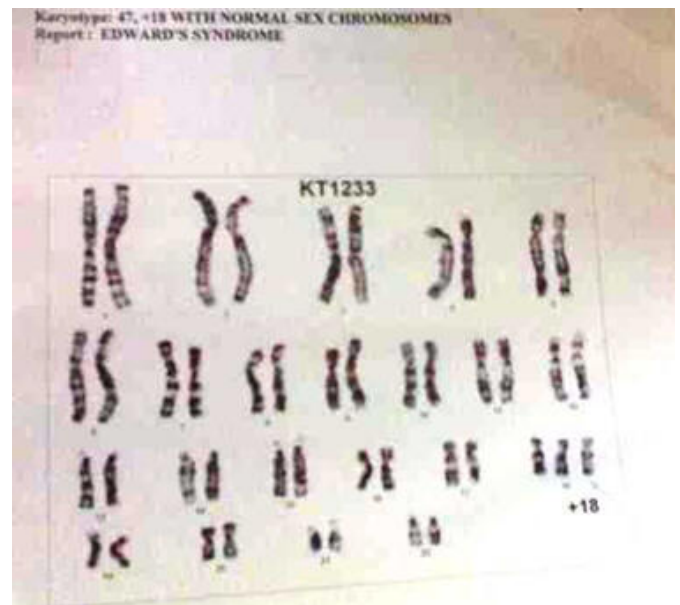
Figure 3

Insitu dissection of the heart showed ventricular septal defect

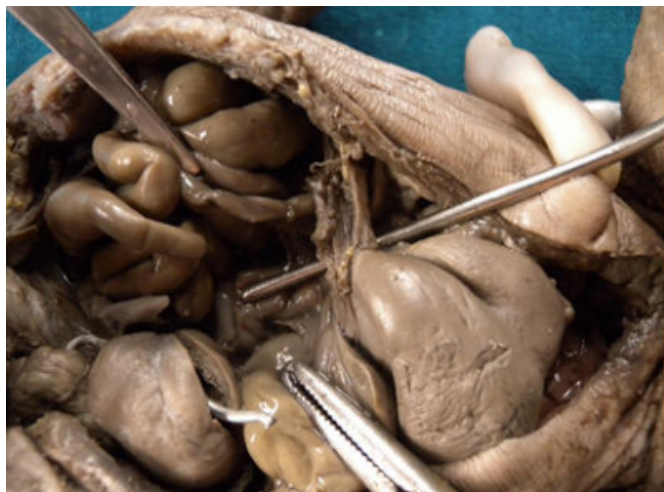

Figure 4

Karyotyping



DISCUSSION

Trisomy 18 is well known autosomal chromosomal disorder. It results in a well defined clinical syndrome. Though rare, it the second most common trisomy in man after trisomy 21. Most of the diseased die in embryonic or foetal life. Advanced maternal age was found to be a risk factor.

Trisomy 18 is a multiple malformation syndrome. It results in craniofacial, skeletal, cardiovascular, central nervous system and genitourinary malformations. Craniofacial malformations include microcephaly with prominent occiput, narrow bifrontal diameter, short palpebral fissures, low set malformed ears, cleft lip, cleft palate, narrow palatal arch, micrognathia [3,5,6].

Skeletal malformations include webbed neck, short sternum, widely spaced nipples, small pelvis, congenital dislocation of hip, limited hip abduction, phocomelia, rockerbottom feet, short dorsiflexed bigtoes, fixed flexion deformity of fingers, simple arch pattern of fingers and toes, hypoplasia of finger nails, single crease of the fingers, simian crease[3,5].

Central nervous system malformations include choroids plexus cysts, neural tube defects, abnormal intracranial anatomic characteristics, ventriculomegaly/hydrocephalus [2,3].

Cardiovascular system malformations include ventricular septal defect, atrial septal defect, patent ductus arteriosus, transposition of great vessels, fallot's tetralogy, anomalous coronary artery, coarctation, arteriosclerosis, dextrocardia,

aberrant subclavian artery, pulmonary stenosis, bicuspid aortic or/and pulmonic valves [3,4].

Gastrointestinal malformations include inguinal, umbilical and/or diaphragmatic hernia, diastasis recti, heterotopic pancreas, malrotation, meckel's diverticulum, tracheoesophageal fistula. Hepatoblastoma have been reported [3,5,6].

Genitourinary anomalies include cryptorchidism, double ureter, ectopic kidney, horseshoe kidney, hydronephrosis, polycystic kidney [3,5,6].

Other abnormalities include intrauterine growth retardation, umbilical cord abnormalities (cyst and single umbilical artery), hydrops and pleural effusion, cystic hygroma and amniotic fluid abnormalities (oligohydramnios and polyhydramnios) [2].

Our case showed two major anomalies, diaphragmatic hernia and ventricular septal defect, consistent with the diagnosis of Edward syndrome. The diagnosis was confirmed by karyotyping.

CONCLUSION

Fetuses with trisomy 18 can be identified by second

trimester ultrasonography up to 97% [7]. Our case, from a remote place, came to the hospital at thirty weeks with out an ultrasonography taken at the second trimester. Thus, importance of ultrasonography at second trimester must be stressed.

References

1. KK Naguib, Trisomy 18 in Kuwait, International Journal of Epidemiology 1999;28:711-716
2. Lami Yeo, MD, Detection of Trisomy 18 Through Abnormal Sonographic Features, J Ultrasound Med 2003; 22:581-590
3. Schreinemachers DM, Cross PK, Hook EB. Rates of trisomies 21, 18, 13 and other chromosome abnormalities in about 20 000 prenatal studies compared with estimated rates in live births. Hum Genet. 1982;61(4):318-24
4. D Moyano, Fetal echocardiography in trisomy 18, Arch Dis Child Fetal Neonatal Ed 2005;90:F520–F522
5. Moerman P, spectrum of clinical and autopsy findings in trisomy 18 syndrome, J Genet Hum. 1982 mar;30(1):17-38
6. Kinoshita M, Thirty-one autopsy cases of trisomy 18: clinical features and pathological findings, Pediatr Pathol. 1989;9(4):445-57
7. Gregory R. DeVore, MD, Second Trimester Ultrasonography May Identify 77 to 97% of Fetuses with Trisomy 18, J Ultrasound Med. 2000; 19:565–576

Author Information

K. Barani, MBBS, MD; Prof.

Stanley Medical College

Chennai, India

R. Padmavathy, MBBS, MD

Stanley Medical College

Chennai, India