

Hamartoma Of The Mammary Gland: An Entity Often Under-Recognized

M Rehan, A Shetty, P B. R

Citation

M Rehan, A Shetty, P B. R. *Hamartoma Of The Mammary Gland: An Entity Often Under-Recognized*. The Internet Journal of Surgery. 2013 Volume 30 Number 3.

Abstract

Hamartomas of the breast are uncommon benign lesions. Mammographic and sonographic features of this entity often mislead to a diagnosis of other lesions like fibroadenoma or fibrocystic disease. These lesions also lack cytological specificity, with FNA and core biopsy being non-conclusive most of the times. As rare cases of recurrences and malignancy arising in the epithelial elements of hamartomas have been reported, excision biopsy is now considered the treatment of choice. We present a case of hamartoma of the breast in a 35-year-old lady, which was inconclusive on FNAC and suspected to be a hamartoma/lipoma on ultrasonography. Examination of the excision biopsy specimen gave the final diagnosis of an adenolipomatous hamartoma. We present this case, not only because this is an uncommon benign lesion of the breast, but also to make the pathologists aware of this entity which otherwise histologically shows components of a normal breast and can often be under-looked in the absence of clinico-radiological correlation.

INTRODUCTION

Hamartoma of the breast is an uncommon, benign, slow-growing lesion found in all age groups after puberty. This pathological entity has a reported incidence of only 1.2% of benign lesions and 4-8% of benign breast tumors in women, in spite of breast lumps being encountered commonly in clinical practice. Because of the lack of cytological and architectural specificity, and diagnostic difficulties in which imaging findings are atypical, the correlation between clinical manifestation, imaging findings and histology is essential for the successful diagnosis of breast hamartoma [1].

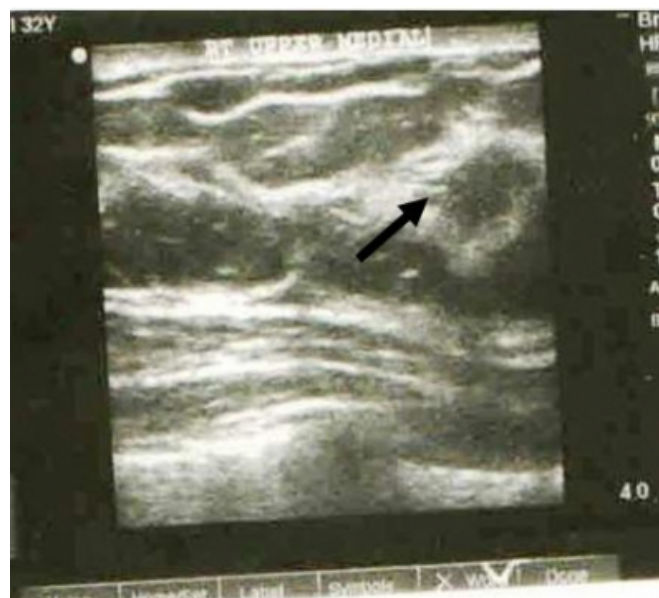CASE REPORT

A 35-year-old female presented with a lump in the right breast for two years, progressively enlarging in size during the last 3 months, not associated with any other symptoms of inflammation or nipple discharge. On examination, a mobile, oval, firm, painless mass measuring 3 x 2cm was palpable in the retromammary region of the right breast. Axillary nodes were not palpable. Suspecting it to be fibroadenoma, fine-needle aspiration (FNA) was done, which was inconclusive as only adipose tissue along with occasional benign ductal cells was aspirated. Ultrasonography showed a well circumscribed isoechoic mass, with no evidence of calcification and vascularity, easily compressed with a

transducer, with the skin and subcutaneous tissue being normal. (Fig. 1)

Figure 1

Ultrasonography showing an isoechoic mass with a capsule.

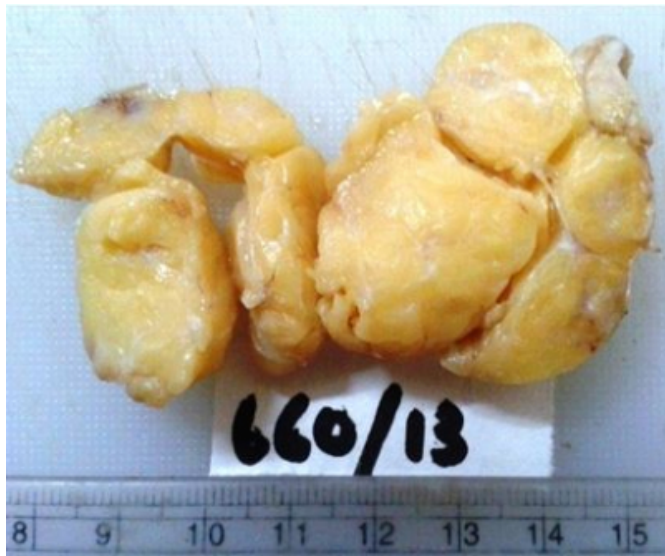

The rest of the breast showed fibrocystic change and the axillary region was unremarkable. A benign breast lesion, possibly hamartoma/lipoma, was suspected. Lumpectomy was done and the specimen was sent for histopathological examination.

On gross examination, the lump was lobulated, measuring 3.2 x 3cm in diameter; the cut section showed homogenous yellow and occasional grey-white fibrous areas. (Fig. 2)

Figure 2

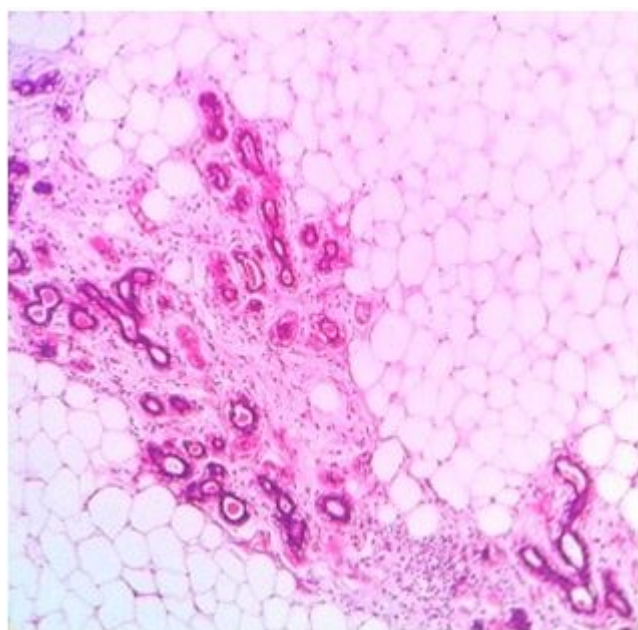
Cut section showing a lobulated yellow mass with thin, grey-white fibrous areas



Microscopy showed a benign, partially encapsulated lesion, composed predominantly of adipose tissue in lobules. The grey-white areas on gross examination showed entrapped benign breast lobules arranged haphazardly, with no proliferative change or atypia. Ducts were absent. (Fig. 3).

Figure 3

H&E stain (x10) showing a mixture of adipose tissue and lobules without atypia



A diagnosis of mammary hamartoma was given. The patient is on follow-up with no recurrence till date.

DISCUSSION

The breast hamartoma was initially identified by Arrigoni et al. in 1971, as a well circumscribed lesion comprising a mixture of benign mammary elements, fibrous tissue and fat, and is generally classified as rare, benign tumor.[2].

Hamartomas have a broad age distribution, having been reported in women in their 20s to 80s [3]

Hamartomas may not simply result from normal breast stromal and epithelial elements entrapped by proliferating adipocytes, but from mutated mesenchymal cells capable of differentiation to stroma and adipocytes. The genetic defect is mapped to the MAR, a major cluster region of chromosome 12, often involved in other benign tumors. [4]

On ultrasonography, hamartomas have a heterogeneous appearance. The variability and non-specific findings reflect the intrinsic differences in the lesion and inclusion of assorted entities in this diagnostic category [3]. Hamartomas are oval, well circumscribed, with varying internal echotexture, surrounded by an echogenic halo, without intratumoral calcification and absent retro-tumor acoustic phenomenon. [2]. Most of the above features were seen in the index case also. Hamartomas containing predominantly fatty tissue may mimic lipoma, fat necrosis and oil cysts, and those containing predominantly glandular tissue may mimic fibroadenoma. On mammography fibroadenomas have a homogenous glandular density, and cone compression view shows lack of intrinsic density in lipomas and oil cysts [5].

Although fine-needle aspiration cytology (FNAC) and core needle biopsy are accurate for diagnosing most breast lesions, in cases of adenolipomas both may be inconclusive or non-specific as they reveal normal breast tissue components, similar to our case [2].

Histologically, the tumor consists of mature fat and mammary parenchyma, mixed in varying proportions, delimited by a pseudocapsule of compressed breast tissue. Lobules and ducts in the lesion appear structurally normal with no proliferative activity [3].

Secondary tumours, in-situ and invasive ductal carcinomas arising in the epithelial component have been reported by Lee et al [6] and Tse et al. [7], stressing the relevance of surgical excision in all cases of suspected breast hamartomas/adenolipomas.

CONCLUSION

Hamartomas are rare benign breast lesions. A high degree of suspicion must be kept in mind for this entity by surgeons while encountering breast masses in routine clinical practice and by radiologists while imaging the same. FNA and core biopsy are inconclusive in these cases, unlike in other breast lesions. As reports of secondary tumors and malignancies arising from the elements of this lesion have been documented in the literature, excision must be the treatment of choice.

ACKNOWLEDGEMENT

We thank the staff, Department of Pathology and Radiology, for providing us the relevant information pertaining to the case.

CONFLICT OF INTEREST

All the authors declare that they have no conflict of interest.

References

1. Farrokh D, Hashemi J, Ansaripour E: Breast hamartoma – mammographic findings. *Iranian J Radiol*; 2011; 8: 258-260.
2. Chao TC, Chao HH, Chen MF: Sonographic features of breast hamartomas. *J Ultrasound Med*; 2007; 26: 447-52.
3. Rosen PP: Benign mesenchymal neoplasms. In: *Rosen's Breast Pathology*. Philadelphia, PA: Lippincott, Williams & Wilkins; 1997: 676-679.
4. Rohen C, Caselitz J, Stern C, Wanschura S, Schoenmakers E, Van de Ven WJ, Bartnitzke S, Bullerdiek J: A hamartoma of the breast with an aberration of 12q mapped to the MAR region by fluorescence in situ hybridization. *Cancer Genet Cytogenet*; 1995; 84: 82-84.
5. Pui M, Movson I: Fatty tissue breast lesions. *Clin Imaging*; 2003; 27: 150-155.
6. LeeL, Wylie J, Bourke A, Bastiaan De Boer W: Invasive ductal carcinoma arising in a breast hamartoma: two case reports and a review of the literature. *Clin Radiol*; 2003; 58: 80-86.
7. Tse GM, Law BK, Pang LM, Cheung HS: Ductal carcinoma in situ arising in mammary hamartoma. *J Clinical Pathol*; 2002; 55: 541-542.

Author Information

Mudasser Rehan, MBBS, MS, MRCS(Edin), F.MAS

Department of Surgery, Sapthagiri Institute of Medical Sciences and Research Centre

Bangalore

rehan_m1978@rediffmail.com

Archana Shetty, MBBS, MD

Department of Pathology Sapthagiri Institute of Medical Sciences and Research Centre

Bangalore

archanacshetty@yahoo.com

Prakash B. R, MBBS, MS, FICS

Department of Surgery, Sapthagiri Institute of Medical Sciences and Research Centre

Bangalore