

Urological Transabdominopelvic Ultrasound Findings In Patients With Prostatic Diseases

E Ogwuche, M Hameed, E Animashaun

Citation

E Ogwuche, M Hameed, E Animashaun. *Urological Transabdominopelvic Ultrasound Findings In Patients With Prostatic Diseases*. The Internet Journal of Urology. 2013 Volume 11 Number 2.

Abstract

Ultrasonography is the first line imaging investigation in most patients with prostatic diseases in our environment. More so because of the non- ionizing nature, cheap, availability and ease of performance of the modality. This study aims to document urological transabdominopelvic ultrasound findings in patients who presented with prostatic diseases in a private urodiagnostic centre in Makurdi, north central Nigeria.

A total of 126 adult patients who had transabdominal ultrasonography to evaluate prostatic diseases were studied prospectively between May 2010 and April 2011. The mean age of the patients was 65 years. 77(61.1%) of the patients had a clinical diagnosis of BPH, 48(38.1%) and 1(0.8%) had diagnosis of cancer and chronic prostatitis respectively. Cancer of the prostate was more common among the elderly (65 years), BPH among the middle age (45-65years) while prostatitis is common among those below 45 years. Regular capsular outline was more common in patients with BPH as compared with cancer of the prostate (73 % vs 11 %). Incidental findings included solitary urinary bladder calculus 9(7.1%), multiple urinary bladder calculi 1(0.8%), renal calculus 1(0.8%) and renal cyst 4(3.2%) respectively. Bilateral hydronephrosis as a consequence of prostatic disease was noted among 11 patients (8.7%). Of these, 4 patients had BPH while 7 had Cancer of the prostate. The array of findings in this study underscores the clinical utility of ultrasonography in the management of patient with prostatic disease.

INTRODUCTION

The prostate gland continues to generate clinical attention in view of the fact that it is commonly involved in benign and malignant neoplasms as well as infections.

The prostate gland is wedged between the bladder neck superiorly and the urogenital diaphragm inferiorly with the prostatic urethra passing through it. Anteriorly it is related to the pubic symphysis and posteriorly to the rectum.

This intimate relationship becomes very important when the organ is diseased leading to backpressure changes in the prostatic urethra, bladder, ureters and kidneys. Some of these pathological changes are detectable on ultrasonography. Certain findings on ultrasonography may however be incidental¹

We set out to evaluate the ultrasound findings in patients presenting with prostatic diseases.

Ultrasound is a non invasive, radiation free, cheap and readily available investigation modality¹ though the findings are operator dependent and its application and interpretation requires some level of training.

OBJECTIVE

To evaluate the frequency of urological abnormalities in urinary tract ultrasonography in patients with prostatic diseases.

METHODS

All patients presenting at the urodiagnostics specialist imaging centre, Makurdi, Benue state, Nigeria with clinical diagnosis of BPH, Ca prostate or prostatitis from May 2010 – April 2011 were evaluated sonologically with a portable mindray 1100 ultrasound machine fitted with 3 – 5MHz multifrequency curvilinear transabdominal transducer and the findings were tabulated and analyzed using the SPSS software.

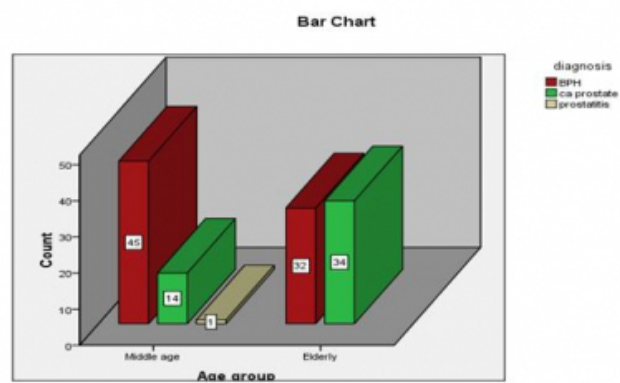
RESULTS

A total of 126 patients were involved in the study with an age range of 47 – 80yrs with a mean of 65yrs.

Seventy seven (61.1%) patients had clinical diagnosis of BPH while 48 (38.1%) and 1 patient (0.8%) had diagnosis of cancer of the prostate and chronic prostatitis respectively. Fig 1 shows that BPH is the most prevalent diagnosis in the

middle age group (45- 65years) while cancer of the prostate is the most prevent diagnosis in the elderly.

Figure 1
Diagnosis Vs age of patients



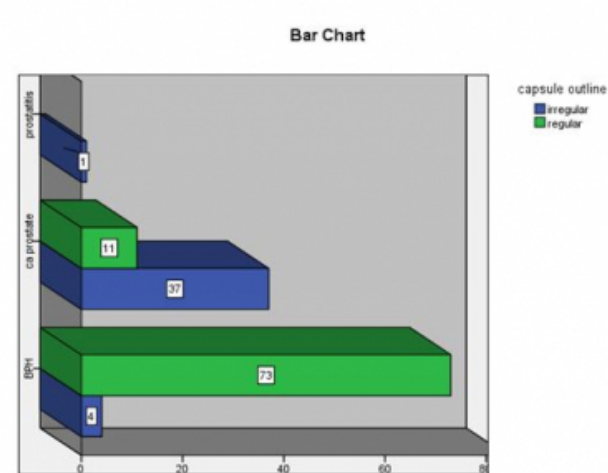
The prostate volume ranged from 27mls to 777mls with a mean volume of 99.2mls.

73 patients (96%) with BPH had regular capsular outline while 4 had irregular capsular outline

37 (77%) of patients with cancer of the prostate had irregular capsular outline while eleven patients the capsular outline appeared regular (Fig II).

Irregularity of the capsular outline is therefore more common in cancer of the prostate compared to BPH.

Figure 2
Capsular outline in different prostatic diseases



About half (54%) of the patients with a diagnosis of cancer had nodules on ultrasonography out of which 65% were hypoechoic while 35% were hyperechoic. Multiple nodules were noted in 3 (11%) of patients. All multiple

nodules were hypoechoic in nature.

The patient with chronic prostatitis had an irregular capsular outline.

The bladder wall thickness ranged from 4 – 12mm with a mean of 7.76mm.

No bladder mass suggestive of tumour was noted in the studied patient population.

Four patients (3.2%) had bladder diverticula which were noted in the bladder neck.

Solitary urinary bladder calculus was noted in Nine (7.1%) of the patients while one patient (0.8%) had multiple stones.

Submucosal halo was noted in two (1.6%) of patients.

A kidney stone was noted in one patient (0.8%) while 4 patients (3.2%) had renal cysts. No solid renal masses noted in any of the patients studied.

Hydronephrosis was noted in 4 patients with BPH while seven patients with cancer of the prostate had hydronephrosis making up a total of 8.7% of patients with Hydronephrosis. (Table I)

Table 1
prevalence of hydronephrosis in studied patient population

		Frequency	Percent	Valid Percent	Cumulative Percent
Valid	nil	115	91.3	91.3	91.3
	present	11	8.7	8.7	100.0
Total		126	100.0	100.0	

DISCUSSION

The general objectives for transabdominal ultrasonography in patients with prostatic disease are to establish baseline for subsequent management and also to detect abnormalities in the urinary bladder, ureters and kidneys that may influence management of the patients’ conditions.

This study revealed that the mean age of the patients in this Study is 65 years. This finding supports previous works 2, 3.

In this study 65% of patients with cancer had hypoechoic nodules corroborating the series by Yeboah2 in which 71% of cancers were hypoechoic, however 35% of the nodules in this series are hyperechoic as opposed to the 1% in his study. No isoechoic nodules were noted in this study.

Prostatic Carcinoma arise in 80% of cases in the peripheral zone. They are primarily hypoechoic but with increasing tumour size echogenicity becomes varied due to tumour infiltration 4

However, a transrectal transducer defines the zonal anatomy and hence has a better sensitivity and specificity than a transabdominal transducer which was used in our study.

The incidence of bladder stone in our series is 6.3% this is comparable to 5% in Al-Durazi's series but Rafique¹ had found stones in 13.6% of patients in his series of 250 patients.

The incidence of bladder diverticulum is 3.2% however Quirinia A et al⁶ however had an incidence of 51% on cystography & 30% on urography. This is a subject for further study as our series only comprise of ultrasonic studies.

Bladder wall thickness has been noted to correlate with the extent of bladder outlet obstruction from prostatism in a series by Franco G et al⁷. An area of future study could be to correlate the bladder wall thickness on ultrasound with International Prostate Symptom Score of patients.

The incidence of kidney stones is 0.8% (1) correlating with one stone in a series of 128 patients with prostatism by Gerald de Lacey et al⁸ while Al-Durazi H m et al⁵ in Bahrain found 9 cases of renal stones in a series of 100 patients. The changes in incidence of stones may be related to weather condition which is a known factor in the development of urolithiasis.

The incidence of renal cyst in our study is 3.2% compared with 9% in Al-Durazi's series while in the Gerald de Lacey⁸ series, they had 21%⁵, Koch et al had an incidence of 11.7% in a series of 556 patients with BPH⁹.

Bilateral hydronephrosis was present in 8.7% of our studied patient population but Rafique had noted hydronephrosis in 3% of patients in his series¹.

CONCLUSION

Transabdominal ultrasound assessment is imperative in patients with prostatic disease. This is not only because of the effects of the prostatic disease on the upper and the lower tracts but also of the fact that some of these patients may harbour clinical conditions that may influence the management of the patients' conditions.

References

1. Rafique M. Value of routine renal and abdominal ultrasonography in patients undergoing prostatectomy. *Int Urol Nephrol*. 2006; 38(1):153-6.
2. Yeboah EO. The prostate gland in: Badoe E. A, Archampong EQ Da Rocha – Afodu J.I (Eds). Principles and practice of surgery including pathology in the tropics. 3rd edition. Ghana Publishing Corporation. 2000; 850 – 867.
3. Barry M.J. Epidemiology of & Natural history of BPH. *Urol clinic North Am*. 1990; 17; 495 – 497.
4. Fred T. Lee, Jr. and John R. Thornbury. The Urinary Tract in: Paul and Juhl's Essentials of Radiologic Imaging 7th edition (September 15, 1998): by John H. Juhl (Editor), Andrew B. Crummy (Editor), Janet E. Kuhlman (Editor), Lester W. Paul (Editor) By Lippincott Williams & Wilkins Publishers
5. Al-Durazi MH, Al-Helo HA, Al-Reefi SM, Al-Sanaa SM, Abdulwahab WA. Routine ultrasound in acute retention of urine. *Saudi Med J*. 2003 Apr; 24(4):373-5.
6. Quirinia A, Hoffmann AL. Bladder diverticula in patients with prostatism. *Int Urol Nephrol*. 1993; 25(3):243-7.
7. Franco G, De Nunzio C, Leonardo C, Tubaro A, Ciccariello M, De Dominicis C, Miano L, Laurenti C. Ultrasound assessment of intravesical prostatic protrusion and detrusor wall thickness--new standards for noninvasive bladder outlet obstruction diagnosis? *J Urol*. 2010 Jun;183(6):2270-4. doi:10.1016/j.juro.2010.02.019. Epub 2010 Apr 18.
8. Gerald de lacey, Stephen Johnson, David Mee Prostatism: how useful is routine imaging of the urinary tract? *BMJ* volume 296 2 April 1988 967-969
9. Koch WF, Ezz el Din K, de Wildt MJ, Debruyne FM, de la Rosette JJ. The outcome of renal ultrasound in the assessment of 556 consecutive patients with benign prostatic hyperplasia. *J Urol* 1996; 155:186-9.

Author Information

E. I. Ogwuche, FWACS

Dept. of Surgery, BSUTH, Makurdi/Urodiagnostic Specialist Centre

Makurdi

owofuichechukwuehi@yahoo.com

Mohammed Hameed, FMCR

Dept. of Radiology, BSUTH

Makurdi

E. A. Animashaun, MBBS

Dept of surgery, FMC

Makurdi