

General Anesthesia In A Patient With Complete Atrioventricular Block For Permanent Pacemaker Implantation Without A Temporary Pacing

H Hepađuplar, H Çatalyürek, S Bayar, Z Elar, O Oto

Citation

H Hepađuplar, H Çatalyürek, S Bayar, Z Elar, O Oto. *General Anesthesia In A Patient With Complete Atrioventricular Block For Permanent Pacemaker Implantation Without A Temporary Pacing*. The Internet Journal of Anesthesiology. 2002 Volume 7 Number 2.

Abstract

Complete atrioventricular block was diagnosed in a 43-year-old patient and treatment with permanent pacemaker was planned. The patient had a history of cardiac surgery for the replacement of mitral and tricuspid valves. Transvenous cardiac pacing was impossible because he had a tricuspid valve prosthesis. Implantation of an epicardial pacemaker was performed using anterior thoracic approach under general anesthesia while the transcutaneous cardiac pacing was ready to use. We present the anesthetic management of the case and review the literature.

Presented in part at the XXXIII. Turkish Anesthesiology and Reanimation Congress in Mersin, TURKEY, Oct 27-31, 1999.

INTRODUCTION

Complete atrioventricular block (CAVB) is one of the serious cardiac conduction abnormalities which necessitates pacemaker implantation. In adult patients, implantation of permanent pacemaker is usually performed transvenously under local anesthesia. If the procedure is planned under general anesthesia, a temporary pacing is used as a bridge to permanent pacing for stabilizing the patient's hemodynamics_{1,2}.

We report an adult case with CAVB who underwent surgery for the implantation of an epicardial permanent pacemaker under general anesthesia while the transcutaneous cardiac pacing was readily available.

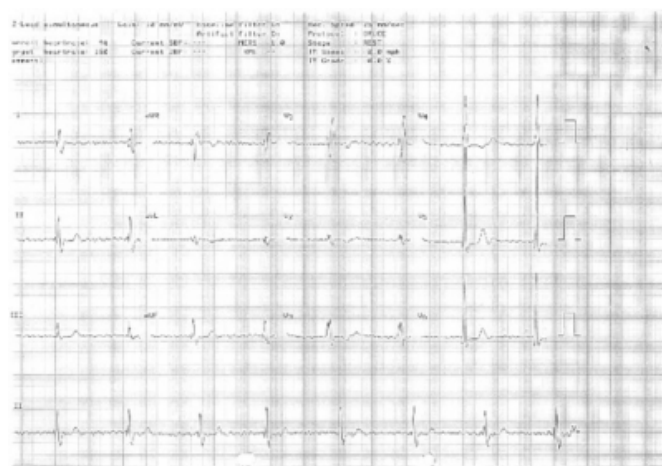
CASE

CAVB (46 beat per min, [bpm]) with an atrial fibrillation was diagnosed in a 43-year-old male patient (ASA IV, 60 kg) during his routine cardiac follow-up. He had a history of cardiac surgery for the replacement of mitral and tricuspid valves nine months ago. Postoperative echocardiographic investigation of the patient had revealed normal functioning of mitral mechanical valve with left ventricular systolic dysfunction and 25% ejection fraction.

The patient was taking digoxin since the early postoperative period. His serum digoxin level ($1,0 \text{ ng.ml}^{-1}$), and serum Na^+ and K^+ levels were in the normal ranges. After withdrawal of digoxin, CAVB (46 bpm) with atrial fibrillation persisted within a follow-up period of two weeks (Fig. 1).

Figure 1

Figure 1: Preoperative electrocardiographic recordings of the patient demonstrating complete atrioventricular block with atrial fibrillation (12 lead simultaneous ECG, Gain; 10 mm/mV, Speed; 25 mm/sec).



Although he didn't have any signs yet, the patient was at risk for congestive heart failure, and pacemaker implantation was planned. Placement of permanent epicardial pacing instead of transvenous ventricular pacing was preferred because the

patient had a tricuspid valve prosthesis.

While the intravenous access was secured with two large cannulas in the operating room, standard monitoring of vital signs including heart rate, blood pressure (non-invasive) and peripheral arterial saturation (Viridia, CMS, Hewlett Packard, USA) was applied. Drugs for cardiopulmonary resuscitation were prepared and the external transcutaneous pacemaker (Hellige, SCP 922, PPG Hellige GMBH, Freiburg, Germany) was ready to use.

The patient's heart rate was around 42 bpm on arrival to the operating room. We administered intravenous atropine 20 $\mu\text{g.kg}^{-1}$ and couldn't see any chronotropic response. Anesthesia was induced smoothly with incremental doses of fentanyl up to a total of 3 $\mu\text{g.kg}^{-1}$ and thiopental 5 mg.kg^{-1} in fractional doses. Rocuronium 0.9 mg.kg^{-1} was administered to facilitate tracheal intubation. Capnography was added to routine monitoring after tracheal intubation. The lungs were ventilated mechanically with 50% oxygen in air to maintain end-tidal CO_2 between 35-40 mmHg. We maintained anesthesia with midazolam infusion 40 $\mu\text{g.kg}^{-1}.\text{h}^{-1}$. In the course of anesthesia, the surgical team was alert in case the use of external transcutaneous pacemaker would be necessary.

After left limited anterior thoracotomy and detachment of pericardial adhesions, unipolar epicardial electrode was screwed into the wall of the right ventricle and secured with polypropylene stitches. Then, the pacemaker battery was placed in the rectus muscle. Pacing mode of the pacemaker was adjusted to fixed-rate and the frequency of stimulation was set at 70 bpm. Epicardial pacing was active 35 minutes after the induction of anesthesia.

The course of general anesthesia was stable without any significant hemodynamic instability. Although systolic and diastolic arterial pressures were decreased by the induction of anesthesia, transient asystole (> 4 sec) or severe hemodynamic depression (systolic arterial pressure < 90 mm Hg and mean arterial pressure < 60 mmHg) weren't observed. Intraoperative hemodynamic variables are displayed in Table 1.

Figure 2

Table 1: Heart rate (HR), and systolic (SAP) and diastolic arterial pressure (DAP) of the patient intraoperatively, P indicates pacemaker rate.

	Pre-induction	Post-induction	Maintenance		Post-extubation.
			Maximal	Minimal	
HR (bpm)	42	42	43	42	70(P)
SAP (mmHg)	171	144	144	103	152

At the end of the surgery, the trachea was extubated and the patient was transported to the cardiothoracic care unit. The anesthetic recovery was uneventful. The pacing mode was readjusted postoperatively.

DISCUSSION

General anesthesia for implantation of a permanent pacemaker without an active temporary pacing is presented in a cardiac patient. We found few reports related with general anesthesia in a patient with CAVB in the Medline data over the last 20 years.

Structural heart disease was considered as the cause of the cardiac conduction disturbance. Contributory effects of the drug therapy was ruled out by determination of the serum digoxin level and persistence of it after withdrawal.

Different anesthetic techniques are described for pacemaker implantation in the literature^{1, 2, 3,4}. Pacemaker implantation is usually performed transvenously under local anesthesia with sedation in usual situations^{1, 2}. Permanent transvenous cardiac pacing was impossible in our patient because of his previous tricuspid valve surgery. Both the ventricular lead and the tricuspid valve prosthesis could have been damaged by this attempt. If transvenous cardiac pacing would be possible, the procedure would have been performed under local anesthesia. Consequently, placement of a permanent epicardial pacing by anterior thoracotomy approach was planned.

Although epicardial electrode insertion to the ventricle via subxiphoid approach is possible under local anesthesia⁵, heavy sedation is required for tunneling of lead to an abdominal generator site³. Excessive use of sedatives and opioids may cause hypoxia¹ and partial loss of protective reflexes³ during the procedure. On the other hand, administration of local anaesthetic agents during local or regional anesthesia may possess potential risks, that is, cardiac conduction system could be depressed by local anaesthetics. Kosowsky et al⁶ reported transient asystole (>

4 sec) after subcutaneous local anaesthetic administration during permanent pacemaker implantation. Regional technique using a combination of a cervical plexus block and blocks of the second, third and fourth intercostal nerves could be adequate for transvenous pacemaker implantation, but not for placement of a battery in an abdominal pouch⁴. General anesthesia is commonly managed for transthoracic implantation of epicardial electrodes while temporary pacing is active¹. We managed general anesthesia in the current patient while the non-invasive transcutaneous cardiac pacing was ready to use⁷.

The necessity of temporary pacing during general anesthesia is discussed in patients having different cardiac conduction defects in the literature. In 1975, Venkataraman et al⁸ reported that asymptomatic patients with right BBB and left anterior hemiblock didn't require prophylactic pacemaker insertion. In another report, Gauss et al⁹ stated that routine prophylactic insertion of a temporary pacemaker in patients with chronic bifascicular block or left bundle branch block should be reevaluated. In 1957, Vandam and McLemore¹⁰ notified episodes of cardiac arrest and respiratory failure in patients with third degree atrioventricular block undergoing noncardiac surgery.

High grade atrioventricular block is one of the major clinical predictors of increased perioperative cardiovascular risk according to the ACC/AHA guideline update for perioperative cardiovascular evaluation for noncardiac surgery¹¹; and temporary cardiac pacing is recommended for patients with CAVB undergoing surgery^{1,2}. As mentioned previously, temporary transvenous cardiac pacing was impossible in our patient and subsequently general anesthesia was managed while the external transcutaneous pacemaker was ready to use in case it was needed. We couldn't find any data related with tricuspid valve replacement surgery in which temporary transvenous pacing couldn't be performed in a similar case. Transesophageal ventricular pacing¹² would have been another choice, however, it was not available in our institution.

The recommendation of temporary pacing is different in pediatric patients. Linton and Human¹³ reported that perioperative prophylactic cardiac pacing wasn't necessary in children with asymptomatic congenital heart block but was mandatory in patients with acquired complete heart block. According to Bennie et al¹⁴, there is no benefit in routine preoperative temporary pacing in children with third degree heart block undergoing permanent pacemaker

placement.

CAVB didn't progress toward a transient asystole or standstill requiring transcutaneous pacing in the current patient and this result might partly be explained by the chronic form of the disturbance. Most of the reported cases requiring cardiopulmonary resuscitation were those in which cardiac conduction abnormalities were acutely advanced to CAVB during general anesthesia^{12,15}. Additionally, the anesthetics that we used neither showed any effect on ventricular rhythm nor caused any ventricular irritability. Tsuda et al¹⁶ reported that thiopental was useful for induction of anesthesia in a patient with alcoholic heart disease and transient complete heart block. The reason why we didn't use nitrous oxide during the maintenance was based upon the report regarding the malfunction of pacemaker during nitrous oxide anaesthesia by Aboelmagd¹⁷. Pacing mode of the pacemaker was adjusted to fixed-rate intraoperatively.

In summary; general anesthesia is reported for implantation of a permanent epicardial pacemaker in a patient with chronic CAVB and synthetic tricuspid valve without temporary pacing. We didn't observe any severe hemodynamic depression or block progression to cardiac asystole requiring urgent cardiac pacing or cardiopulmonary resuscitation. In spite of this uneventful case, caution should be paid to the use of temporary pacemaker in patients with CAVB while managing general anesthesia.

CORRESPONDENCE TO

Dr. Hasan HEPAGUSLAR 1463 Sok., No:22 / 2, Alsancak-Izmir, TURKEY, 35220. Phone No: 00 90 232 4225659 Fax No: 00 90 232 4634971 E-mail : hasan@deu.edu.tr

References

1. YAO FSF. Pacemaker. In: Yao FSF, ed. Yao and Artusio's Anesthesiology. Problem-oriented patient management. Philadelphia: Lippincott-Raven Publishers, 1999; 258-275.
2. ATLEE JL. Cardiac pacing and electroversion. In: Kaplan JA, ed. Cardiac Anesthesia. Philadelphia: WB Saunders Company, 1999; 959-990.
3. CRANEY JM, GORMAN LN. Conscious sedation and implantable devices. Safe and effective sedation during pacemaker and implantable cardioverter defibrillator placement. Critical Care Nursing Clinics of North America; 9: 325-334, 1997.
4. RAZA SM, VASIREDDY AR, CANDIDO KD, WINNIE AP, MASTERS RW. A complete regional anesthesia technique for cardiac pacemaker insertion. Journal of Cardiothoracic and Vascular Anesthesia; 5: 54-56, 1991.
5. STEWART S, COHEN J, MURPHY G. Sutureless epicardial pacemaker lead: a satisfactory preliminary experience. Chest; 67: 564-567, 1975.

6. KOSOWSKY BD, MUFTI SI, GREWAL GS et al. Effect of local anesthesia on ventricular escape intervals during permanent pacemaker implantation in patients with complete heart block. *American Journal of Cardiology*; 51: 101-104, 1983.
7. GAUSS A, HUBNER C, MEIERHENRICH R, ROHM HJ, GEORGIEFF M, SCHUTZ W. Perioperative transcutaneous pacemaker in patients with chronic bifascicular block or left bundle branch block and additional first-degree atrioventricular block. *Acta Anaesthesiologica Scandinavica*; 43: 731-736, 1999.
8. VENKATARAMAN K, MADIAS JE, HOOD WB. Indications for prophylactic preoperative insertion of pacemakers in patients with right bundle branch block and left anterior hemiblock. *Chest*; 68: 501-506, 1975.
9. GAUSS A, HUBNER C, RADERMACHER P, GEORGIEFF M, SCHUTZ W. Perioperative risk of bradyarrhythmias in patients with asymptomatic chronic bifascicular block or left bundle branch block. *Anesthesiology*; 88: 679-687, 1998.
10. VANDAM LD, McLEMORE GA. Circulatory arrest in patients with complete heart block during anesthesia and surgery. *Annals of Internal Medicine*; 47: 518-532, 1957.
11. EAGLE KA, BERGER PB, CALKINS H et al. ACC/AHA guideline update for perioperative cardiovascular evaluation for noncardiac surgery: executive summary: areport of the American College of Cardiology/American Heart Association Task Force on Practice Guidelines (Committee to Update the 1996 Guidelines on Perioperative Cardiovascular Evaluation for Noncardiac Surgery. *Circulation*; 105: 1257-1267, 2002.
12. MAMIYA K, AONO J, MANABE M. Complete atrioventricular block during anesthesia. *Canadian Journal of Anaesthesia*; 46: 265-267, 1999.
13. LINTON DM, HUMAN DG. Peri-operative management and administration of anesthesia in children with congenital complete heart block. A case report and review. *South African Medical Journal*; 66: 875-876, 1984.
14. BENNIE RE, DIERDORF SF, HUBBARD JE. Perioperative management of children with third degree heart block undergoing pacemaker placement: a ten year review. *Paediatric Anaesthesia*; 7: 301-304, 1997.
15. MARUYAMA K, AGATA H, ONO K, HIROKI K, FUJIHARA T. Slow induction with sevoflurane was associated with complete atrioventricular block in a child with hypertension, renal dysfunction, and impaired cardiac conduction. *Paediatric Anaesthesia*; 8: 73-78, 1998.
16. TSUDA N, HIROSE M, ASHIDA H, TOJO H, MIZOBE T, TANAKA Y. Anesthesia for a patient with alcoholic heart disease and transient complete heart block. *Masui*; 50: 1126-1128, 2001.
17. ABOELMAGD E. Anesthetic management of the patient with a pacemaker. *Middle East Journal of Anesthesiology*; 15: 13-29, 1999.

Author Information

H. Hepađuplar

Assistant Professor, Department of Anesthesiology, Dokuz Eylül University

H. Çatalyürek

Assistant Professor, Department of Cardiothoracic Vascular Surgery, Dokuz Eylül University

S. Bayar

Registrar, Department of Anesthesiology, Dokuz Eylül University

Z. Elar

Professor, Department of Anesthesiology, Dokuz Eylül University

O. Oto

Professor, Department of Cardiothoracic Vascular Surgery, Dokuz Eylül University