

# Outcome of Two Surgical Options Used in Treatment of Chiari Type-One Malformation

M G Ammar

## Citation

M G Ammar. *Outcome of Two Surgical Options Used in Treatment of Chiari Type-One Malformation*. The Internet Journal of Neurosurgery. 2015 Volume 11 Number 1.

DOI: [10.5580/IJNS.30675](https://doi.org/10.5580/IJNS.30675)

## Abstract

Background/aim : Controversy for the optimum surgical plan for Chiari malformation type 1 is evident especially if it was associated with syringomyelia, the aim of this study is to determine the outcome of the two surgical options used in treatment of chiari malformation type 1 patients either bony decompression alone or combined with duraplasty .

Patients and Methods: a retrospective study was undertaken on the medical records of 25 surgical corrections of Chiari malformation type I performed at Zagazig university hospitals, Egypt, from 2002 to 2012.

Results: Of the 11 patients who did bony decompression only, 6 patients without syringomyelia revealed improvement postoperatively; of the 5 patients with syringomyelia, four patients showed improvement, including two with a decrease in the cavity size. Among the 14 patients who underwent duraplasty, improvements were detected in 5 of the six patients without syringomyelia and in all eight patients with syringomyelia.

Conclusion: Suboccipital craniectomy, C1 laminectomy, and duraplasty for the treatment of Chiari I malformation may benefit more the group of patients with associated syringomyelia, compared with Suboccipital craniectomy and C1 laminectomy alone. Further studies are needed in order to better determine these Chiari I malformation patients which are better treated with posterior fossa decompression, and others whom pathology required both duraplasty and bony decompression.

## INTRODUCTION

Chiari malformation type I (CM-I) is a congenital disease characterized by descent of the cerebellar tonsil and crowding in the craniocervical junction area, which was first described by Hans Chiari over one century ago [8]. Generally, about 50~70% CM- I cases are associated with syringomyelia (SM), which will slowly lead to chronic and sometimes irreversible myelopathy [3,15,16,33]. Although many individuals with CM-I are asymptomatic, the malformation can cause headaches, cerebellar ataxia, ocular disturbances, spasticity or lower cranial nerve affection. [3]. Since many cases of CM-I are asymptomatic, prevalence may not be accurate. However, a retrospective investigation of brain magnetic resonance images (MRIs) reported that the prevalence of CM-I was one case in 1,280 individuals [31]. Surgery is the only way to cure this disease. There are still obvious controversies in current surgical approaches although the expansion of posterior fossa volume has been widely accepted as the surgical goal [1,2,15,16,18,24]. The various surgical approaches attempted have included suboccipital craniectomy, syringosubarachnoid or fourth

ventriculo subarachnoid shunting, obex plugging, and syringostomy, [3,7,9,11,13]. Patients with syringomyelia have a poorer outcome with surgery, compared with those without syringomyelia [6, 21]. In the present report, we review our experience with the treatment of CM-I in patients who underwent suboccipital bony decompression with or without duraplasty.

## PATIENTS AND METHODS

A total of 25 symptomatic patients with CM- I (11 men and 14 women; age range, 23-62 years; median age at surgery was 41.8 years were treated surgically at the Department of Neurosurgery , Zagazig university hospitals between 2002 and 2012. Preoperative MRI scan revealed that 13 cases were associated with Syringomyelia. We retrospectively analyzed the surgical results with a minimum of 1 year of postoperative follow-up (mean 36 months).

## Preoperative Clinical Symptoms

Preoperative neurological examinations were routinely performed. Sensory disturbance (38.5%), pain (23.1%) and

motor weakness and muscular atrophy (23.1%) were the three main symptoms in CM- I patients with SM. Pain (41.7%), cerebellar dysfunctions (33.3%) and cranial nerve dysfunctions (25%) were the three main symptoms in patients without SM. Further details are presented in Table 3.

### Preoperative Imaging

Patients generally underwent magnetic resonance imaging (MRI) preoperatively and the diagnosis of CM- I was defined as tonsillar herniation extending at least 5mm below the foramen magnum without meningocele (14). SM was found by preoperative MRI in 13 patients. MR imaging was performed with a 1.5-T Philips Achieva system by using a head coil with the patient in supine position. MR imaging was done in axial, and sagittal scans with the following parameters: T1WI (TR148- 97/TE2-15), T2WI (TR4400-4800/TE110) and FLAIR (TR6000/TE120-TI2000), Section thickness was 5 mm with a gap of 1 mm. All MRI examinations were performed at the initial and follow up examinations.

### Surgical technique:

The specific surgical procedure, i.e. non-duraplasty (without durotomy) or duraplasty was chosen by each surgeon on the basis of personal preference and training. All patients underwent decompressive sub occipital craniectomy extending at least 2 cm above the foramen magnum, with bilateral atlas laminaectomy. Eleven of the patients then underwent removal of all dural bands or scarring on the outer dura, fourteen patients underwent bone removal plus dural grafting using the fascia lata. Clinical and radiological Follow-up was performed postoperatively at 1, 3, 6 months and one year. For patients with postoperative MRI images, the change in the size of the syringomyelia cavity was classified as decreased diameter (improved) , unchanged or increased. This study was approved by the local ethics committee.

## RESULTS

Of the 11 patients who did suboccipital craniectomy , six patients without syringomyelia showed improvement postoperatively; of the other five patients with syringomyelia, four of them showed clinical improvement, including two with a decrease in the syrinx size. Two patients showed improvement in symptoms but the syrinx size was unchanged. The syrinx size increased in the one patient whose clinical condition did not show improvement

(Table 2). Among the 14 patients who underwent dural grafting, improvement was noted in 5 of the six patients without syringomyelia and in all of the eight cases with syringomyelia. All of the patients with syringomyelia showed a decrease in the size of their syringomyelia and clinical improvement (Table 3). with durotomy cases, the surgical complications included two cases of cerebrospinal fluid (CSF) leaks associated with subgaleal CSF collection in one patient and aseptic meningitis in one patient; both required no more than conservative treatment ; one case of postoperative occipital neuralgia and superficial wound infections in one patient. No complication other than superficial wound infection recorded when the dura was not opened.

**Table 1**

Clinical and surgical groups of the patients. CM: chiari malformation, SM: syringomyelia. PFD: posterior fossa decompression

Patient group	PFD only (11)	PFD+duraplasty(14)
Chiari malformation (CM) 12	6	6
CM+SM 13	5	8

**Table 2**

Clinical and radiological summary of patients.

Patient	Age(yrs)	sex	Syringomyelia	Uraplasty
1	34	F	NO	YES
2	29	M	YES	NO
3	47	F	YES	NO
4	52	M	NO	YES
5	39	F	YES	YES
6	36	F	NO	NO
7	60	F	NO	YES
8	55	M	YES	YES
9	27	M	YES	NO
10	29	F	YES	YES
11	53	F	NO	YES
12	42	M	NO	NO
13	62	F	YES	NO
14	23	F	YES	YES
15	28	F	YES	YES
16	34	M	NO	YES
17	29	F	YES	YES
18	47	M	YES	YES
19	52	F	NO	NO
20	55	M	NO	N'O
21	43	F	YES	YES
22	39	M	NO	YES
23	36	F	NO	NO
24	45	M	YES	NO
25	50	M	NO	NO

**Table 3**

Preoperative symptoms/signs of patients. CM: chiari malformation, SM: syringomyelia.

Symptom/sign	CM	CM+SM
pain	5	3
Sensory disturbance	-	5
Weakness&muscular atrophy	-	3
Gait problems or ataxia	4	2
Cranial nerve dysfunction	3	-
total	12	13

**Table 4**

Clinical summary of patients who did posterior fossa decompression only.

Patient	Syringomyelia	Syringomyelia decrease	Symptom improvement
2	yes	yes	yes
3	yes	no	no
6	no	-	yes
9	yes	yes	yes
12	no	-	yes
13	yes	no	yes
19	no	-	yes
20	no	-	yes
23	no	-	yes
24	yes	no	yes
25	no	-	yes

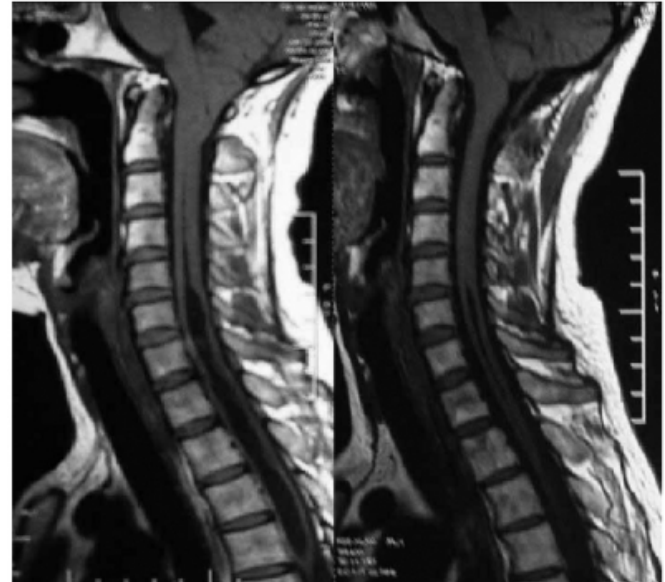
**Table 5**

Clinical summary of patients who underwent posterior fossa decompression and duraplasty.

Patient	Syringomyelia	Syringomyelia decrease	Symptom improvement
1	no	-	yes
4	no	-	yes
5	yes	yes	yes
7	no	-	no
8	yes	yes	yes
10	yes	yes	yes
11	no	-	yes
14	yes	yes	yes
15	yes	yes	yes
16	no	-	yes
17	yes	yes	yes
18	yes	yes	yes
21	yes	yes	yes
22	no	-	yes

**Figure 1**

A) preoperative MRI showed chiari type one malformation with tonsillar herniation extending below foramen magnum more than two cm in addition to marked syringomyelia B) postoperative MRI reveals decrease of syringomyelia and elevation of the cerebellar tonsi. (duraplasty group)



## DISCUSSION

A hypothesis regarding the pathogenesis of CM-I is that the posterior fossa and hindbrain structures are dislocated into the spinal canal after birth due to small posterior cranial fossa volume which is caused by the retarded development of the occipital bone during the embryonic period [14]. However, the pathogenesis of syringomyelia remains unclear. The 3 main theories which try to explain the formation of syringomyelia are Gardner's hydrokinetics, Oldfield's CSF and spinal substance penetration and Williams' intracranial and intraspinal pressure dissociation. [27]. Partial obstruction in the foramen magnum area blocks the normal circulation of CSF which is a major factor in the development and progression of syringomyelia; CM-I patients usually have increased atlanto-occipital fascia thickness and narrowed cisterna magna, The longer the duration of CM-I and the more severe the condition, the narrower the subarachnoid space. The false membrane at the orifice of the spinal canal is one of the causes of intraspinal canal fluid accumulation and the formation of a syrinx. [5]; CM-I is congenital, whereas Syringomyelia is acquired. When the obstruction of the subarachnoid space reaches a certain extent, Syringomyelia may occur. At present, the main treatment of CM-I complicated with SM is surgery. However, surgical treatment retards the disease's progression rather than curing the damage caused to the spinal cord. [5]

Sub occipital craniectomy essential to relieve the bony compression at the craniocervical junction. [30] However, no agreement on safety and usefulness of additional procedures, such as duraplasty, obex plugging or syringosubarachnoid shunting. [25] There is no direct neurological deficit that has been demonstrated as a result of tonsillar resection [17]. However, the surgical effect of cerebellar tonsillectomy may lead to further arachnoidal scarring at the foramen magnum with aggravation of syringomyelia and symptoms [4,19].

The purpose of surgery for CM-I is enlargement of the cisterna magna, thereby allowing improved CSF flow, this could be obtained by adequate bone removal. [22] Four of our five patients with syringomyelia showed improvement with bone removal only, and two (40%) of the five showed a decrease in the syrinx size. The two patients with a decrease in syrinx size showed an increase in CSF space behind the cerebellum. The patient with no change in the cavity size showed no change in the CSF space behind the cerebellum. All of the eight patients with syringomyelia who underwent duraplasty showed improvement and all eight (100%) showed a decrease in syrinx size. Five of the six patients without syringomyelia who underwent duraplasty showed clinical improvement. It therefore seems that duraplasty provides a better chance of enlarging the size of the cisterna magna, , this agree with results of Munshi et al; 2000 whom reviewed the medical records and magnetic resonance imaging (MRI) scans of 34 surgical corrections' of Chiari malformation performed from 1988 to 1998, the type of surgery (duraplasty or non duraplasty), the presence of syringomyelia , and the clinical outcome were determined. [25] Munshi et al; 2000 reviewed 11 patients whom underwent posterior fossa decompression (PFD) and C1 laminectomy without dural opening, they reported 8 (73%) of these patients had clinical improvement. 7 of the 11 patients had syringomyelia. Of the 6 patients who underwent follow-up MRI, 3 (50%) had a decrease in the size of the syringomyelia, and all 3 had clinical improvement. Munshi et al; 2000 also reported a morphometric increase in posterior fossa volume on postoperative MRI scans in these three patients, which was not documented in those without improvement. Two of the three patients whose syringomyelia did not decrease on follow-up MRI scans worsened clinically, and one underwent a reoperation with dural grafting. 23 patients underwent combined Posterior fossa decompression, C1 laminectomy, and duraplasty. 20 (87%) of these patients had improvement. Twelve of the patients who underwent duraplasty had syringomyelia; nine

underwent follow-up MRI. All nine of these patients (100%) had a decrease in the cavity size, including eight with clinical improvement. [25] These results agree with our results as in the post fossa decompression alone group out of eleven patients only one patient (9.1%) did not show clinical improvement and ten patients (90.9%) show symptom improvement, while in the duraplasty group out of the 14 patients only one patient (7.1%) did not show clinical improvement and thirteen patients (92.9%) show symptoms improvement. In a review of patients who underwent Chiari decompression with or without duraplasty, Matsumoto and Symon [21] noted no difference in the reduction of syringomyelia, while Munshi et al. showed that regarding the improvement in symptoms, patients doing bony decompression alone had a significantly bad outcome, compared with those who underwent both bony decompression and duraplasty. [25] Complications such as transient postoperative swallowing problems, cerebellar infarctions and electrolyte imbalances have been reported after Chiari surgery [9, 26]. CSF leaks reported in two cases and secondary stitches resolved the leaks. The subgaleal fluid collections that developed after surgery were also resolved conservatively with tight bandage. Occipital neuralgia, reported in one patient and improved with medical treatment; Eight cases of subdural hygroma after foramen magnum decompression with duraplasty have been reported in literature. [12, 20, 28, 29] Hygroma become symptomatic 5 to 21 days after foramen magnum decompression in all cases. Suzuki et al; 2011 [32] reviewed postoperative subdural hygromas and concluded that caution should paid if CSF leakage has occurred even if very small and the arachnoid appears intact, Suzuki et al recommend wide opening of the arachnoid intraoperatively which may aid spontaneous resolution of subdural hygroma, no subdural hygromas were reported as postoperative complication in our series. There is a concept that patients with syringomyelia may benefit more after undergoing duraplasty. Some patients showed a decrease in syringomyelia, with an improvement in symptoms, through bone removal alone. This improvement was linked to an increase in the size of the cisterna magna, allowing improved CSF flow resulting in resolution of the syringomyelia. It therefore seems that duraplasty provides a better chance of enlarging the size of the cisterna magna and decrease in concurrent syringomyelia. However, a group of patients whose syringomyelia will decrease through bone removal alone still exists. our results stated that cases with syringomyelia may benefit more from bony decompression

combined with dural grafting while chiari one cases without syringomyelia improved after bony decompression alone without added risk of durotomy such as arachnoid scarring and CSF leak, cerebellar ptosis. Recently, endoscopic approaches for the management of Chiari I malformation have been reported as minimally invasive surgical strategy for CM-I patients.[10]; Further studies are needed in order to better determine these Chiari I malformation patients which are better treated with posterior fossa decompression , and others whom pathology required both duraplasty and bony decompression.

### References

- 1) Aghakhani N, Parker F, David P, Morar S, Lacroix C, Benoudiba F, Tadie M : Long-term follow-up of Chiari-related syringomyelia in adults. Analysis of 157 surgically treated cases. *Neurosurgery* 64: 308-315, 2009.
- 2) Alden TD, Ojemann JG, Park TS: Surgical treatment of Chiari I malformation. Indications and approaches. *Neurosurg Focus* 11:E2, 2001.
- 3) Armonda RA, Citrin CM, Foley KT, Ellenbogen RG: Quantitative cine mode magnetic resonance imaging of Chiari I malformations. An analysis of cerebrospinal fluid dynamics. *Neurosurgery* 35: 214-224, 1994.
- 4) Asgari S, Engelhorn T, Bschor M, Sandalcioğlu IE, Stolke D: Surgical prognosis in hindbrain related syringomyelia. *Acta Neurol Scand* 107:12-21, 2003.
- 5) Bao C, Yang F, Liu L, Wang B, Li D, Gu Y, Zhang S, Chen L: Surgical treatment of Chiari I malformation complicated with syringomyelia. *Exp Ther Med* 5(1):333-337, 2013.
- 6) Barbaro NM, Wilson CB, Gutin PH, Edwards MS: Surgical treatment of syringomyelia. Favorable results with syngo-peritoneal shunting. *J Neurosurg* 61:531-538, 1984.
- 7) Batzdorf U: Chiari I malformation with syringomyelia. Evaluation of surgical therapy by magnetic resonance imaging. *J Neurosurg* 68:726-730, 1988.
- 8) Chiari H: Über Veränderungen des Kleinhirns infolge von Hydrocephalie des Grosshirns *Dtsch. Med. Wochenschr* 17:1172-1175, 1891 (in German).
- 9) Dauser RC, DiPietro MA, Venus JL: Symptomatic Chiari I malformation in childhood. A report of 7 cases. *Pediatr Neurosci* 14:184-190, 1988.
- 10) Deng K, Li GL, Gao J, Yang Z, Di X, Wang RZ: Neural endoscopic assisted micro-invasive management of Chiari I malformation. *Chin Med J* 123:1878-1883, 2010.
- 11) Duddy MJ, Williams B: Hindbrain migration after decompression for hindbrain hernia. A quantitative assessment using MRI. *Br J Neurosurg* 5:141-152, 1991.
- 12) Elton S, Tubs RS, Wellons JC III, Blount JP, Grabb PA, Oakes WJ: Acute hydrocephalus following a Chiari I decompression. *Pediatr neurosurg* 36: 101-104, 2002.
- 13) Fujii K, Natori Y, Nakagaki H, Fukui M: Management of syringomyelia associated with Chiari malformation. Comparative study of syrinx size and symptoms by magnetic resonance imaging. *Surg Neurol* 36(4):281-285, 1991.
- 14) Furtado SV, Thakre DJ, Venkatesh PK, Reddy K, Hegde AS : Morphometric analysis of foramen magnum dimensions and intracranial volume in pediatric Chiari I malformation. *Acta Neurochir (Wien)* 152: 217-221, 2010.
- 15) Goel A, Desai K: Surgery for syringomyelia. An analysis based on 163 surgical cases. *Acta Neurochir* 142: 293-302, 2000.
- 16) Isu T, Sasaki H, Takamura H, Kobayashi N: Foramen magnum decompression with removal of the outer layer of the dura as treatment for syringomyelia occurring with Chiari I malformation. *Neurosurgery* 33:845-850, 1993.
- 17) Lazareff JA, Galarza M, Gravori T, Spinks TJ: Tonsillectomy without craniectomy for the management of infantile Chiari I malformation. *J Neurosurg* 97:1018-1022, 2002
- 18) Levy WJ, Mason L, Hahn JF: Chiari malformation presenting in adults. A surgical experience in 127 cases. *Neurosurgery* 12: 377-390, 1983.
- 19) Ma J, You C, Chen H, Huang S, Jeong C: Cerebellar tonsillectomy with suboccipital decompression and duraplasty by small incision for chiari I malformation (with syringomyelia). Long term follow- up of 76 surgically treated cases. *Turkish neurosurgery* 22, no: 3,274-279, 2012.
- 20) Marshman LAG, Benjamin JC, Chawda SJ, David KM: Acute obstructive hydrocephalus associated with infratentorial subdural hygromas complicating Chiari malformation type I decompression. Report of two cases and literature review. *J Neurosurg* 103:752-755, 2005.
- 21) Matsumoto T, Symon L: Surgical management of syringomyelia. Current results. *Surg Neurol* 32:253-256, 1989.
- 22) McGirt MJ, Nimjee SM, Floyd J, Bulsara KR, George TM: Correlation of cerebrospinal fluid flow dynamics and headache in Chiari I malformation. *Neurosurgery* 56:716-721, 2005.
- 23) Menezes AH: Chiari I malformations and hydromyelia. Complications. *Pediatr. Neurosurg* 17:146-154, 1991.
- 24) Michael B. Pritz: Surgical treatment of Chiari I malformation. Simplified technique and clinical results. *Skull Base* 13: 173-177, 2003.
- 25) Munshi I, Frim D, Stine-Reyes R, Weir BK, Hekmatpanah J, Brown F: Effects of posterior fossa decompression with and without duraplasty on Chiari malformation- associated hydromyelia. *Neurosurgery* 46:1384-1390, 2000.
- 26) Nagib MG: An approach to symptomatic children (age 4-14 years) with Chiari type 1 malformation. *Pediatr Neurosurg* 21:31-35, 1994.
- 27) Park YS, Kim DS, Shim KW, Kim JH, Choi JU: Factors contributing improvement of syringomyelia and surgical outcome in type I Chiari malformation. *Childs Nerv Syst* 25: 453-459, 2009.
- 28) Perrini P, Rawlinson A, Cowie RA, King AT: Acute external hydrocephalus complicating craniocervical decompression for syringomyelia-Chiari I complex. case report and review of the literature. *Neurosurg Rev* 31: 331-335, 2008.
- 29) Ranjan A, Cast IP: Symptomatic subdural hygroma as a complication of foramen magnum decompression for hindbrain herniation (Arnold-Chiari deformity). *Br j Neurosurg* 10: 301-303, 1996.
- 30) Romero FR, Pereira CA: Suboccipital craniectomy with or without duraplasty- what is best choice in patients with Chiari type 1 malformation. *Arq neuropsiquiatr* 68(4):623-626, 2010.
- 31) Stover LJ, Bergan U, Nilsen G, Sjaastad O: Posterior cranial fossa dimensions in the Chiari I malformation. Relation to pathogenesis and clinical presentation. *Neuroradiology* 35:113-118, 1993.
- 32) Suzuki F, Kitagawa T, Takagi K, Nozaki K: Subacute subdural hygroma and presyrinx formation after foramen magnum decompression with duraplasty for chiari type 1 malformation. Case report. *Neurol Med Chir (Tokyo)* 51:389-393, 2011.
- 33) Williams B: On the pathogenesis of syringomyelia: A

review. J Roy Soc Med 73: 798–806, 1980.

**Author Information**

**Mohamed Gouda Ammar**

Lecturer of Neurosurgery, Zagazig University

Zagazig, Egypt

ammarmg@gmail.com