

---

# Pseudotumor Of Metatarsal: A Thorny Problem

N Dastgir, P O'Rourke

---

## Citation

N Dastgir, P O'Rourke. *Pseudotumor Of Metatarsal: A Thorny Problem*. The Internet Journal of Orthopedic Surgery. 2002 Volume 1 Number 2.

## Abstract

An insidious onset of a lytic lesion in the base of 1<sup>st</sup> metatarsal of an eleven-year-old boy is presented. Surgical exploration revealed a 1.5 cm black thorn embedded in granulation tissue. Despite the absence of a definite history of trauma, an organic foreign body lesion should be considered in the differential diagnosis of a lytic lesion of bone.

## CASE REPORT

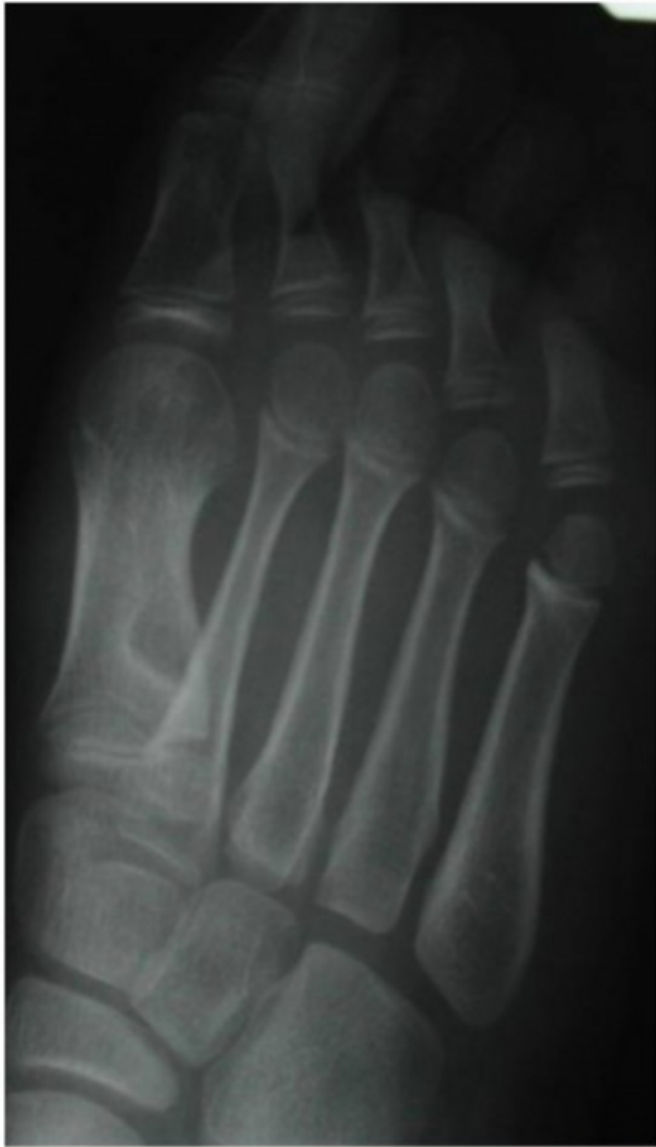An eleven-year-old boy was referred by his general practitioner with an insidious onset of a limp and swelling on dorsum of his left foot of two-month duration. The patient himself did not recall any penetrating injury to his foot. On close enquiry patient gave a history of playing in the woods a few months back. Clinical examination revealed

a large, tender swelling overlying the base of 1<sup>st</sup> metatarsal with no local signs of inflammation.

Laboratory investigations revealed a WBC of  $6.55 \times 10^3$  /ml & ESR of 4mm/hour. Radiographs of the foot revealed an osteolytic lesion with a sclerotic rim in the metaphysis of the 1<sup>st</sup> metatarsal. (Fig 1).

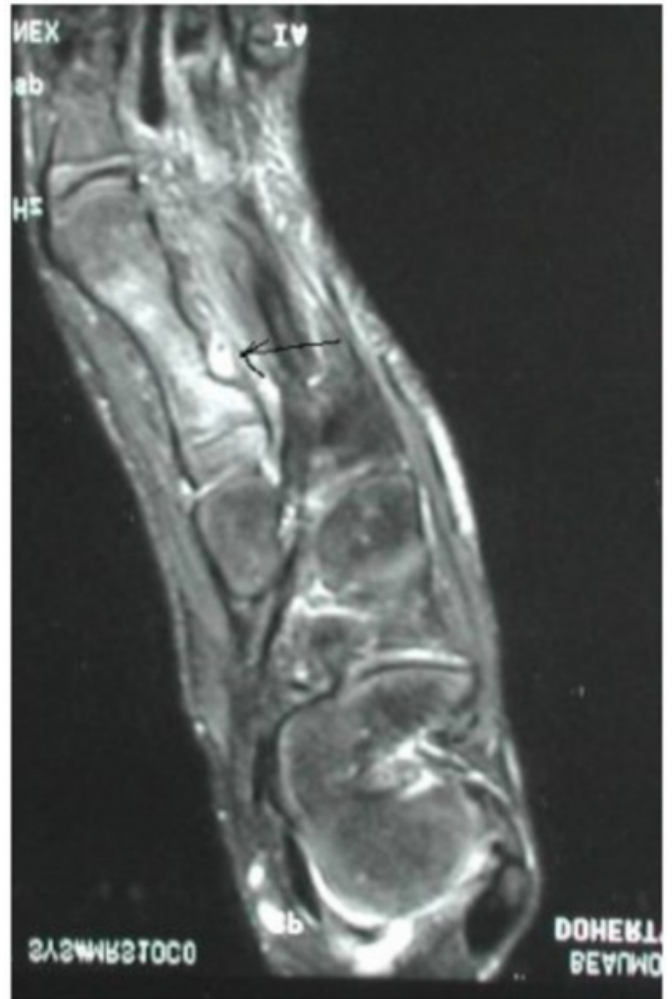
**Figure 1**

Figure 1: Plain X Ray showing a lytic lesion at the base of 1<sup>st</sup> Metatarsal



**Figure 2**

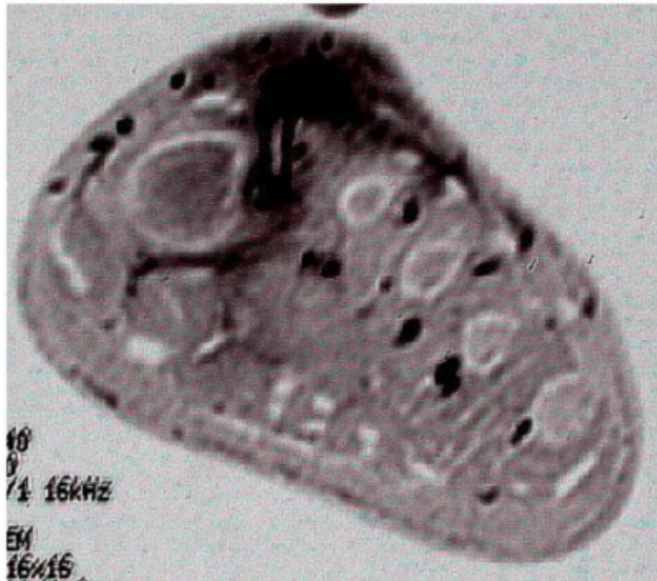
Figure 2: Altered soft tissue signal on T 2 image



There was increased uptake in all three phases of Bone scan . The patient was treated with intravenous flucloxacillin and benzyl penicillin for 10 days with a presumptive diagnosis of osteomyelitis, but failed to show any response. An MRI scan showed diffusely altered soft tissue signal with a sinus tract formation centering on medial aspect of proximal 1<sup>st</sup> metatarsal with bone erosion and reactive marrow edema (fig 2 and 3).

**Figure 3**

Figure 3: Tract formation centering on medial aspect of 1<sup>st</sup> metatarsal



Surgical exploration through 1<sup>st</sup> web space revealed a 1.5 cm black thorn embedded in granulation tissue in the base of the 1<sup>st</sup> metatarsal bone. The wound was curetted, washed and closed.

## DISCUSSION

Penetrating injury to the hand and foot by foreign body are common. Immediate removal cause little morbidity. Many of these are caused by thorns or splinters of wood that are retained in the hand or foot creating a foreign body granuloma [1]. Embedded thorns have been reported to cause bone lesions resembling those of osteomyelitis [2]. Organic material when present in or near a bone can produce a pathological reaction, either osteolytic, osteoblastic or combination of both, the radiological appearance of which may resemble a soft tissue tumour. Symptomatic lesions may appear years after initial injury and patient may not recall a specific traumatic event [3]. Various manifestations of the black thorn (*Pranus spinosa*) penetrating the skin have been reported [4]. Because of exposure, hands are the most common site for thorns or splinters. The second common site is the foot, of which 5 metatarsal cases [5,6], one cuneiform [7], one cuboids [8] and one phalangeal lesion [9] have been reported in the literature. Thorns have been shown to cause foreign body cysts, bursitis, tenosynovitis, synovitis & also bony reaction. Case reports in the literature reveal a consistent feature of patient's delay in seeking medical advice and clinician's delay in reaching correct diagnosis. In thirty-one reported cases, nineteen had osteolysis, five had

periosteal reaction without osteolysis and seven cases had a combination of both. The mean time at presentation in different case reports in the literature was 4 months [10]. In recent years with the use of Ultrasound, C.T scan and MRI scan any suspected foreign body detection has been increased [11,12,13]. But it has been also reported that splinters that have been there for less than three days are not detected reliably by any of the imaging method [12].

It was also found in different cases that foreign body was hypointensive on T1 weighted images and most important factor for identification by MRI is the presence of a surrounding rim of fluid rich granulation tissue or fluid filled cyst [14,15].

## CONCLUSION

The presence of a thorn in or adjacent to a bone induces a foreign body reaction, osteolysis and/or periosteal reaction of the bone. One should be aware of the characteristic clinical and radiological presentation in the differential diagnosis of hand and foot tumors. MRI scan was found to be a sensitive diagnostic tool. Treatment should be aimed at operative exploration, debridement with appropriate antibiotics.

## CORRESPONDENCE TO

Nabeel Dastgir Specialist Registrar Trauma & Orthopaedics  
76 Culcranagh Dooradoyle Limerick. Ireland. Tel:  
00353-61-228285 E-mail: nabeel@esatclear.ie

## References

1. Borgia CA. An unusual bone reaction to an organic foreign body in the hand. *Clin Orthopaedics* 1963; 30; 188-93.
2. Rosenfield R et al. Thorn induced periostetitis associated with *Enterobacter agglomerans* infection. *Canadian Med Ass. J.* 1978; 119; 925.
3. Reginato A J et al . Clinical and pathologic studies of 26 patients with penetrating foreign body injury to the joint, bursae and tendon sheaths. *Arthritis Rheum.* 1990;33:1753-62.
4. Kelly J J. Black thorn inflammation. *J Bone Joint Surg (Br)*; 1966; 48:474-7.
5. Floman Y, Katz S. Osseous lesion simulating bone tumour due to an unexpected fragment of wood in the foot. *Injury* 1975; 6:344-5.
6. Middha V P, Vaishya R. Lesions produced by splinters of wood in soft tissues and bone. *Int Orthopaedics* 1990; 14:47-8.
7. Weston W J. Thorn and twig induced pseudotumours of bone and soft tissues. *British J Radiology* 1963; 36:323-6.
8. Hughes SF, Maffulli N, Fixsen JA. Thorn induced granuloma of the medial Cuneiform. *J Foot Surgery.* 1992; 31:247-9.
9. Yousefzadeh D K, Jackson JH Jr. Organic foreign body reaction. *Skeletal Radiology* 1978; 3:167-7.
10. Durr H D, Stabler A, Muller P E, Refior H.J. Thorn

induced Pseudotumor of the metatarsal. J Bone Joint Surg (A); April 2001;VOL 83A, 4; 580-84.

11. Banerjee B, Das R K. Sonographic detection of foreign bodies of the extremities. British J Radiology.1991; 64:107-12.

12. Mizel M S, Steinmetz N D, Trepman E. Detection of wooden foreign bodies in muscle tissues: experimental comparison of C.T, MRI and ultrasonography. Foot Ankle International 1994; 15:437-43.

13. Kornreich L, Katz K, Horev G, Zeharia A, Mukamel M.

Preoperative localization Of foreign body by magnetic resonance imaging. European Journal of Radiology 1998; 26:309-11.

14. Maillot F, Goupille P, Valat J P. Plant thorn synovitis diagnosed by magnetic resonance imaging. Scand. Journal of Rheumatology.1994; 23:154-5.

15. Grainger A J, Campbell R S. Post-traumatic bone cyst: a case of the floating fragment. Skeletal Radiology 1998; 27; 400-2.

**Author Information**

**N. Dastgir, FRCS**

Department of Orthopaedics, General Hospital

**P. O'Rourke, MCh, FRCS**

Department of Orthopaedics, General Hospital