

# Epilepsy, Hypogonadotropic Hypogonadism, and Systemic Lupus Erythematosus

C Hobson, H Foyaca-Sibat, L Ibanez-Valdes, B Hobson

## Citation

C Hobson, H Foyaca-Sibat, L Ibanez-Valdes, B Hobson. *Epilepsy, Hypogonadotropic Hypogonadism, and Systemic Lupus Erythematosus*. The Internet Journal of Neurology. 2006 Volume 6 Number 1.

## Abstract

We report on a patient with uncontrolled epilepsy, hypogonadotropic hypogonadism and systemic lupus erythematosus in a rural setting of the Eastern Cape, South Africa.

## INTRODUCTION

Gonadal function is significantly affected in many acute and chronic systemic diseases. As the function of the testes and the ovaries is determined by the integrity of the hypothalamic–pituitary–gonadal axis, it is obvious that a systemic disease may affect one or more levels of the axis in such a manner that the gonadal dysfunction may have various clinical and laboratory manifestations. In this brief review, the most common disturbances seen in the main systemic diseases will be discussed, and the relationship between epilepsy, hypogonadotropic hypogonadism and systemic lupus erythematosus examined.

## CASE REPORT

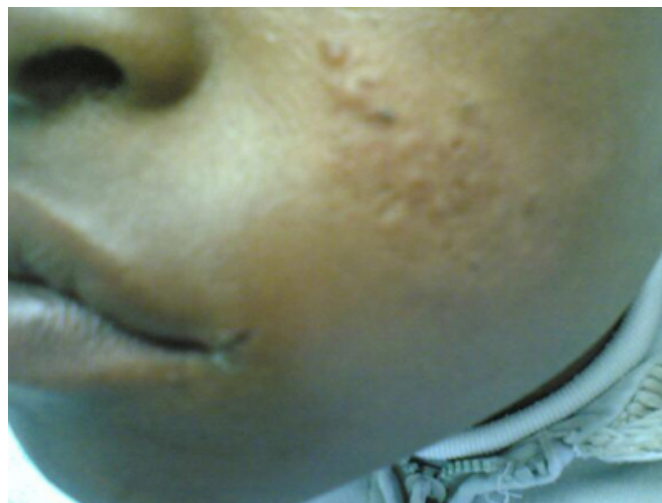A 23 year old male presented at Nelson Mandela Academic Hospital (Mthatha) with a longstanding history of uncontrolled epilepsy. He experienced up to 2 fits per day, which were generalised tonic-clonic. The patient claimed to be compliant on an unknown dose of carbamazepine and phenobarb, which he received at a peripheral clinic.

According to his family the patient had a normal development as a young child, but at the age of 12 he developed a malar rash, and all developmental progression seized. This developmental delay was never brought under the attention of any health worker.

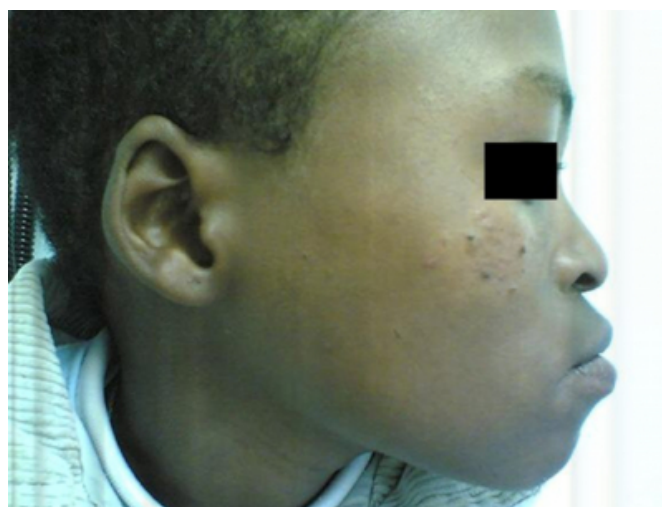On examination the patient was in a good general condition, with normal vital signs. A malar rash was evident. He had an abnormally short stature of 149 cm, no secondary sexual characteristics, and had only a right sided palpable testis. Systemic examination, including neurological, was within normal limits.

**Figure 1**

Figures 1 and 2: Malar rash



**Figure 2**



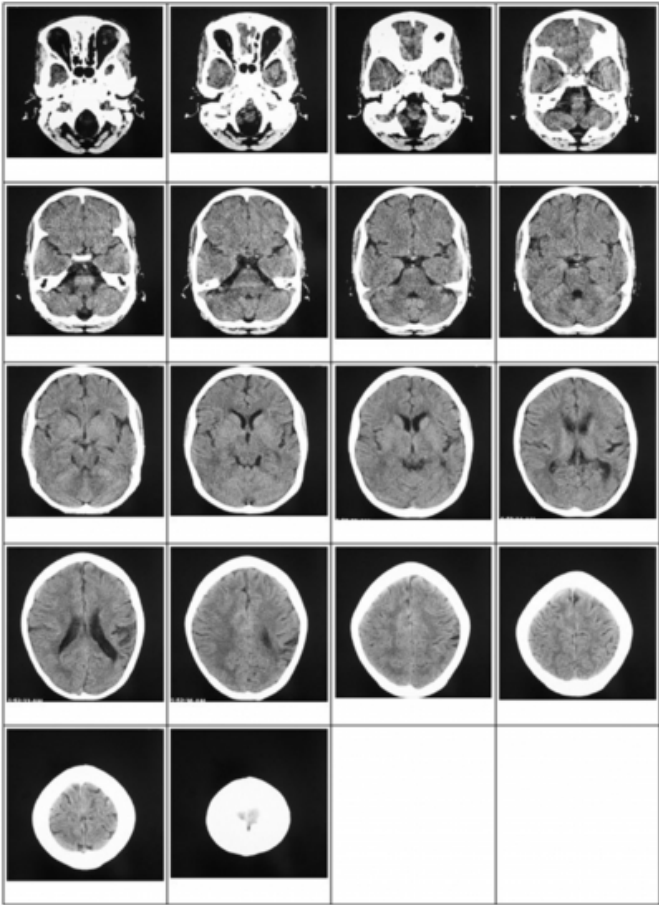
The patient was admitted, and his seizures were well controlled on carbamazepine 200mg tds orally. Early during his stay he had a seizure while taking a bath, and subsequently sustained 10% body surface area burns, which necessitated a skin graft and physiotherapy.

Later during his stay the patient had aggressive outbursts during which he assaulted a patient and threatened a health worker. At that time his seizures were well controlled, his wounds were healing well, and he expressed that he wishes to be discharged. Unfortunately the patient was lost to follow-up.

Summary of special investigations done during admission:

Figure 3

Figure 3: A CT-scan of his brain was done, which showed focally dilated sulci of the left temporal lobe, suggestive of an old infarct. No mass lesions or calcifications were noted.



DISCUSSION

Hypogonadism, a common but frequently underdiagnosed entity, is defined as a combination of abnormal serum testosterone levels and the presence of insufficient androgen end-organ tissue effect<sub>1</sub>. This diagnostic entity is

characterized by an abnormal decrease in the functional capability of the gonads. This results in the delay of growth and sexual development. Primary or hypergonadotropic hypogonadism is characterized by sex organ failure<sub>2</sub>. This discussion focuses on secondary or hypogonadotropic hypogonadism, which has many central causes:

Figure 4

Table 1: Central causes of hypogonadism, as adapted from Warren

Hypothalamic	Pituitary
Hypothalamic amenorrhea	Pituitary lesions
Exercise-induced	Prolactin-secreting adenoma
Anorexia nervosa	Craniopharyngioma (most common pituitary tumour in children)
Psychogenic	Other pituitary adenomas
Post contraceptive	Other benign tumours and cysts
Tumours	Pituitary apoplexy
Hypothalamic glioma	Infiltrative diseases
Other hypothalamic tumours	Cranial irradiation
Infiltrative diseases	
Laurence-Moon syndrome	
Bardet-Biedl syndrome	
Prader-Willi syndrome	
Head trauma	
Chronic or acute systemic illness	
Cranial irradiation	
Continuous GnRH analogue use	
Drug use	
Opioids	
Phenothiazines	
Risperidone	
Anabolic steroids	
Isolated GnRH deficiency	
Idiopathic hypogonadotropic hypogonadism	
Kallmann's syndrome	
Adrenal Hypoplasia congenital	

The hypothalamo-pituitary-gonadal axis can be interrupted by the mass effect of tumours because of spatial encroachment and compressions of the portal vessels. The resultant effect is less GnRH reaching the pituitary gland via the portal vessels. Craniopharyngiomas, the most common suprasella turcica tumour in children, are slow growing, and might only be diagnosed in early adulthood, presenting with amenorrhea, gonadotropin deficiency, hyperprolactinemia, obesity, ocular defects, and recurrent frontal headaches with vomiting<sub>2</sub>.

Figure 5

Table 2: Genetic disorders presenting with delayed puberty, adapted from Clarisa

Disorder	Genes or chromosomal abnormalities
Turner's syndrome	45X0
Gonadal dysgenesis	SRY mutations
	DAX1 duplications
	DAX1
Adrenal hypoplasia	Kal1
Kallmann's syndrome	GnRH receptor
Idiopathic hypogonadotropic hypogonadism*	15q11-13 paternal deletions or maternal isodisomy
Prader-Willi syndrome	BBS1-6
Bardet-Biedl syndrome	FSHβ, Lhβ, LH receptor, FSH receptor
Gonadotrophin abnormalities	CYP17
CYP17 deficiency	CYP19
Aromatase deficiency	Androgen receptor
Androgen Insensitivity Syndrome	Leptin, PROPI
Hypogonadotropic hypogonadism	

\*Idiopathic hypogonadotropic hypogonadism could present as autosomal dominant, autosomal recessive, X-linked or unexplained (80%).

When prepubertally acquired male hypogonadism presents with scanty body and terminal facial hair, high pitched voice, female distribution of pubic hair, small testis, small penis, little or no scrotal rugae, small prostate, and eunuchoidal proportions<sub>1</sub>.

The evaluation of hypogonadism includes the measurement of pituitary function. Thyroid and adrenal function should also be evaluated<sub>1</sub>. A good understanding of the classification of hypogonadism is needed for the interpretation of blood results.

Figure 6

Table 3: Male hypogonadism, classification and hormones

Category	Dysfunction of	Hormone levels			
		Testosterone	LH	FSH	GnRH
Primary hypogonadism	Testis	decreased or low normal	increased	increased	increased
Secondary hypogonadism	Anterior pituitary	decreased or low normal	decreased or normal	decreased or normal	increased
Tertiary hypogonadism (clinically grouped under secondary)	Hypothalamus	decreased	decreased	decreased	decreased
Isolated defect in spermatogenesis	Testicles	normal	normal	normal or increased	normal
Andropause	Testicles and hypothalamus	decreased or low normal	normal or increased	normal or increased	decreased and aberrant secretion

Imaging of the pituitary region is indicated when an organic cause is suspected. MRI is superior to CT in detecting smaller lesions, and is the imaging modality of choice. CT is adequate for detecting macro adenomas, and is a less expensive imaging option<sub>1</sub>.

Our patient does not have a definitive diagnosis of systemic lupus erythematosus (SLE). Nevertheless, this remains an interesting avenue to explore. Neuropsychiatry SLE is seen in 20% to 70% of SLE patients. Seizures, in particular, occur in 10% to 40% of paediatric cases, with generalized seizures being more common than focal seizures<sub>5</sub>.

It was shown that 88.3% of SLE patients have at least one seizure.<sup>14</sup> The incidence of epilepsy in patients with systemic lupus erythematosus is raised to between 5.4%-10%.<sup>6,7,8</sup> The seizures tend to respond to anticonvulsant drugs, and can take any form<sub>7</sub>, with various EEG abnormalities reported.<sup>6,7,9</sup> Epilepsy is particularly common in association with the presence of anticardiolipin antibodies, especially in high titre<sub>6,7</sub> the lupus anticoagulant<sub>6,10</sub>; and the antiphospholipid antibody syndrome(APS).<sup>8,9</sup> However, these findings are not universal.<sup>8,11</sup> Brain MRI tends to be normal in those with epilepsy alone<sub>7</sub>,but abnormal in those with clinical features of the APS.<sup>12</sup> In another study of patients with systemic lupus erythematosus (SLE) admitted to hospital, an association of epilepsy with stroke (clinical or on imaging) was reported.<sub>9</sub>

The role of these antiphospholipid antibodies in causing epilepsy has been open to debate. Possible mechanisms include a direct effect of antibodies causing seizures, the trapping of immune complexes within vessels resulting in seizures, and antiphospholipid antibodies causing microvascular lesions. The direct effect of antibodies in provoking epilepsy is supported by studies showing that anti-brain antibodies can directly cause seizures<sub>13</sub>; that serum from patients with SLE with epilepsy and anticardiolipin antibodies can inhibit Cl currents through the GABA receptor complex<sub>14</sub>; and that the presence of anticardiolipin antibodies in the CSF is longitudinally associated with clinical symptoms.<sup>15</sup> The finding that antiphospholipid antibodies react directly with CNS tissue<sub>16</sub> does not rule out secondary damage as a mechanism for seizures. Ischemia-induced seizures secondary to a hypercoagulable state is backed by reports of abnormal imaging and an association with stroke as a confounding factor in some groups of patients. Even in the presence of normal imaging, post-mortem has disclosed cerebral microinfarctions.<sub>7</sub> Many patients with SLE and epilepsy have no detectable antiphospholipid antibodies in the serum or the CSF, so other processes such as infection, metabolic abnormalities, or as yet unidentified antibodies could be responsible. It is of interest that anti-GM1 antibodies, reported to be epileptogenic, have been identified in 15.5% of patients with systemic lupus erythematosus.<sup>17</sup> More information can be found on the Palace's article<sub>18</sub>

Appenzeller et al<sub>19</sub> observed epileptic seizures in 11.2% of SLE patients. Antiphospholipid antibodies and stroke were related to epileptic seizures at SLE disease onset. Patients with renal flares, epileptic seizures at SLE disease onset, and

antiphospholipid antibodies were at greater risk for acute symptomatic seizures during follow-up. Recurrence of epileptic seizures occurred in 1.3% of patients and was associated with antiphospholipid syndrome.

The antiphospholipid syndrome (APS) is defined by the presence of antiphospholipid antibodies (aPL), demonstrated by ELISAs for antibodies against phospholipids and associated phospholipid-binding cofactor proteins and/or a circulating lupus anticoagulant (LA), together with diverse systemic clinical manifestations such as thrombosis, and recurrent spontaneous abortions. According to the criteria set out in Sydney the only neurological manifestations that can be suitable as APS classification criteria are ischemic events (stroke and transient ischemic attacks). However, other neurological manifestations, including seizures in particular, have been repeatedly reported in APS patients<sup>20</sup>.

Cytokines are also linked to the neuropsychiatry manifestations of SLE, including seizures<sup>21</sup>. It is suggested that pro-inflammatory cytokines are locally produced in the CNS, since the levels of IL-6 and interferon- $\gamma$  are higher in the CSF than in the plasma of patients with neuropsychiatry SLE. Many other mediators of inflammation are also suspected. Flares of SLE have also been linked to hyperestrogenic states<sup>22</sup>.

Testosterone replacement, as indicated in hypogonadism, shifts the cytokine balance to a reduced state of inflammation in hypogonadotropic males<sup>23</sup>. This treatment is an exiting possibility that could have addressed our patient's pathology on more than one level.

We agree that gonadal function, both in men and women, is seriously affected in a variety of acute and chronic diseases. In most cases, the pathophysiological mechanisms are hypothalamic dysfunction in conjunction with direct gonadal involvement. Hormonal changes in acute illnesses rarely reach the stage of inducing clinical manifestations and they are reversible in the majority of cases, following regression of the main disease. In chronic illnesses, like cirrhosis and end-stage renal disease, and in our case hormonal changes itself, provoke severe systemic manifestations and worsen prognosis. In these cases, the correction of hypogonadism neither affects the progress of the disease nor improves prognosis<sup>24</sup>.

From our knowledge this combination of clinical SLE, hypogonadotropic hypogonadism, and epilepsy is an uncommon presentation which requires a multidisciplinary

approach.

### **USEFUL LINKS**

Bardet-Biedl syndrome

[http://www.nlm.nih.gov/mesh/jablonski/syndromes/syndrom\\_e048.html](http://www.nlm.nih.gov/mesh/jablonski/syndromes/syndrom_e048.html)

Kallmann's syndrome

<http://www.medstudents.com.br/endoc/endoc1.htm>

Laurence-Moon syndrome

[http://www.nlm.nih.gov/mesh/jablonski/syndromes/syndrom\\_e393.html](http://www.nlm.nih.gov/mesh/jablonski/syndromes/syndrom_e393.html)

Pituitary Apoplexy

<http://www.emedicine.com/OPH/topic471.htm>

Prader-Willi syndrome

<http://www.emedicine.com/ped/topic1880.htm>

Turner Syndrome

<http://www.emedicine.com/ped/topic2330.htm>

### **ACKNOWLEDGEMENTS**

The authors wish to thank Dr. Greg Hough for his advice regarding the preliminary investigations done, and Ben-Barend Grib for his technical assistance with the writing of this case report.

### **References**

1. Grant NN; Anawalt BD. Male hypogonadism in the primary care clinic. *Prim Care Clin Office Pract* 2003;30:743-763
2. Warren MP; Vu C. Central causes of hypogonadism - functional and organic. *Endocrinol Metab Clin N Am* 2003;32:593-612
3. Gracia CR; Driscoll DA. Molecular basis of pubertal abnormalities. *Obst Gynecol Clin N Am* 2003;30:261-277
4. Jarow JP. Endocrine causes of male infertility. *Urol Clin N Am* 2003;30:83-90
5. Benseler SM; Silverman ED. Systemic Lupus Erythematosus. *Pediatr Clin N Am* 2005;52:443-467
6. Herranz MT, Rivier G, Munther AK, et al. Association between antiphospholipid antibodies and epilepsy in patients with systemic lupus erythematosus. *Arthritis Rheum* 1994;37:568-571
7. Liou HH, Wang CR, Chen CJ, et al. Elevated levels of anticardiolipin antibodies and epilepsy in lupus patients. *Lupus* 1996;5:307-312
8. Formiga F, Mitjavila F, Pac M, et al. Epilepsy and antiphospholipid antibodies in systemic lupus erythematosus patients [letter]. *Lupus* 1997;6:486
9. Futrell N, Schultz LR, Millikan C. Central nervous system disease in patients with systemic lupus erythematosus. *Neurology* 1992;42:1649-1657
10. Mackworth-Young CG, Hughes GRV. Epilepsy: an early symptom of systemic erythematosus. *J Neurol Neurosurg Psychiatry* 1985;48:185
11. Sachse C, Luethke K, Hartung K, et al. Significance of

antibodies to cardiolipin in unselected patients with systemic lupus erythematosus: clinical and laboratory associations. *Rheumatol Int* 1995;15:23-29

12. Sabet A, Sibbitt WL, Stidley CA, et al. Neurometabolite markers of cerebral injury in the antiphospholipid antibody syndrome of systemic lupus erythematosus. *Stroke* 1998;29:2254-2260

13. Mihailovic LJT, Cupic D. Epileptiform activity evoked by intracerebral injection of anti-brain antibodies. *Brain Res* 1971;32:97-124

14. Liou HH, Wang CR, Chou HC, et al. Anticardiolipin antisera from lupus patients with seizures reduce a GABA receptor-mediated chloride current in snail neurons. *Life Sci* 1994;54:1119-1125

15. Yeh TS, Wang CR, Jeng GW, et al. The study of anticardiolipin antibodies and interleukin-6 in cerebrospinal fluid and blood of Chinese patients with systemic lupus erythematosus and central nervous system involvement. *Autoimmunity* 1994;18:169-175

16. Kent M, Vogt E, Rote NS. Monoclonal antiphospholipid antibodies react directly with cat brain. *Lupus* 1994;3:315

17. Galeazzi M, Annunziata P, Sebastiani GD, et al. Anti-ganglioside antibodies in a large cohort of European patients with systemic lupus erythematosus: clinical, serological, and HLA class II gene associations. European Concerted Action on the Immunogenetics of SLE. *J. Rheumatol.*

2000;27:135-141

18. Palace J, Blang B. Epilepsy: an autoimmune disease? *J Neurol Neurosurg Psychiatry* 2000;69:711-714

19. Appenzeller S, Cendes F, Costallat LTL. Epileptic seizures in systemic lupus erythematosus. *Neurology* 2004;63:1808-1812

20. Cimaz R, Meroni PL, Shoenfeld Y. Epilepsy as part of systemic lupus erythematosus and systemic antiphospholipid syndrome (Hughes syndrome) *Lupus*, 2006;15(4):191-197

21. Mikdashi J; Krumholz A; Handwerker B. Factors at diagnosis predict subsequent occurrence of seizures in systemic lupus erythematosus. *Neurology*

2005;64:2102-2107

22. Szyper-Kravitz M; Zandman-Goddard G; Lahita RG; Shoenfeld Y. The Neuroendocrine-Immune Interactions in Systemic Lupus Erythematosus: A Basis for Understanding Disease Pathogenesis and Complexity. *Rheum Dis Clin N Am* 2005;31:161-175

23. Malkin CJ; Pugh PJ; Jones RD; Kapoor D; Channer KS; Jones TH. The Effect of Testosterone Replacement on Endogenous Inflammatory Cytokines and Lipid Profiles in Hypogonadal Men. *Journal of Clinical Endocrinology and Metabolism* 2004;89(7)

24. Karagiannis A, Harsoulis F Gonadal dysfunction in systemic diseases. *European Journal of Endocrinology* 2005; 152(4):501-513

**Author Information**

**C. Hobson**

Division of Medicine, Department of Neurology, Nelson Mandela Academic Hospital

**H. Foyaca-Sibat**

Division of Medicine, Department of Neurology, Nelson Mandela Academic Hospital

**LdeF Ibanez-Valdes**

Division of Medicine, Department of Neurology, Nelson Mandela Academic Hospital

**B. Hobson**

Division of Medicine, Department of Neurology, Nelson Mandela Academic Hospital