

An Enhanced Method of Pediatric Urine Collection: Negative Pressure Bladder Catheterization (NPBC)

K Ambroz, W Eilber

Citation

K Ambroz, W Eilber. *An Enhanced Method of Pediatric Urine Collection: Negative Pressure Bladder Catheterization (NPBC)*. The Internet Journal of Emergency Medicine. 2002 Volume 1 Number 1.

Abstract

While bladder catheterization with a small feeding tube is an accepted method for pediatric urine collection, it is believed that syringe applied negative pressure may cause bladder wall trauma.

OBJECTIVE: Evaluate pediatric bladder trauma with applied negative pressure bladder catheterization (NPBC).

METHODS: Patients were randomized into control or NPBC groups. Controls were catheterized allowing urine to flow freely to gravity. NPBC patients had minimal negative pressure (<2cc) applied by an attached 5.0 cc syringe. Previous studies had demonstrated that a non-traumatic urethral catheterization produced < 3 RBCs/HPF.

RESULTS: Sixty-four patients were randomized with 24 controls and 40 NPBC; 39 males, 25 females, mean age = 14.75 months. No significant difference was found between the two groups neither with regard to mean age or sex nor in the percentage of patients with >3 RBCs/HPF.

CONCLUSIONS: No significant hematuria was induced by NPBC. NPBC is a safe and effective technique to obtain a sterile urine specimen during pediatric bladder catheterization.

PRESENTED AT

American College of Emergency Physicians,
Research Forum, October 1999;
Las Vegas, Nevada

INTRODUCTION

Bladder catheterization with a small caliber feeding tube is an accepted and often used method to obtain a sterile urine specimen in the pediatric patient, yet the procedure often yields an inadequate specimen secondary to poor free flow of urine to gravity. A simple method to enhance specimen collection is to apply negative pressure to the catheter with a 5.0 cc syringe. Physicians routinely avoid this method because of anecdotal reports of suction trauma to the bladder wall epithelium causing increased RBC counts on urinalysis. A thorough review of the literature failed to reveal any previous investigation verifying this alleged complication. The consensus opinion of several pediatric urologists surveyed was that minimal, if any, trauma to the bladder wall would be caused by this procedure. We believe negative pressure bladder catheterization (NPBC) is a safe and

effective method of collecting urine in the pediatric patient. We hypothesized that NPBC would not cause bladder wall epithelial trauma as indicated by significant hematuria on routine urinalysis.

METHODS

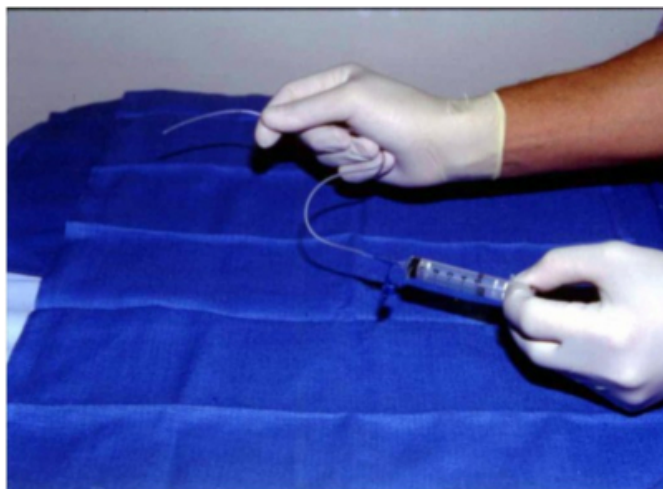
The study was approved by the Institutional Review Board and conducted in the emergency department (ED) of an urban teaching hospital with an annual census of 34,000 patients. All emergency department personnel were informed of the nature of the study and an in-service was held to orient them to the study methods and protocol. All pediatric patients under forty months requiring bladder catheterization for sterile specimen collection as part of their ED diagnostic work up were eligible. Informed consent was obtained from the parent or legal guardian prior to entrance into the study. Patients ineligible for the study included those with (1) a pre-existing or newly discovered GU anatomic abnormality, (2) a pre-existing condition causing chronic hematuria, or (3) history or evidence of recent GU trauma. In addition, study participants demonstrating current

urinary tract infection as defined by greater than 100,000 colony forming units in the catheterized urine specimen were excluded.

Patients were randomized into two groups; control and NPBC. The control group was catheterized with a lubricated 5 French standard pediatric feeding tube, which was allowed to drain freely to gravity. The study group underwent similar catheterization with a small amount of negative pressure applied by an attached 5.0 cc standard syringe (Figure 1).

Figure 1

Figure 1: Negative Pressure Bladder Catheterization (NPBC) Using a 5 cc Standard Syringe



Negative pressure was applied by hand upon entrance of the catheter into the bladder (as indicated by decreased resistance), or when the catheter had penetrated to its base. Suction pressure did not exceed 2.0 cc of intra-luminal volume of the syringe. A 3.0 – 5.0 cc volume of urine was collected from each patient and sent for routine urinalysis, culture and sensitivity. All specimens were processed using the same Ames Clinitec 200 urinalysis analyzer. Results of individual urinalysis were recorded by the ED physician and confirmed by the authors.

Routine microscope analysis of each specimen was performed. Previous studies, Hockberger, et al. ¹ and Sklar, et al. ² examined the incidence of hematuria in catheterized specimens and both studies found that < 3 RBC's/HPF could be expected in a non-traumatic catheterization. For the purposes of our study, significant hematuria was defined as > 3 RBC's/HPF.

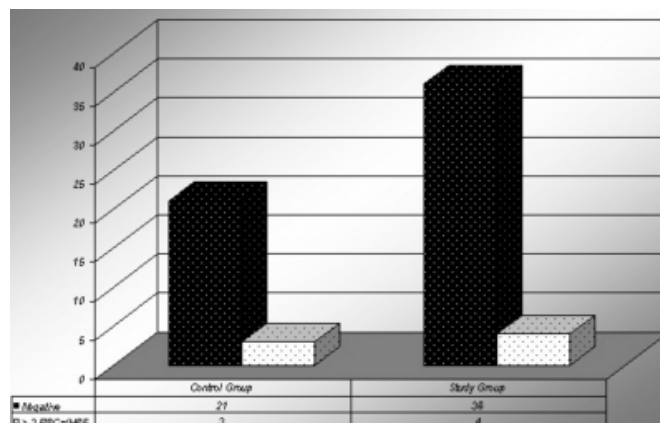
RESULTS

A total of 64 subjects were enrolled in the study; 39 male and 25 female. The age of the subjects ranged from 0.25 to

39 months with a mean age of 14.75 months. Significant hematuria (> 3 RBC's/HPF) was found in 4/40 (10.0%) of NPBC subject's urine and 3/24 (12.5%) of control subject's urine (Figure 2.0). There was no significant difference between groups with regard to mean age or sex. A Fisher exact analysis was performed with a two tailed P-value of 1.0 and an O.R.= 0.78; 95% C.I. (0.13 – 5.85). No subjects were eliminated by exclusion criteria.

Figure 2

Figure 2: Patients with Hematuria (> 3 RBCs/HPF) in Controls and NPBC Patients



DISCUSSION

The collection of a sterile urine specimen from pediatric patients can be a tedious, time consuming, and often frustrating process for the health care provider, but it is frequently necessary to complete the patient's work-up.^{3,4} Although the clean catch bag has become popular with nursing personnel and does spare the child an invasive procedure, it is often a method of futility. Every physician has waited for a child to void, only to find the bag empty and multiple studies have confirmed the inherent risk of contamination by this method.⁵ Suprapubic aspiration, although historically considered standard of care for obtaining a sterile urine specimen, is often avoided for multiple reasons. In addition to being highly invasive, requiring informed consent, and causing a great deal of anxiety for both patient and parent, suprapubic aspiration cannot be performed by nursing personnel and further taxes the physician's time.^{6,7} For all these reasons, direct urethral bladder catheterization has become the preferred method for obtaining a sterile urine specimen.

Anecdotal fear of causing bladder wall trauma by negative pressure had never been studied, but was probably the result of a 1965 article describing trauma secondary to foley catheterization. Mille's found hemorrhagic pseudopolyps on

the bladder wall epithelium in a number of autopsied patients with known history of recent catheterization.⁸ He postulated that negative pressure was being applied to the bladder wall by direct effect of intra luminal gravity on the urine column. The vertical component of this fluid column exerted a negative pressure of sufficient magnitude to draw mucosa of the collapsed bladder into the eyes of the catheter. The result was the engorgement of the mucosal vessels and the denudation of the mucosa seen at autopsy. Using a mercury manometer attached to a conventional urine drainage tube, Milles found that a water column of 30cm vertical height could generate 28 Mm Hg of negative pressure. He reproduced his findings by catheterizing 15 dogs and found hemorrhagic lesions similar to those of the autopsied patients, concluding that further study was warranted.

Our data demonstrates no significant increase in hematuria when minimal negative pressure is applied to a small catheter (5 Fr.). One limitation of the study was that no patients with documented UTI were evaluated. One can hypothesize that the inflammatory response associated with an infectious process would create a more friable bladder wall epithelium, and therefore, would be easier to damage by direct trauma. Further study in patients with culture documented UTI is warranted.

CONCLUSION

We believe negative pressure bladder catheterization is a safe and effective method of sterile urine collection. NPBC will not alter routine urinalysis results as indicated by

RBC's/HPF. It is evident that further study is indicated for patients with documented UTI.

CORRESPONDENCE TO

Karl Ambroz, MD, FACEP Resurrection Medical Center
Emergency Medicine Residency Program 7435 West Talcott
Avenue Chicago, Illinois 60631 (773) 594-7815 fax (773)
594-7805 kambroz@reshealthcare.org

References

1. Hockberger RS, Schwartz B, Connor J: Hematuria induced by urethral catheterization. *Ann.Emerg.Med.* 1987;16:550-552.
2. Sklar DP, Diven B, Jones J: Incidence and magnitude of catheter-induced hematuria. *Am.J.Emerg.Med.* 1986;4:14-16.
3. Baraff LJ, Bass JW, Fleisher GR, et al: Practice guideline for the management of infants and children 0 to 36 months of age with fever without source. Agency for Health Care Policy and Research [published erratum appears in *Ann Emerg Med* 1993 Sep;22(9):1490] [see comments]. *Ann.Emerg.Med.* 1993;22:1198-1210.
4. Brewer ED, Benson GS: Hematuria: algorithms for diagnosis. I. Hematuria in the child. *JAMA* 1981;246:877-880.
5. Bonadio WA: Urine culturing technique in febrile infants. *Pediatr.Emerg.Care* 1987;3:75-78.
6. Redman JF, Bissada NK: Direct bladder catheterization in infant females and young girls: description of an effective and painless procedure. *Clin.Pediatr.(Phila.)* 1976;15:1060-1061.
7. Pollack CVJ, Pollack ES, Andrew ME: Suprapubic bladder aspiration versus urethral catheterization in ill infants: success, efficiency and complication rates. *Ann.Emerg.Med.* 1994;23:225-230.
8. Milles G, MD: Catheter-Induced Hemorrhagic Pseudopolyps of the Urinary Bladder. *JAMA* 1999;193:196-197.

Author Information

Karl G. Ambroz, MD

Resurrection Emergency Medicine Residency Program, Resurrection Medical Center

Wes Eilber, MD

Mercy Hospital and Medical Center