

# Histological Investigation of the Effects of *Croton zambesicus* on the Liver of Swiss albino mice

D Ofusori, A Adelakun, A Ayoka, J Ibeh, A Adeeyo, A Adesanya, K Ajeigbe

## Citation

D Ofusori, A Adelakun, A Ayoka, J Ibeh, A Adeeyo, A Adesanya, K Ajeigbe. *Histological Investigation of the Effects of Croton zambesicus on the Liver of Swiss albino mice*. The Internet Journal of Gastroenterology. 2007 Volume 7 Number 1.

## Abstract

Histological effects of *Croton zambesicus* (*C. zambesicus*) traditionally used as antimalaria therapy was studied on the liver of Swiss albino mice. Mice of male sex (n=15), were randomly assigned into control group (A; n=5) and two treatments (B & C; n=10). The mice in the treatment groups received 5mg and 10mg of *C. zambesicus* per kg of body weight for five consecutive days, while the control mice received equal amounts of normal saline for the same period of days. The mice were sacrificed on day six of the experiment. The liver was excised and fixed in 10% formol saline for routine histological study adopting H&E staining procedure. Our histological findings revealed that the treated sections of the liver showed no evidence of degenerative changes, necrosis or cyto-architectural distortions of the hepatic parenchyma. These findings indicate that *C. zambesicus* consumption have no deleterious effects on the liver of Swiss albino mice up to 10mg/kg body weight and by extension may enhance the functions of the liver.

## INTRODUCTION

*Croton zambesicus* (*C. zambesicus*; Fig 1) is a medicinal plant grown in Africa particularly in Nigeria<sup>1</sup>. It is a Guineo – Congolese species widely spread in tropical Africa<sup>2</sup>. It has anti-microbial<sup>3,4</sup> and anti-hypertensive<sup>5</sup> potentials. The genus *Croton* is well known for its diterpenoid content and a lot of different types of diterpenes (phorbol esters, clerodane, labdane, kaurane, trachylobane, pimarane, etc.) have been isolated from this genus<sup>6</sup>. The role of medicinal herbs in the treatment and prevention of disease do not guaranty their safety for uncontrolled use by an uninformed public<sup>7</sup>.

The liver (the largest organ in the body) performs a number of functions some of which are plasma protein synthesis, production of bile and detoxification of most substances<sup>8</sup>. It is note worthy that the liver is also a chemically reactant pool of cells that have a high rate of metabolism, sharing substrates and energy from one metabolic system to another, processing and synthesizing multiple substances that are transported to other areas of the body, and performing myriad other metabolic functions<sup>9</sup>. Based on these varied functions it may be liable to injury particularly in situation of toxicity. It would therefore be expedient to investigate the effects of *C. zambesicus* on the liver of Swiss albino mice.

Recently we have found that ethanolic extract from the leaves of *C. zambesicus* have profertility property<sup>1</sup>. In order

to continue our investigations on the possible effect of *C. zambesicus* on body organs, we examine the histological effect of *C. zambesicus* on the liver of Swiss albino mice.

## Figure 1

Figure 1: The leaves of



## MATERIALS AND METHODS

### PLANT MATERIALS

The leaves of *Croton zambesicus* were procured from a local market in Ile-Ife, Osun-State, Nigeria. It was identified by

the Department of Botany, Igbiniedion University, Okada, Nigeria, where a voucher was deposited at the Herbarium. The leaves were oven dried at 40°C for 6 days and then grounded to a fine powder.

### **PREPARATION OF EXTRACT**

The powdered material (100g) was percolated with ethanol. The extract obtained yield (26.27%) was partitioned between dichloromethane and water. The aqueous fraction was concentrated in vacuum at 20°C (yield 3.98%). The fraction was dissolved in normal saline and administered orally at a dose of 5mg/kg and 10mg/kg as the plant extract for a period of five consecutive days.

### **ANIMAL TREATMENT**

Fifteen Swiss male albino mice (27-30g) were used for the experiment. They were maintained under standard laboratory conditions in the Animal Holdings of Igbiniedion University, Okada, Nigeria, and fed with standard pelleted diet and water ad libitum. The animals were randomly assigned into groups A, B and C (n=5). Groups B and C were administered with 5 and 10mg/kg doses of the extract; an equivalent volume of normal saline was given to group A (control group) for five consecutive days. All experimental procedures followed the recommendations provided in the "Guide for the Care and Use of Laboratory Animals" (National Academy Press, 1996)

### **HISTOLOGICAL PROCEDURE**

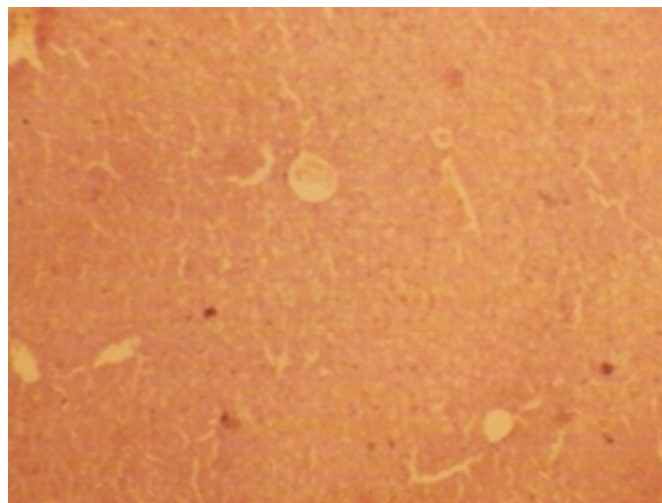
Histological examination was done by fixing the organs of the mice in 10% formal saline, processed and embedded in paraffin wax. Tissue blocks were sectioned 5 µm thick and stained with Haematoxylin and Eosin (H & E).

### **RESULTS**

The treatment and control sections of the liver showed normal histological features with the hepatic lobules showing polyhedral three-dimensional shape. Sinusoids originate at the lobule margin and course between plates of hepatocytes to converge upon the terminal hepatic venule. The lobules were also seen to be bounded by thin septa of collagenous supporting tissue. (Figure 2, 3 & 4).

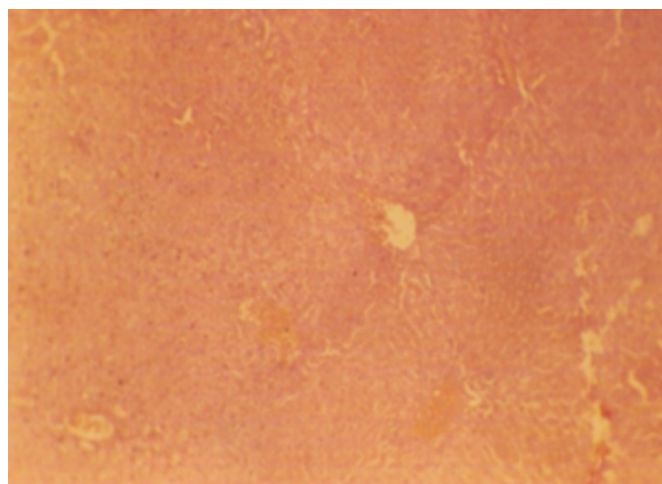
**Figure 2**

Figure 2: Photomicrograph of the liver of group A (control) (Mag. x100)



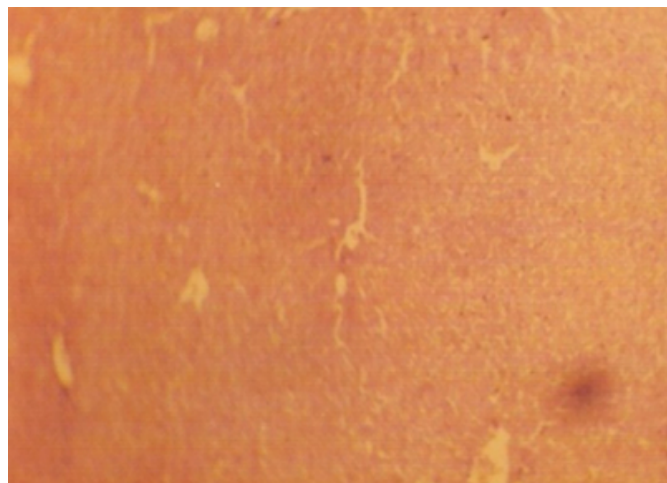**Figure 3**

Figure 3: Photomicrograph of the liver of group B (Mag. x100)



**Figure 4**

Figure 4: Photomicrograph of the liver of group C (Mag. x100)



**DISCUSSION**

Our histological findings revealed that there was no distortion on the cyto-architecture of the liver parenchyma both in the treated and control groups. This confirms that consumption of *C. zambesicus* is safe for the liver which is the first organ susceptible to any injurious substances in case of toxicity. This investigation further buttresses a similar work by Abo et al<sub>3</sub> which confirmed in their work- Antimicrobial potential of *Spondias mombin*, *Croton zambesicus* and *Zygotritonia crocea*, that there is justification for the use of these medicinal plants as anti-infective agents in traditional medicine. It may be inferred from the present study that even at higher dosage (10mg) *C. zambesicus* does not cause any degenerative or atrophic changes in the liver cells. The hepatic lobules which are polyhedral three-dimensional in shape were well preserved. The actual mechanism by which *C. zambesicus* performs their functions is still unknown but may be due to their high flavonoids content<sub>10,11</sub>. Flavonoids, alkaloids and tannins have been associated with antimicrobial effects in various studies using plant extracts<sub>3</sub>. In *Garcinia kola*, flavonoid has been screened to have antioxidant property<sub>12,13</sub>. This antioxidant which is expected to be active in the flavonoid isolated in the leaves of *C. zambesicus* may have acted on the liver tissue by scavenging natural free radicals which involves the donation of electron<sub>14</sub>.

Chemosuppressant potential of *C. zambesicus* can be further studied extensively to ascertain its extension in the management of some liver diseases.

The present investigation justifies that intake of ethanolic

extract of *C. zambesicus* have no lethal effects on the liver of Swiss albino mice.

**ACKNOWLEDGEMENT**

The authors are in deed very grateful for the technical assistance of E. Gbela of the Department of Morbid Anatomy and Forensic Medicine, Obafemi Awolowo University, Ile-Ife, Nigeria.

**References**

1. Ofusori DA, Oluwayinka OP, Adelakun AE, Keji ST, Oluyemi KA, Adesanya OA, Ajeigbe KO and Ayoka AO. (2007). Evaluation of the effect of ethanolic extract of *Croton zambesicus* on the testes of Swiss albino mice. *Afri. J. Biotechnol* Vol. 6 (21), pp. 2434-2438.
2. Okokon JE, Iyadi KC, Effiong CO (2004). Effect of sub chronic administration of ethanolic leaf extract of *croton zambesicus* on hematological parameters of rats. *Nigerian Journal of Physiological Sciences*, Vol. 19, No. 1-2, pp. 10-13.
3. Abo KA, Ogunleye VO and Ashidi JS (1999). Antimicrobial potential of *Spondias mombin*, *Croton zambesicus* and *Zygotritonia crocea*. *Phytother Res.* 1999 Sep; 13(6):494-7.
4. Watt JM and Breyer-Brandwijk MG. (1962). *The Medicinal and Poisonous Plants of Southern and Eastern Africa*, second ed. E. and S. Livingstone Ltd., London, UK.
5. Adjanohoun, EJ, Adjakidje, V, de Souza, S. (1989). *Contribution aux E'tudes Ethnobotaniques et Floristiques en Re'publique Populaire du Be'nin*, Vol. 1. Agence de Coope'ration Culturelle et Technique, Paris, pp. 245.
6. Block S, Baccelli C, Tinant B, Van Meervelt L, Rozenberg R, Habib Jiwan J, Llabre`se G, De Pauw-Gillet M, Quetin-Leclercq J. (2004). Diterpenes from the leaves of *Croton zambesicus*. *Phytochemistry* 65: 1165-1171.
7. Matthews HB, Lucier GW, Fisher KD. (1999) Medicinal herbs in the United States: Research Needs. *Environ. Health Perspect.* 107, 773-778.
8. Heath JW, Young B and Burkitt HG (1999). Liver and pancreas. *Wheater's functional histology* 3rd ed pg 271-275.
9. Guyton AC, Hall JC (2000). *Textbook of Medical Physiology* 10th Edn.,
10. B. Saunders Company. Philadelphia. Pennsylvania, pp. 797-799.
11. Nweze EI, Okafor JI, Njoku O (2004). Antimicrobial Activities of Methanolic Extract of *Trume guineesis* (schumm and thorn) and *Morinda lucinda* Benth used in Nigerian Herbal Medicinal Practice. *J. Biol. Res. Biotechnol.* 2(1): 34-46.
12. Corthout J, Pieters LA, Claeys M, Vanden Berghe DA, Vlietinck AJ (1991). Antiviral ellagitannins from *Spondias mombin*. *Phytochem.* 30(4): 1129-1130.
13. Iwu MM and Igboko OA (1982). Flavonoids of *Garcinia kola* seeds. *J. Natural Prod*; 45: 650-651.
14. Akpantah AO, Olabiyi OA, Oremosu AA, Noronha CC, Okanlawon AO (2006). Assessment of the antioxidant potential of alcoholic extract of *Garcinia kola* seed in alcohol induced testicular oxidative stress in Spague-Dawley rat. *Niger. J. Health Biomed. Sci.* 5(1): 37-42.
15. Mira L, Femandez M, Santos M, Rocha R, Florencio M, Jennings K. (2000). Interaction of flavonoids with iron and copper ions. A mechanism for their antioxidant activity. *Free Radical Research.* 36: 1199-1208.

**Author Information**

**D.A. Ofusori, M.Sc.**

Department of Anatomy, School of Basic Medical Sciences, Igbinedion University

**A.E. Adelakun, M.Sc.**

Department of Chemistry, Faculty of Science, University of Lagos

**A.O. Ayoka, MPhil**

Department of Physiological sciences, Faculty of Basic Medical Sciences, Obafemi Awolowo University

**J.A. Ibeh, NIST**

Department of Anatomy and Cell Biology, Faculty of Basic Medical Sciences, Obafemi Awolowo University

**A.O. Adeeyo, M.Sc.**

Department of Human Anatomy, Faculty of Basic Medical Sciences, Ladoke Akintola University

**A.O. Adesanya, MPhil**

Department of Anatomy, School of Basic Medical Sciences, Igbinedion University

**K.O. Ajeigbe, M.Sc.**

Department of Physiology, School of Basic Medical Sciences, Igbinedion University