

# Signet Ring Cell Carcinoma Of The Ileum – A Case Report And Review Of Literature

J Deuskar, P Joshi, U Adbe, A Railkar

## Citation

J Deuskar, P Joshi, U Adbe, A Railkar. *Signet Ring Cell Carcinoma Of The Ileum – A Case Report And Review Of Literature*. The Internet Journal of Surgery. 2009 Volume 25 Number 1.

## Abstract

A 17-year-old female presented with signs of subacute intestinal obstruction, was investigated and found to have a terminal small-bowel stricture. She was put on empirical AKT along with steroids, but there was no improvement. She was posted for elective laparoscopy to rule out Crohn's/Koch's disease. Laparoscopically assisted right hemicolectomy was done for terminal ileum stricture. The specimen showed a firm to hard stenotic terminal ileum. Histopathology revealed the diagnosis of signet ring cell carcinoma.

## INTRODUCTION

The small bowel rarely develops neoplasms. The majority of them are found in the colon or stomach. Malignant tumors of the small intestine are rare, most of them being adenocarcinomas, and are more common in the duodenum. These adenocarcinomas are well to moderately differentiated. Signet ring cell carcinomas are a rare variant of small bowel tumor. We present a case report of a young patient who suffered from signet cell carcinoma of the small bowel.

## CASE REPORT

A 17-year-old female was admitted with complaints of colicky abdominal pain, abdominal distension and episodes of bilious vomiting.

She was managed conservatively, as she refused all investigations.

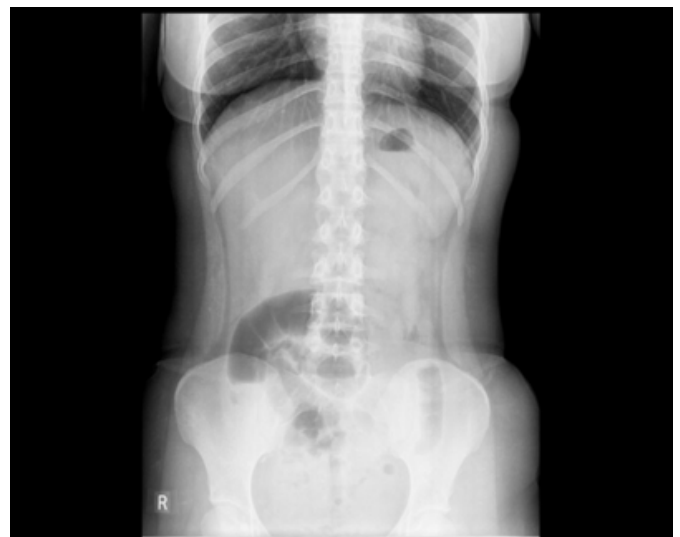She came back to us with no relief of symptoms.

She was then investigated at our hospital.

X-ray of the abdomen (standing)

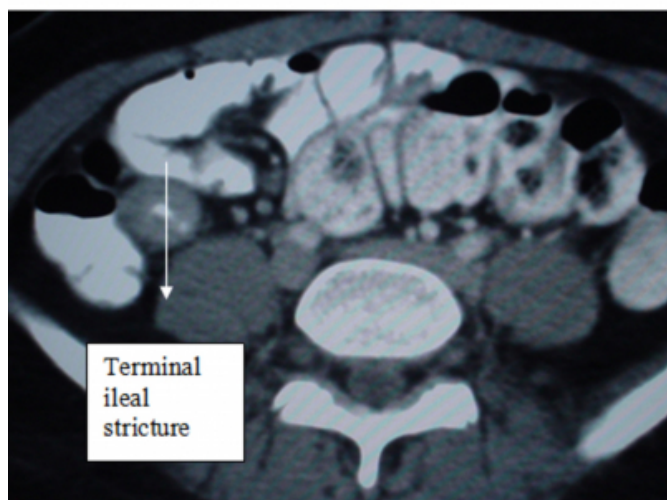
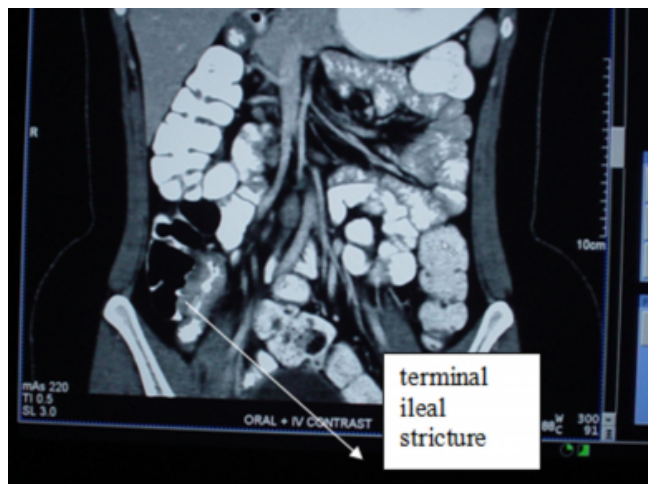
## Figure 1

Figure 1: Air-fluid levels



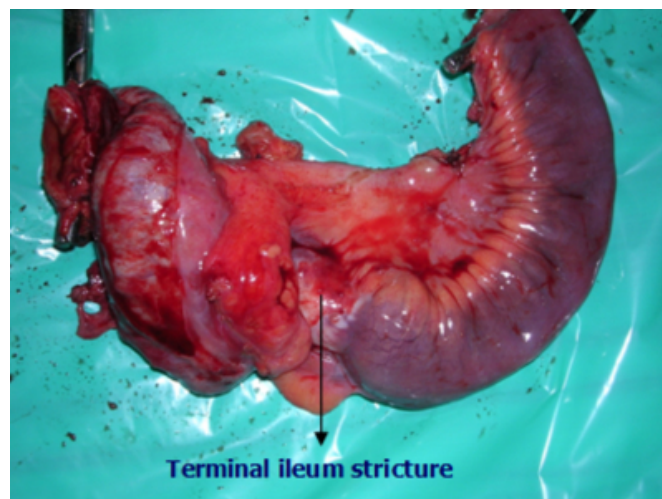
**Figure 2**

CT scan of abdomen & pelvis



A 7cm stricture at the terminal ileum was found and a laparoscopically assisted right hemicolectomy was done.

**Figure 3**



The postoperative period was uneventful.

### **SURGICAL PATHOLOGY REPORT**

Signet ring cell carcinoma of the ileocaecal junction with infiltration into muscle coat, serosa and peri-ileal adipose tissue.

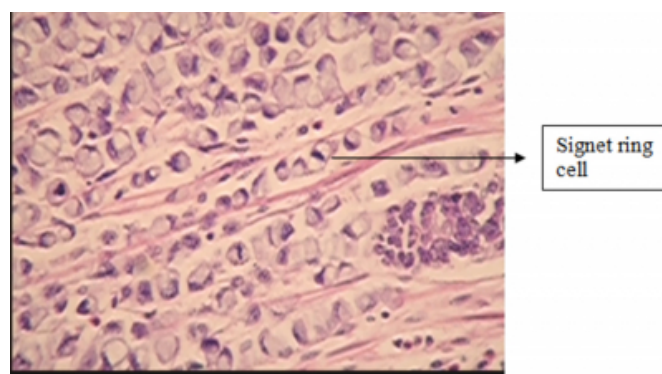
Metastasis to lymphnodes.

Ends of resection free of tumor.

Stage III, pT3N1M0.

Histologic grade: G3.

**Figure 4**



### **DISCUSSION**

Small-bowel tumors account for less than 10% of G.I. tumors and 64% of small-bowel tumors are malignant, with adenocarcinoma accounting for 40%. The survival rate is poor (20-30% at 5years).

Signet ring cell carcinoma is an epithelial malignancy characterized by the histologic appearance of signet ring

cells. The name of the cell comes from its appearance; signet ring cells resemble signet rings. They contain a large amount of mucin, which pushes the nucleus to the cell periphery. The pool of mucin in a signet ring cell mimics the appearance of a finger hole and the nucleus mimics the appearance of the face of the ring in profile.

Signet cell carcinoma has been reported in the jejunum<sup>(1)</sup>, but there is only one reported case of signet ring cell carcinoma of the ileum, and that in an elderly female<sup>(2)</sup>. Here, we report an unusual case of signet ring cell carcinoma in a young female.

### **CONCLUSION**

Small-intestinal malignancies are extremely rare. They account for 0.1 to 0.3% of all malignancies with slight male predominance. They are very rare before the age of 30.

This patient presented with signs and symptoms of small-bowel obstruction. In India, malignancy is an extremely rare cause of small-bowel obstruction, especially at an early age. In most cases, it may be attributed to adhesive intestinal

obstruction or to tuberculosis, as happened in this case.

Thus, a high index of suspicion, early specific investigations and timely surgical intervention would result in a curative management of such rare disease.

Laparoscopically assisted surgery is a good modality of treatment. Early postoperative recovery, better quality of life and cosmesis are important in this patient.

We hereby report a rare case of signet cell carcinoma of the ileum in a young female. Our literature search reveals that this is the second known case of ileal signet ring cell carcinoma.

### **References**

1. Yamagami H, Oshitani N, Suekane T, Aomatsu K, Kamata N, Sogawa M, Watanabe K, Noda E, Ikura Y, Maeda K, Hirakawa K, Arakawa T: Signet-ring cell carcinoma of the jejunum diagnosed by double balloon enteroscopy. *Hepatogastroenterology*; 2008; 55(85): 1246-8.
2. Iizawa H, Ikeda E, Sato T, Ohta Y: Signet-ring cell carcinoma of the ileum: report of a case and review of the Japanese literature. *Surg Today*; 1998; 28(11): 1168-71.

**Author Information**

**Jitendra Deuskar, MS**

Department of Surgery Deenanath Mangeshkar Hospital & Research Centren India

**Pankaj Joshi**

**Umesh Adbe, DNB(Surgery)**

Department of Surgery Deenanath Mangeshkar Hospital & Research Centre

**Amruta Railkar**

DNB Traineeee, Department of Surgery Deenanath Mangeshkar Hospital & Research Centre