Intravascular Endometrium Mimicking Vascular Invasion

A Papanicolau, G Lin

Citation

A Papanicolau, G Lin. *Intravascular Endometrium Mimicking Vascular Invasion*. The Internet Journal of Pathology. 2010 Volume 12 Number 1.

Abstract

Intravascular endometrium (IEM) is a rare finding that can pose a significant diagnostic dilemma, especially in cases of known carcinoma where the possibility of vascular invasion must be entertained. The distinction between IEM and intravascular invasion of malignancy can be made based on histologic findings and immunohistochemical profile. We report a case of IEM in a hysterectomy specimen removed from a 38 year old patient with invasive cervical adenocarcinoma and adenomyosis. Histologically, the lumen and intima of large muscular vessels contained well-developed glands with high nuclear to cytoplasmic ratio and endometrial stroma with spindled nuclei associated with hemorrhage and hemosiderin-laden macrophages. By immunohistochemistry, the benign glands within vascular spaces were positive for vimentin, ER and PR, but only rare cells were positive for p16. The stroma surrounding the intravascular glands was positive for CD10. These results confirmed the presence of IEM. The presence of IEM may be confused with vascular invasion which may affect staging and treatment of the patient.

INTRODUCTION

Endometrial tissue found within the myometrial vessels during menstruation is an uncommon, benign finding which was initially described by Sampson in 1927.[1] Subsequently, there have been reports of endometrial tissue in myometrial vessels that was not associated with menstruation, although all of these cases were found in association with extensive, and frequently multifocal, adenomyosis.[2] A case of cervical dysplasia in association with intravascular menstrual endometrium has also been reported.[3] We are not aware of literature describing IEM in association with invasive adenocarcinoma. We present a case of IEM, not associated with menstruation, in a hysterectomy specimen removed from a patient with invasive cervical adenocarcinoma. We discuss the histologic and immunohistochemical findings used to distinguish between vascular invasion of cervical adenocarcinoma and IEM.

MATERIALS AND METHODS

This case is from the surgical pathology files of the Department of Pathology of the University of California San Diego Medical Center (San Diego, California). Tissue sections were formalin-fixed, embedded in paraffin and stained with hematoxylin-eosin (H&E). Four µm thick, formalin-fixed, paraffin-embedded tissue sections were stained with ER, PR, CD10, p16, or vimentin (Table 1).

CLINICAL HISTORY

At the time of initial evaluation, the patient was a 38 year old nulligravida with a prior history of iron deficiency anemia, depression, gastric bypass and abdominoplasty. There was no prior history of malignancy. She had an unremarkable physical exam. On a routine cervical Papanicolau screen, she was diagnosed with cervical adenocarcinoma in situ (AIS). A subsequent cervical biopsy and endocervical curettage confirmed the diagnosis. The endometrial biopsy was negative for malignancy. A cervical cone biopsy was done, which was consistent with invasive cervical adenocarcinoma with a background of AIS and focal squamous dysplasia. Repeat endocervical curettage and endometrial biopsy at the time were negative for malignancy. A radical hysterectomy and pelvic lymphadenectomy were then performed. The patient is doing well two years after the operation.

RESULTS

The initial pap screen, cervical biopsy and endocervical curretings were diagnosed as AIS without vascular invasion but with a suspicion of stromal invasion due to the unoriented specimens. The cone biopsy demonstrated invasive, well differentiated adenocarcinoma (Fig 1A) with a depth of invasion of 4.5 mm, and maximum length of 9 mm. The adenocarcinoma cells were hyperchromatic with crowding, architectural complexity and loss of polarity. No vascular invasion was detected and margins were negative.

The cervix of the hysterectomy specimen measured 2.6 cm in diameter and no gross tumors were seen. On microscopic examination, there was focal residual adenocarcinoma in situ with widely clear margins. There was adenomyosis in the context of benign secretory endometrium (not shown). In sections of the cervix and parametrium, several large muscular vessels were found to contain glands with surrounding spindled stromal cells which involved the endothelium (Fig 1D-I). The glandular component in the vessels consisted of a single layer of columnar or cuboidal cells with high nuclear to cytoplasmic ratio. The nuclei were oval shaped and no mitotic figures were appreciated. The bulk of the stromal component was distributed in an eccentric fashion and had indistinct cellular borders with fusiform or plump nuclei. This stroma was disrupted by groups of red blood cells which extended into the media of the vessel (Fig 1D-I). The vessels had a very thick muscular media layer that was focally disrupted by stroma, hemorrhage, and fibrous amorphous material, which was occasionally associated with hemosiderin laden macrophages.

In addition, three lymph nodes were found to contain glands within the subcapsular sinuses (Fig 1B-C). The epithelium of the glands showed minimal cytologic atypia and was focally ciliated. No mitotic figures or necrosis were noted. Pelvic washings were negative.

The combined finding of glands within the cervical parametrial vessels and within the lymph node sinuses raised the possibility of vascular space invasion and lymph node metastasis. Immunohistochemical stains were performed to identify the source of the intravascular glands and stroma. P16 was positive in the cervical adenocarcinoma and showed rare positive cells in the intravascular glands (Fig 2A and 2B). The cervical adenocarcinoma was CD10 negative while the stromal component of the intravascular tissue was positive, and the glandular component was negative (Fig 2C and 2D). Both ER and PR were negative in the adenocarcinoma, while they were positive in both the intravascular glands and stroma (Fig 2E-H). Vimentin was negative in the cervical adenocarcinoma but focally positive in the glandular component and strongly positive in the surrounding stroma (Fig 2I and J).

Figure 1

Table 1

Antibody	Source	Catalogue No.	Dilution	Fixation
ER	DAKO	# M7047	1:100	10% formalin
PR	DAKO	# M3569	1:300	10% formalin
CD10	LABVISION	# MS-728-S	1:60	10% formalin
p16	SANTA CRUZ BIOTECH	# SC-56330	1:100	10% formalin
Vimentin	ZYMED	# 18-0052	1:800	10% formalin

Figure 2

Figure 1. A: Cervical adenocarcinoma with crowding, loss of polarity, architectural complexity and hyperchromasia, 200x; B, E: intravascular endometrium composed of single layer of columnar or cuboidal cells with high nuclear to cytoplasmic ratio and associated stromal cells and hemorhage, 40x; C, F: intravascular endometrium, 100x; D, G: intravascular endometrium, 200x; H: Lymph node with endosalpingiosis, 200x.

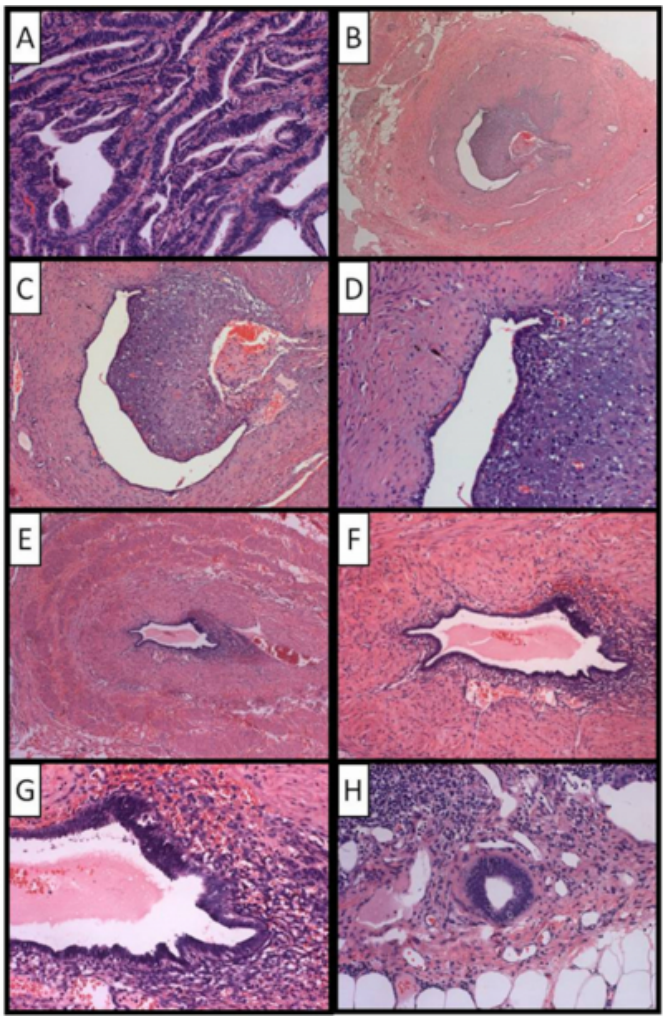

Figure 3

Figure 2. A comparison between the immunophenotypic profile of the cervical adenocarcinoma and the IEM. A and B: p16 is strongly and diffusely positive in the adenocarcinoma but only a few cells are positive in the IEM; C and D: CD10 stains the stroma but not the adenocarcinoma or IEM; E-H: ER shows nuclear positivity in most of the IEM epithelium and numerous IEM stromal cells but not in the adenocarcinoma. PR shows a similar pattern but with less prominent positivity. I and J: Vimentin shows membranous positivity in many IEM epithelial and stromal cells and is negative in the adenocarcinoma.

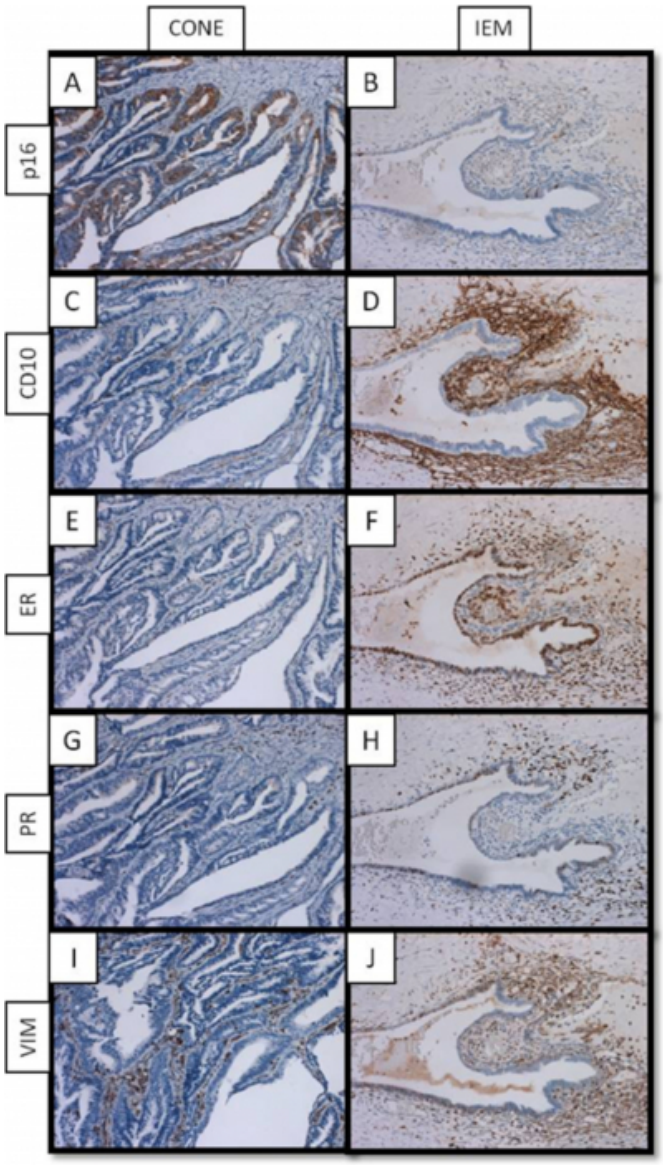

DISCUSSION

In this case of a patient with cervical adenocarcinoma, the presence of glands within parametrial vessels raised the possibility of vascular invasion. However, the intravascular glandular epithelium had bland cytologic features with no mitotic activity and associated with the glands were stromal spindle cells with hemorrhage, as well as focal hemosiderin deposition. These findings suggested that this intravascular tissue was endometrium. The concurrent presence of glands within the pelvic lymph nodes also raised the possibility of metastasis. These glands were lined by ciliated columnar cells with no atypia or mitoses, consistent with lymphatic endosalpingiosis.

To differentiate between the adenocarcinoma and IEM and to clarify the exact type of adenocarcinoma, we used a panel of antibodies to detect the cyclin dependent kinase p16, cell-surface neutral endopeptidase CD10, estrogen (ER) and progesterone (PR) nuclear hormone receptors, and the intermediate filament vimentin.[6-9]

P16 has been found to be positive in endocervical AIS and adenocarcinoma .[9, 10] In this case the cervical adenocarcinoma was strongly and diffusely positive for p16, whereas the intravascular glands and stroma were negative. This suggests that the intravascular glands did not originate from the adenocarcinoma of the cervix. CD10 is typically negative in endocervical adenocarcinoma and positive in endometrial stroma.[8, 11] The cervical adenocarcinoma and intravascular glandular epithelium were CD10 negative while the intravascular stromal component was strongly positive, further suggesting the endometrial origin of the intravascular tissue. ER and PR are positive in endometrial glands and stroma but are typically underexpressed in cervical adenocarcinomas.[7, 12] The intravascular glandular and stromal tissue in this case was positive for ER and PR, suggestive of endometrial tissue. Vimentin is positive in endometrium and negative in endocervix, including endocervical adenocarcinoma.[6] The adenocarcinoma indeed was negative, while the IEM demonstrated partial epithelial positivity. Overall, the histological and immunohistochemical findings are strongly supportive of benign, IEM, akin to typical endometriosis.

IEM was first described by Sampson.[1] He theorized that endometriosis may be secondary to dissemination of uterine mucosa into uterine vessels during menstruation. Others have also described IEM.[2-5] Adenomyosis seems to be associated with IEM. Sahin and colleagues looked at 14 non-menstrual uteri with IEM, all of which were associated with extensive adenomyosis which was frequently multifocal.[2] Eight cases of IEM had only stroma and six had both glands and stroma. Importantly, no uteri without adenomyosis were found to have IEM. Based on these findings, it has been suggested that intravascular menstrual endometrium may be

underreported.[3] In this case, the adenomyosis was also present.

In a previous case report of IEM, the differential diagnosis was analyzed based on the presence of the particular endometrial component (epithelium or stroma or both).[3] The presence of only one component can be more difficult to recognize as endometrium compared to biphasic tissue.[3] If only the stromal component is present, it could be confused with high grade carcinomas, stromal sarcoma, intravascular lymphomatosis, and necrotic tumor. The epithelial component alone can also be confused with carcinoma, such as the adenocarcinoma our patient had, or intravascular trophoblastic disease.[3] While morphologic correlation is very important, immunohistochemistry can also help us determine the primary site of the intravascular malignancy.

In conclusion, in the event of the discovery of IEM in the context of prior history of neoplasia, particularly adenocarcinoma, histological and immunohistochemical analysis should be done to determine whether the lesion is truly benign.

References

1. Sampson JA. Metastatic or embolic endometriosis, due to the menstrual dissemination of endometrial tissue into the venous circulation. Am J Pathol 1927;3:93-109.
2. Sahin AA, Silva EG, Landon G, Ordonez NG, Gershenson DM. Endometrial tissue in myometrial vessels not associated with menstruation. Int J Gynecol Pathol. 1989;8(2):139-46.
3. Banks ER, Mills SE, Frierson HF Jr. Uterine intravascular menstrual endometrium simulating malignancy. Am J Surg Pathol. 1991 Apr;15(4):407-12.
4. Javert CT. Observations on the pathology and spread of endometriosis based on the theory of benign metastasis. Am J Obstet Gynecol. 1951 Sep;62(3):477-87.
5. Kupryja□czyk J. Intravascular endometriosis with thrombosis in a patient with adenomyosis. Patol Pol. 1991;42(4):134-5.
6. Dabbs DJ, Geisinger KR, Norris HT. Intermediate filaments in endometrial and endocervical carcinomas. The diagnostic utility of vimentin patterns. Am J Surg Pathol. 1986 Aug;10(8):568-76.
7. Garcia E, Bouchard P, De Brux J, Berdah J, Frydman R, Schaison G, Milgrom E, Perrot-Applanat M. Use of immunocytochemistry of progesterone and estrogen receptors for endometrial dating. J Clin Endocrinol Metab. 1988 Jul;67(1):80-7.
8. McCluggage WG, Oliva E, Herrington CS, McBride H, Young RH. CD10 and calretinin staining of endocervical glandular lesions, endocervical stroma and endometrioid adenocarcinomas of the uterine corpus: CD10 positivity is characteristic of, but not specific for, mesonephric lesions and is not specific for endometrial stroma. Histopathology. 2003 Aug;43(2):144-50.
9. McCluggage WG. Immunohistochemistry as a diagnostic aid in cervical pathology. Pathology. 2007 Feb;39(1):97-111.
10. Cameron RI, Maxwell P, Jenkins D, McCluggage WG. Immunohistochemical staining with MIB1, bcl2 and p16 assists in the distinction of cervical glandular intraepithelial neoplasia from tubo-endometrial metaplasia, endometriosis and microglandular hyperplasia. Histopathology. 2002 Oct;41(4):313-21.
11. Chu P, Arber DA. Paraffin-section detection of CD10 in 505 nonhematopoietic neoplasms. Frequent expression in renal cell carcinoma and endometrial stromal sarcoma. Am J Clin Pathol. 2000 Mar;113(3):374-82.
12. Liang J, Mittal KR, Wei JJ, Yee H, Chiriboga L, Shukla P. Utility of p16INK4a, CEA, Ki67, P53 and ER/PR in the differential diagnosis of benign, premalignant, and malignant glandular lesions of the uterine cervix and their relationship with Silverberg scoring system for endocervical glandular lesions. Int J Gynecol Pathol. 2007 Jan;26(1):71-5.

Author Information

Antonios Papanicolau, M.D.
Department of PathologyDepartment of Pathology, University of California

Grace Y. Lin, M.D., Ph.D.
Department of Pathology, University of California