

# An Unusual Cause Of Seizures In A 10 Year Old

P Govindaraj, E Thomas, J Gnanapragasam

## Citation

P Govindaraj, E Thomas, J Gnanapragasam. *An Unusual Cause Of Seizures In A 10 Year Old*. The Internet Journal of Pediatrics and Neonatology. 2003 Volume 4 Number 1.

## Abstract

Seizures are a common problem in childhood. We report a 10 year old presenting with seizures caused by acute onset heart block. Although minor degrees of heart block can occur in acute myocarditis, presenting with Stokes Adams episodes because of complete heart block is extremely rare.

## CASE HISTORY

A previously healthy 10year old girl presented with 3 episodes of generalised tonic seizures, each lasting approximately half a minute, within a span of 2 hours. She recovered from each episode without intervention. Over the previous 4 days she had been unwell with vomiting, headache, fever and lethargy. Two weeks prior to this she had similar symptoms of vomiting, fever and lethargy, which settled with paracetamol. She had no past history of fits, faints or a slow heart rate.

On arrival at the casualty department, her pulse rate was 48 beats per minute. She was pale with a capillary refill time of 4 seconds; the liver was palpable 2 cm below the costal margin the respiratory rate of 40 per minute. There were no features of meningism and no signs of neurodefecit. She was resuscitated with a fluid bolus and given oxygen by facemask.

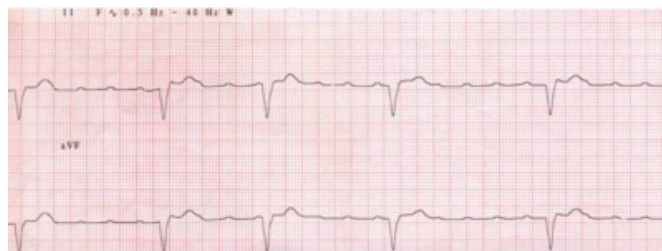
Electrocardiogram showed complete heart block with broad QRS complexes and a ventricular rate of 48 per minute. X-ray chest showed cardiomegaly and an echocardiogram showed moderate impairment of ventricular function with a fractional shortening of 22%, a mildly dilated left ventricle and a small pericardial effusion. She was started on an isoprenaline infusion and was transferred to the Regional Cardiac Centre.

Shortly after arrival at the regional centre, she had a short episode of abrupt slowing of the ventricular rate to 38 beats per minute (figure 1) which coincided with fainting and a generalised tonic seizure, which lasted less than a minute. As the convulsions were most likely to be Stokes Adams attacks related to a slow ventricular rate, a permanent endocardial

pacemaker was implanted transvenously. She was also started on captopril and diuretics.

## Figure 1

Figure 1: Rhythm strip showing complete heart block. Complete heart block-p waves and qrs complexes are independent of each other with broad qrs complexes with a ventricular rate of 38/mt.



The pacemaker was set in the VVI mode at a rate of 90 beats per minute. Five days later she reverted back to sinus rhythm with a prolonged PR interval. Subsequently the PR interval normalised. Twenty-four hour electrocardiogram was recorded with the pacemaker rate turned down and sinus rhythm without block was confirmed. Echocardiographic assessment of left ventricular function also improved over the next few days. She remained in stable sinus rhythm and the pacemaker was removed four months later.

Serology for coxsackie, enterovirus, Epstein Barr, adenovirus, mycoplasma, legionella and Lymes disease and throat swab and faeces for virus isolation were negative. Screening tests for metabolic disorders including serum carnitine, urine for organic and amino acids, thyroid function tests and autoimmune profile were also negative. Her creatinine phosphokinase (290 IU/L, normal 25-170) and troponin I (22.9 microgram/L, normal <0.15) levels were high indicating recent major myocardial damage.

## **DISCUSSION**

The differential diagnosis to be considered in a 10-year-old girl presenting with seizures include meningitis/encephalitis, head injury, epilepsy and drug toxicity. A low heart rate due to sinus bradycardia can be associated with seizures in the setting of raised intracranial pressures. Our patient presented with seizures and a low heart rate and was found to have complete heart block on ECG.

In the absence of congenital heart disease, complete heart block is usually due to maternal auto antibodies transferred to the fetus. Although most cases on congenital block present in infancy a significant number present in later childhood<sup>1</sup>. The subsequent resolution of heart block seen in our patient is not in keeping with congenital heart block.

Acute myocarditis is the most likely possibility. The preceding prodrome as well as the elevated creatinine phosphokinase and troponin I levels are compatible with this<sup>2</sup>. The most common cause of acute myocarditis is viral. Viral titres were negative in our patient but this is often the case in myocarditis. It is common to have minor degrees of heart block associated with myocarditis but complete heart block is rare<sup>3</sup>. Complete heart block can lead to Stokes-Adams seizures because of poor cerebral perfusion<sup>3,4</sup>. The reduced ventricular function may have also contributed to a

poor cardiac output in our case. The use of immunoglobulins and steroids has been reported in this setting but our patient responded well to pacing<sup>5</sup>.

Seizures are a common problem in childhood and being aware of unusual causes is important, as specific measures may be required in the management<sup>6</sup>.

## **References**

1. Eronen M. Long-term outcome of children with complete heart block diagnosed after the newborn period. *Paediatric Cardiology* 2001; 22: 133-7.
2. Levi D, Alejos J. Diagnosis and treatment of pediatric viral myocarditis. *Current Opinion in Cardiology* 2001;16: 77-83.
3. Wang JN, Tsai YC, Lee WL, Lin CS, Wu JM. Complete atrioventricular block following myocarditis in children. *Pediatric Cardiology* 2002; 23: 518-21.
4. Das Gupta R, Das MK, Mitra S, Tagore R, Lahiri D. Acute non-specific carditis in adolescents presenting with Stokes -Adams attacks. *Journal of the Association of Physicians of India* 1999; 47: 1195-7.
5. Hanawa H, Izumi T, Saito Y, Ochiai Y, Okura Y, Inomata T et al. Recovery from complete atrioventricular block caused by idiopathic giant cell myocarditis after corticosteroid therapy. *Japanese Circulation Journal* 1998; 62: 211-4.
6. Batmaz G, Villain E, Bonnet D, Iserin L, Fraisse A, Kachaner J. Therapy and prognosis of infectious complete heart block in children. *Archives des Maladies du Coeur et des Vaisseaux* 2000; 93: 553-7.

**Author Information**

**P.R. Govindaraj**

Southampton general hospital

**E. Thomas**

Southampton general hospital

**J.P. Gnanapragasam**

Southampton general hospital