

Osteogenesis imperfecta: A Report Of Two Cases

R Akinola, E Disu, O Adewole

Citation

R Akinola, E Disu, O Adewole. *Osteogenesis imperfecta: A Report Of Two Cases*. The Internet Journal of Pediatrics and Neonatology. 2007 Volume 8 Number 2.

Abstract

Background: The diagnosis of two cases of osteogenesis imperfecta, which is a rare form of congenital skeletal anomaly in a space of one month in this young tertiary institution inspired this write up. Medical records confirmed that no such cases have been reported for at least two years prior to this.

Case reports: Two Nigerian neonates diagnosed with osteogenesis imperfecta presented at the Lagos State University Teaching Hospital (LASUTH). At birth, they were found to be small for their gestational age. The heads were large while their limbs were deformed due to multiple fractures. They both had Osteogenesis imperfecta tarda (Type 11), which is the form that is associated with perinatal deaths^{1,2,3,4,5,6}.

Conclusion: Osteogenesis imperfecta though rare, occurs in our environment. More attention has to be paid to antenatal diagnosis of this pathology and postpartum clinical and radiological investigations to mitigate the suffering of these patients.

INTRODUCTION

Osteogenesis imperfecta or Brittle bone disease,^{4,5,6,7,8} is defined as a rare hereditary disorder, characterized by increased bone fragility, resulting from abnormal collagen formation^{2,4,5,6,7,8,9,10,11}. There are four clinical types, the hall mark of which is bone fragility⁵. Fractures, blue sclera and dentinogenesis imperfecta are associated findings^{6,7,8,9,10,11}. It is usually due to qualitative and quantitative defects in the synthesis of collagen type 1^{5,7,9,11}. It occurs in about 1:20,000-50,000 live births in developed countries^{4,9,10}. Osteogenesis imperfecta could be either recessive (severe) or dominant (mild).

CASE REPORTS

CASE 1

Baby AA, female, was born at 40weeks gestation by emergency caesarean section for unanticipated breech in labour. Mother was an unbooked 25 year old primipara, who had no hospital antenatal care. She denied family history of any skeletal abnormalities. Baby's father was a 35year old civil servant. Mother had no major illness and was relatively well during pregnancy. She routinely used daily herbal medicines throughout pregnancy. Baby cried immediately after birth, with an Apgar score of 7 and 9 at 1 and 5 minutes respectively.

Examination of the baby at four hours of life, revealed a small for gestational age baby, weighing 2kg, she was 41cm in length, below the third percentile for gestational age. She was pink, afebrile and not in respiratory distress. Her head however appeared disproportionately large, with occipitofrontal diameter of 34cm, normal for gestational age. Both lower and upper limbs were short, irregular and curved medially. Extra digits were present on the little fingers of both hands.

The central nervous system examination revealed a baby with good cry and normal neonatal reflexes. Both anterior and posterior fontanelles were palpable, soft, and the sutures were slightly widened.

There were no relevant abnormal findings on examination of the cardiovascular and gastrointestinal systems. A clinical diagnosis of osteogenesis imperfecta was made. Other investigations done included a skeletal survey, full blood count, PCV, WBC and differentials, electrolyte, urea, creatinine, serum calcium, phosphate and alkaline phosphatase (218 IU/L). Of these, only serum calcium and phosphate levels were low, at 1.76 mg/dl and 2.0mg/dl respectively.

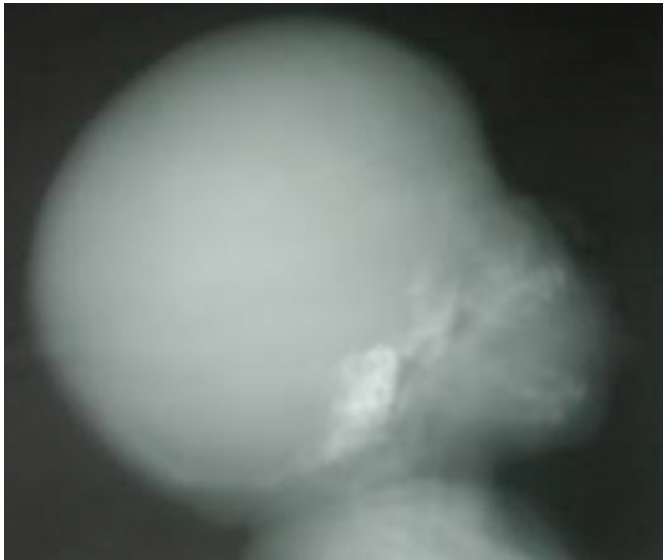
Radiographic examination confirmed the diagnosis of

osteogenesis imperfecta.

The x-ray of the skull showed bone rarification in almost all regions (Fig 1).

Figure 1

Figure 1: Lateral view of the Skull showing severe osteopenia and the skull vault is hardly demonstrated

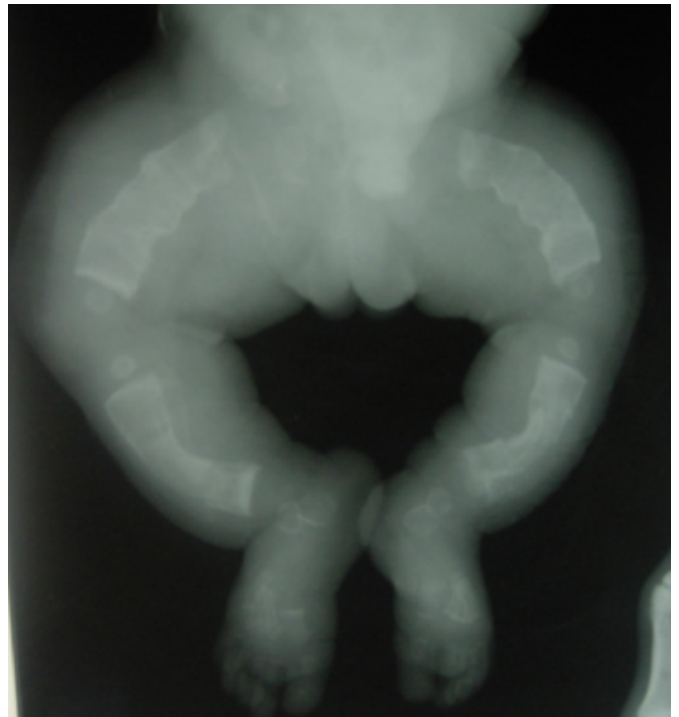


The rib cage appeared irregular especially on the left, with multiple fractures at different stages of healing.

Both upper and lower limbs show multiple fractures with excessive callus formation (Fig 2).

Figure 2

Figure 2: AP view of the lower limbs, showing Genu varum and multiple fractures in the femur, tibia and fibula



The long bone ends are flared and all of them appear short and irregular in outline. The distal long bones were bowed.

The spinal column was normal.

Follow up clinic two weeks later, showed the baby had developed bluish sclera. She was however lost to follow up.

CASE 2

Baby O, female, presented on the fourth day of life at the Neonatal out Patient clinic with abnormal, short limbs and an umbilical defect since birth. There was no known person with similar problem in the immediate extended family or past generation.

She was born at term by spontaneous vaginal delivery, at a private hospital. Antenatal care, which she attended sporadically, was at the same hospital. The mother had a febrile illness during the first trimester which was diagnosed as malaria. She was on herbal medication during pregnancy. Labour was uneventful. Baby cried immediately after birth, with an Apgar score of 8 and 9 at 1 and 5 minutes respectively.

At presentation, baby was active, afebrile, with quiet normal respiration. Birth weight was 2.2kg and head circumference was 31.0cm. Baby appeared abnormal with deformed limbs,

disproportionately short and curved upper and lower limbs.

Central Nervous System examination was normal with primitive neonatal reflexes intact. There were no abnormalities on examination of the respiratory and cardiovascular systems. The abdominal examination revealed a small defect on the right side of the umbilicus of 1.5x2.0cm, with herniation of the intestine. It was covered by a septic membrane, for which she had been receiving antibiotics.

A clinical diagnosis of Osteogenesis imperfecta with omphalocele was made.

Laboratory investigations including, full Blood count, PCV, WBC and differentials, blood film and electrolyte and urea were all normal. The ESR, serum calcium (10mg/dl), phosphate (8mg/dl) and alkaline phosphatase (266 IU/L) were normal.

Skeletal Survey showed severe generalized osteoporosis.

X-ray of the skull revealed a very thin vault which could hardly be differentiated from soft tissue.

X-ray of the chest, anteroposterior view revealed multiple rib fractures at different stages of healing, with excessive callus formation. The ribs therefore appeared irregular. Lung fields were clear and heart appeared normal.

There were multiple fractures in the upper and lower limbs long bones, with excessive callus formation and irregularity of their outlines (Fig 2).

An overlying soft tissue mass over the pelvis was consistent with the omphalocele.

DISCUSSION

In the cases presented, our findings are in agreement with those of previous authors, who believed that routine biochemical tests are usually normal^{4,5,10,12}. However, the first case had low serum calcium and phosphate levels.

Literature has reported that fractures result usually from minimal trauma¹⁰. The cause of multiple fractures in the “safe environment” of the uterus, is speculated to be a result of fetal movements in utero, or premature contractions, which the defective bone cannot withstand. Fractures are therefore, pathological fractures⁸ as they could not be attributed to birth trauma and thus diagnostic of the disease entity.

However, none of the two cases had dentinogenesis

imperfecta, but the blue sclera was demonstrated in only one of the babies, as a late presentation, as found by Bryan D.H.¹⁰ who claims that the sclera may be blue at birth and become less blue with age. Fairney A.¹² wrote that although blue sclera is a well documented clinical sign, it is not a reliable clinical feature in small babies.

Glorieux et al⁵ state that bone fragility and osteopenia, as we found, are the most prominent features of the disease.

The differential diagnosis include battered baby syndrome, the fractures of which are usually metaphyseal¹¹.

CONCLUSION

It is advised that neonates suspected to have osteogenesis imperfecta, should be examined clinically and radiographically to reduce perinatal deaths common in such disease entity.

References

1. Beighton P, Spranger J, Versveld G. Skeletal complications in osteogenesis imperfecta. A review of 153 South African patients. *S Afr Med J* 1983 64:565-8
2. Smith R, Francis MJO, Houghton GR In Brittle bone syndrome. Osteogenesis imperfecta. Butterworths, London 1983, 1st ed. p5.
3. Glorieux F.H, Rauch F, Plotkin H, Ward L, Travers R, Lalic L, et al. Type V Osteogenesis Imperfecta: A New form of Brittle Bone Disease. *J Bone Miner Res* 2000 15: 1650-1658
4. Akiode O, Ogunfowora OB, Shonubi A, Bajomo AA, Musa AA & Sotimehin SA Osteogenesis Imperfecta Congenita in a Nigerian baby. *SICOT Online Report* 2003 E049
5. Glorieux F.H, Ward L.M, Rauch F, Lalic L, Roughley P.J, et al Osteogenesis Imperfecta type VI: A form of brittle Bone Disease with a Mineralization Defect. *J Bone Miner. Res* 2002 17:30-38
6. Mundlos S., Chan D., Weng Y.M, Sillence D.O, Cole W.G et al. Multiexon Deletions in the Type 1 Collagen COL1A2 Gene in Osteogenesis Imperfecta Type 1B. *JBC Online* 1996, 271(15): 21068-21074
7. Jandl J.H. Hereditary disorders of connective tissue: Osteogenesis imperfecta In: Blood Textbook of Haematology 2nd ed. Little & Brown Company U.S.A 1996, p.1285
8. Rees M.M, Rodgers G.N. Hereditary disorders of connective tissue: Osteogenesis Imperfecta. In: Wintrabe's Clinical Haematology Vol.2 10th ed. Edited by Lippincott Williams and Wilkins. Walter Kluwer Company. Philadelphia U.S.A 1998. p1637
9. Engelbert RH, Puijls HE, Beemer FA, Helden PJ Osteogenesis Imperfecta in Childhood: treatment strategies. *Arch.Phys. Med.Rehabil.* 1998 79 (12) 1590-4
10. Bryan D.H. Inherited osteoporosis: Osteogenesis Imperfecta. In: Nelson Textbook of paediatrics. 15th ed. Edited by Behrman, Kliegman, Arvin .WB Saunders Philadelphia, U.S.A 1996. p.1978-1980
11. David Sutton, Textbook of Radiology and imaging, 7th ed. London. Churchill Livingstone 2003 p.72, 74, 411,423,476.

12. Fairney A. Metabolic Bone Disorders: Congenital disorders of the bone matrix- Osteogenesis Imperfecta, In : Postgraduate Textbook of Clinical Orthopedics edited by Nigel H. Harris. John Wright & Sons LTD. Massachusetts U.S.A Bristol England 1983 p311-2
13. Stevenson GH, Cuthbertson DP Blue sclera and associated defects. A study of four families with notes on mineral metabolism. Lancet (1931) 11: 732-8
14. Astley R. Metaphyseal fractures in osteogenesis imperfecta. Br J Radiol 1979 52: 441-3
15. Baily JA. Forms of dwarfism recognizable at birth. Clin Orthop (1971) 159: 171-6
16. Pryles CV, Khan AJ. Wormian bones. A marker of CNS abnormality. Am J Dis Children 1979 133:380-2
17. Shapiro F. Consequences of an osteogenesis imperfecta diagnosis for survival and ambulation. J Paediatric Orthop . 1986 5: 456-62
18. Key JA. Brittle bones and blue sclera. Hereditary hypoplasia of the mesenchyme. Arch. Surg. 1926 13:523-7

Author Information

Rachael Akinola, FWACS

Department of Radiology, Lagos State University College of Medicine

Elizabeth Disu, FMCPaed

Department of Paediatrics and Child Health, Lagos State University College of Medicine

Oladipo Adewole, FWACS

Department of Surgery (Orthopedics), Lagos State University College of Medicine