

Iatrogenic Gastric Perforation in a preterm infant: Clinical Presentation and radiological indicators

D Parasuraman, R Roy, S Mitchell

Citation

D Parasuraman, R Roy, S Mitchell. *Iatrogenic Gastric Perforation in a preterm infant: Clinical Presentation and radiological indicators*. The Internet Journal of Pediatrics and Neonatology. 2006 Volume 7 Number 1.

Abstract

We report an interesting case of a gastric perforation in a premature neonate which is a rare complication following insertion of a gavage feeding tube. A preterm infant of 28 week gestation was referred to our neonatal unit for presumed unresolving Necrotising Enterocolitis (NEC). An abdominal x ray revealed unusual position of the feeding tube and an ultrasound showed a spherical echogenic dense area in the peritoneal cavity. A laparotomy revealed a perforation of the lesser curvature of stomach which was repaired.

Gastric perforation in a neonate is a rare complication. The risk is higher among small, preterm infants and there is often an associated gavage feeding tube in situ. Gastric perforation must be distinguished from other causes of bowel perforation/ pneumoperitoneum including necrotising Enterocolitis (1,2). We report the case of a male infant of 28 weeks gestation presenting with recurrent episodes of acute abdominal distension due to gastric perforation.

CASE REPORT

A male infant, one of twins, was born at 28 weeks gestation with birth weight 965g. He initially made good progress and full enteral feeds of expressed breast milk (EBM) were established by day six of life at 180ml/kg/day. Later the same day, there was an acute clinical deterioration with marked abdominal distension requiring ventilatory support. Feeds were stopped and he was treated conservatively for presumed necrotising Enterocolitis (NEC) with broad spectrum antibiotics. His condition improved over the following week and he was extubated onto nasal continuous positive airway pressure (NCPAP). Feeds were re-established and he was tolerating full enteral feeds of EBM by Day 15 of life. On day 16 of life, there was a further acute clinical deterioration with marked abdominal distension requiring ventilatory support. Transfer was arranged to our unit for presumed recurrent NEC with probable bowel perforation.

An abdominal x ray carried out after admission (figure 1) showed an abnormal round shadow in the midline of the epigastrium that looked dense and was interpreted as showing intramural gas. A provisional diagnosis of recurrent Necrotising Enterocolitis was made and the baby was treated with broad spectrum antibiotics. The nasogastric tube was noted to be in an unorthodox position. Repeat X rays continued to show pneumatosis with no signs of resolution

following a long course (10days) of antibiotic treatment. There was no evidence of pneumoperitoneum on the X-ray films. He remained ventilator dependant with no improvement in clinical status and persistently raised inflammatory markers (C-reactive protein).

Figure 1

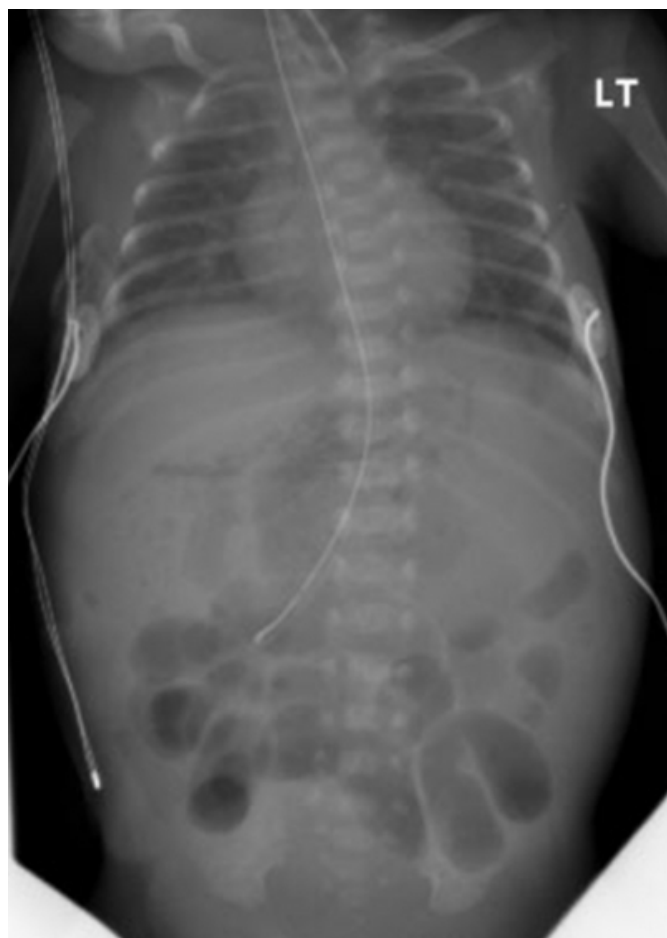
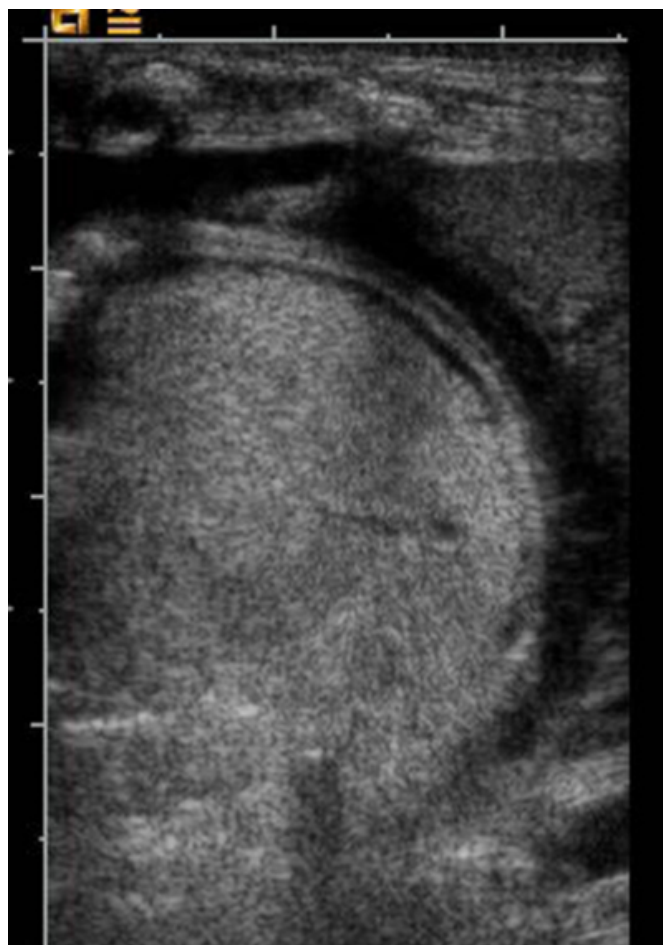

Figure 2



An ultrasound of the abdomen (figure 2) was carried out which revealed a dense, spherical and well circumscribed echogenic area lying within the peritoneum. A diagnosis of gastric perforation was made and the infant was prepared for surgery. At the time of laparotomy, copious milk curds were evacuated from the sub hepatic region. The liver and the bowels were noted to be covered in thick fibrin. There was no macroscopic evidence of NEC. A simple linear rupture of the cardia of the stomach was noted extending along the lesser curvature. The perforation was closed after a trans-anastigmatic tube was passed. There was no further leakage confirmed under direct inspection. Post-operatively, enteral feeds were withheld for five days, following which feeds were cautiously introduced using the transanastamotic tube. The infant made an uncomplicated recovery and was transferred back to the referring hospital (Day 35).

DISCUSSION

Gastric Perforation is a rare complication in neonates. Spontaneous gastric perforation involving the greater curvature of the stomach has been reported (¹). The aetiology of spontaneous gastric perforation in neonates is not always clear. Hypoxic-ischemic injury following an asphyxial insult and congenital defects in the muscle layer of the stomach wall has been suggested (⁴). Other causes include necrotising Enterocolitis of the stomach, lactobezoar causing obstruction and perforation in the stomach and iatrogenic perforation (⁵, ⁶).

Spontaneous gastric perforation is more common than iatrogenic perforation in neonates. Iatrogenic gastric perforation is uncommon, reported associations include aggressive use of bag-mask ventilation and perforation secondary to orogastric or nasogastric tube insertion (¹). The use of soft silastic feeding tubes instead of stiffer polyvinyl catheters may reduce the risk (⁷).

Abdominal distension is the most common clinical presentation. Presenting symptoms may also mimic NEC

with abdominal distension, gastrointestinal bleeding, erythema of the abdominal wall and increasing respiratory distress with signs of shock. Following a small perforation infant may appear clinically well and early diagnosis may be difficult with signs and symptoms of peritonitis lead to clinical deterioration.

Abdominal X-rays, including a left lateral decubitus view may demonstrate a pneumoperitoneum and abdominal ultrasound may show characteristic appearances with the absence of a gastric gas bubble in the fundus .

Definitive diagnosis in most cases is made at laparotomy.

Optimal management requires early diagnosis by maintaining a high index of suspicion and awareness of the condition. Gastric perforation carries a high mortality rate, particularly with delayed diagnosis and intervention.

Definitive surgical management consists of laparotomy and primary repair. In very sick infants, short term external peritoneal drainage may be required followed by formal surgical repair of the perforation once the infant's condition is stabilised.

In the case reported here, the unusual position of the nasogastric tube in the right upper quadrant, which is too vertical and deviates from its normal position in the stomach

provided the earliest indication of iatrogenic gastric perforation. Careful review of the feeding tube position may be a useful clinical sign for early diagnosis of this complication.

CORRESPONDENCE TO

Dr.D Parasuraman, C/o Dr SJ Mitchell, Neonatal Medical Unit, St.Mary's Hospital, Oxford road, Manchester M13 9WL, United Kingdom.

References

1. Rosser SB et al Spontaneous neonatal gastric perforation, J.Pediatric Surg 1982; 17:390-394
2. Borotta AP, Groff DB Gastrointestinal perforation in infants. American J Surg 1998; 155:447-452
3. St Vil D et al Neonatal gastrointestinal perforations. J Pediatr Surg 1992; 27(10):1340-1342
4. Meyer CL et al Spontaneous isolated intestinal perforations in neonates with birth weight less than 1000 grams not associated with Necrotising Enterocolitis. J Pediatric Surg 26:714-717 1991
5. Berkowitz GP, Buntain WL Milk curd obstruction Mimicking Necrotising Enterocolitis, Am J Dis Child 1980;134:989-990
6. Hall NJ, Ward HC, Lactobezoar with perforation in a premature infant, Biol Neonate 2005; 88:328-330
7. Fillipi L et al Use of polyvinyl tubes and iatrogenic pharyngeal oesophageal perforation in very- low birth weight infants. Acta Paediatrica 2005; 94:1825-1828

Author Information

Deepak Parasuraman, MRCPCH

Senior House officer, Department of Neonatology, St.Mary's Hospital

Rahul Roy, MRCPCH

Specialist Registrar, Department of Neonatology, St.Mary's Hospital

Simon Mitchell, FRCPCH

Consultant Neonatologist, St.Mary's Hospital