

# Herpes Zoster Oticus With Ménière's Syndrome Complex

R Meher, S Varshney, P Gupta, R Srivastava

## Citation

R Meher, S Varshney, P Gupta, R Srivastava. *Herpes Zoster Oticus With Ménière's Syndrome Complex*. The Internet Journal of Otorhinolaryngology. 2005 Volume 4 Number 2.

## Abstract

We discuss a case of herpes zoster oticus with Ménière's syndrome complex in a 27 year old male. The patient presented with herpes zoster oticus with varicelliform rash, facial nerve palsy and Ménière's syndrome complex type symptoms i.e. deafness, tinnitus, vertigo, nystagmus, nausea, and vomiting. Patient was managed medically and recovered with some residual facial palsy and sensorineural hearing loss. The aetiology, presentation and management in such cases is discussed in detail.

## INTRODUCTION

Ramsay Hunt's syndrome is an infectious cranial polyneuropathy caused by varicella zoster, the herpetic virus that also causes chickenpox and shingles. This syndrome usually affects multiple nerves, causing central, cervical, and peripheral effects. Clinically patients with Ramsay Hunt syndrome present with three major symptoms i.e. auricular vesicles, facial paralysis and vestibulo-cochlear dysfunction, although these symptoms did not always appear simultaneously. Sensorineural hearing loss is also reported in these patients. Severe form of Herpes Zoster can involve whole of the of the vestibulocochlear nerve along with facial nerve in its entire course producing picture like Ménière's syndrome. We here describe a patient who presented with symptoms similar to Ménière's syndrome complex i.e. deafness, tinnitus, vertigo, nystagmus, nausea, and vomiting along with herpetic rash.

## CASE REPORT

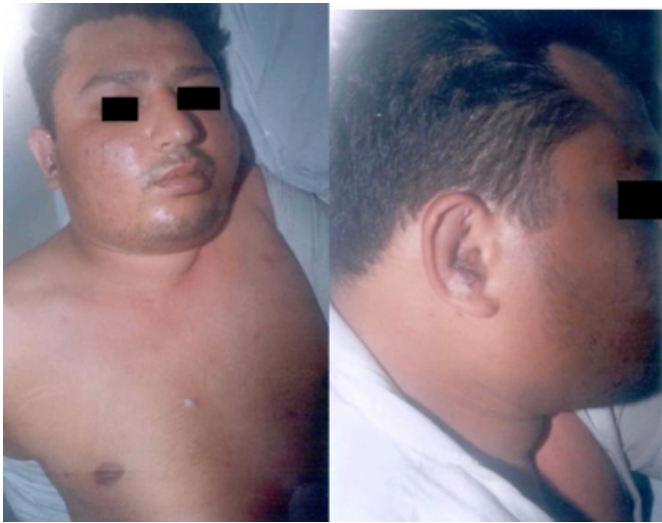A 27 year old male patient was admitted to the ENT OPD of Himalayan Institute of Medical Sciences with complaints of severe headache, otalgia, fever and vesicular lesions on the right ear canal and the pinna for five days. Patient had intractable vomiting and nausea at the time of admission. He did not give past history of chickenpox. On examination patient had erythematous swelling on his right ear canal and tender vesicles on the pinna with lower motor neuron facial nerve palsy which was of grade V on House Brackman scale. Rest of the cranial nerves and fundus examination were normal. Patient also had grade 3 nystagmus of horizontal type. The right tympanic membrane could not be seen because of inflammation of the ear canal. The left ear

was normal. Audiogram showed severe sensorineural hearing loss on the right side in high frequency. The picture thus resembled Ménière's syndrome complex.

There were no features suggestive of immunocompromised state. ELISA for HIV was non-reactive and other routine blood investigations including total leucocyte count, differential leucocyte count and random blood sugar were within normal limits. The patient was started on Tab acyclovir 800mg 5 times a day, injection hydrocortisone 200mg intravenous 8 hourly, injection paracetamol sos, and injection tramadol 8 hourly. For vertigo and vomiting injection prochlorperazine 5 mg intravenous was started. The patient still persisted with headache, vertigo, spontaneous nystagmus, photosensitivity and vomiting. He developed varicelliform rash on his face, trunk and tonsillar fauces. The patient continuously had tinnitus and vertigo, as well as decreased hearing. A gadolinium-enhanced magnetic resonance imaging (MRI) study showed enhancement of the right facial nerve and auditory nerve in its entire intratemporal course (fig2, 3). Two weeks after the treatment of the auricular vesicles, the lesions and otalgia were almost completely gone. He showed improvement in headache, vertigo, nausea and vomiting but had residual facial nerve weakness.

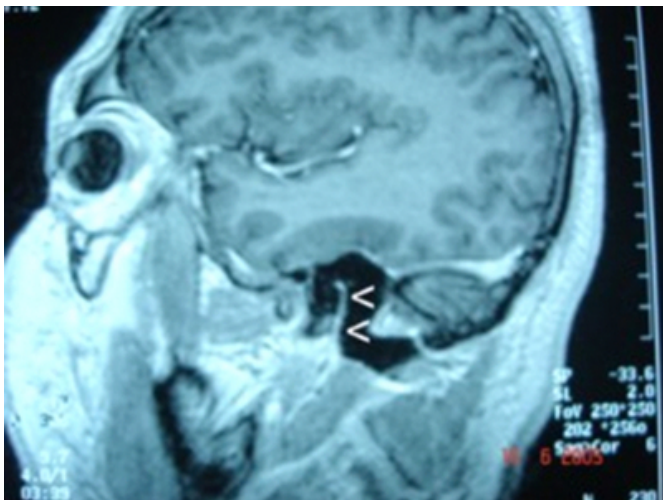
**Figure 1**

Figures 1 and 2: Clinical photograph of patient showing vesicular rash on right ear pinna, facial nerve palsy and varicelliform rash on the face and trunk.



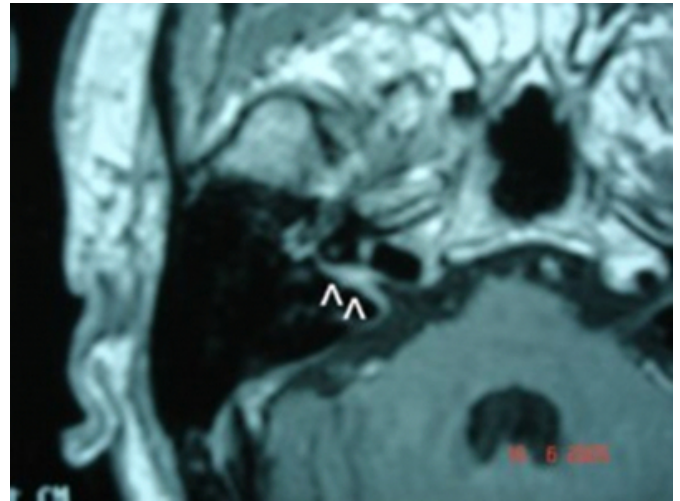
**Figure 2**

Figure 3: Parasagittal contrast enhanced MRI images demonstrating enhancement of mastoid segment of facial nerve (arrows).



**Figure 3**

Figure 4: Contrast enhanced axial MRI images demonstrating enhancement of right VII and VIII nerve in canalicular course (arrows).



## DISCUSSION

Herpes is derived from the Greek meaning, “to creep” and zoster “sword belt or girdle.” Ramsay Hunt(1907) was first to describe this as herpetic eruption associated with viral prodrome, severe otalgia, facial nerve dysfunction, vesicular eruption involving the pinna, and occasionally vestibulocochlear symptoms. Hunt classified herpes zoster at the cephalic extremity according to the sensory ganglion involved and the site of the rash into the following groups: (1) Geniculate herpes zoster (herpes oticus), (2) Gasserian herpes zoster (herpes facialis), and (3) Cervical herpes zoster (herpes occipito-collaris)

The varicella-zoster virus (VZV) belongs to the herpes family. It is a double-stranded DNA virus that causes chicken pox (varicella) and zoster infections. Again what distinguishes Varicella from Zoster is the time of presentation. Reactivation of virus stored in sensory ganglia (spiral and/or vestibular ganglion.) from previous varicella infection results in zoster. The first symptom usually is a deep, burning pain in the region of the ear followed by a vesicular eruption of the EAC and concha, or, less frequently, of the face, neck, trunk, palate or tonsillar fauces after around 1 to 4 days. The distribution of the vesicles depends on which sensory afferent fibers are involved by the viral eruption, but all the fibers may be involved, including cranial nerves V, IX, X and the cervical plexus arising from cervical roots II, III, IV. Cranial nerves VII and VIII are almost always involved. During the acute illness, a varicelliform rash often accompanies the painful vesicular eruption. A similar picture was found in the above case

where patient had involvement VII and VIII nerve with varicelliform rash on his face, trunk and fauces. Thus patient can have hearing loss, vertigo and tinnitus resembling Ménière's syndrome and it is the vesicular rash and facial nerve palsy, which gives an indication of herpes zoster. It is also important to differentiate it from Bell's palsy since it may occur without rash. In Bell's palsy only facial nerve is involved while in Ramsay Hunt syndrome cranial nerves both VII and VIII are almost always involved. Thus a diagnosis in patients with idiopathic facial nerve paralysis and hearing loss even when the characteristic vesicular eruption was absent can be made as Ramsay Hunt syndrome. Also Bell's palsy recurs in 10% -12% of cases, but herpes zoster oticus rarely recurs. In addition, the acute phase of the infection, as measured by electrical response and progression, peaks in 5 to 10 days with Bell's palsy, whereas herpes zoster oticus peaks in days 10 to 14. Finally, 84% of individuals with Bell's palsy have a satisfactory recovery of function, but only 60% of patients with herpes zoster oticus recover function.

Crabtree<sub>1</sub> (1968) was among the first to suggest that complete facial nerve recovery is less likely following herpes zoster oticus than in other cases of idiopathic facial palsy despite treatment with high dose steroids. Ten percent of patients with total facial nerve paralysis and 66 percent of those with partial paralysis recover completely. The timing of the appearance of the vesicular eruption may have prognostic significance. In most cases, eruption and paralysis occur simultaneously. In approximately 25% of cases, the eruption precedes the paralysis, and the likelihood of recovery is higher in this group (Devriese and Moesker<sub>2</sub>, 1988). Factors that appeared favorable for the recovery of hearing include not being older than 64 years, a mild initial hearing loss, a cochlear pattern of hearing loss, and absence of vertigo. Two percent of patients over age 50 will have severe, while nine percent will have moderate, post herpetic neuralgia.

The Tzanck preparation, which is useful with herpes zoster, located on the trunk in more peripheral nerve distribution areas, required toluidine blue staining a scraping from the blister. A positive preparation demonstrates multinucleated giant cells. The gold standard of laboratory diagnosis comprises PCR and direct identification of VZV in cell cultures. Detection of IgM- and IgA-anti VZV antibodies may be helpful in immunocompromised patients. Vesicular fluid, when present, can be cultured with human diploid fibroblasts and after 3-5 days multinucleated giant cells

within the fibroblast population can confirm clinical diagnosis. Laboratory confirmation of the diagnosis is based on increasing antibody titers in repeated complement fixation tests. Immunofluorescence of varicella antigen obtained from exfoliated cells from lesions can provide a more expedient verification of clinical suspicion. Often, diagnosis rests alone on the clinical examination.

Varicella zoster virus (VZV) causes varicella (chickenpox) remains dormant in dorsal root and cranial nerve ganglia and can be reactivated as a consequence of declining VZV specific cellular immunity leading to herpes zoster (shingles). The mechanism of reactivation of VZV in herpes zoster oticus has not been clarified, although deterioration of cell-mediated immunity is thought to play a specific role as the "trigger" in reactivating the virus.

MRI has been used in diagnosing Ramsay Hunt syndrome. Enhancement of the distal intrameatal and labyrinthine segments is specific for facial nerve palsy<sub>4</sub>. A moderate enhancement in the geniculate ganglion as well as in the labyrinthine segment correlated with a good prognosis with respect to restoration of facial movement while an increased enhancement correlated with poor prognosis. Yanagida<sub>3</sub> et al in 1993 noted that in subjects with Ramsay Hunt syndrome who experience internal auditory symptoms such as vertigo and tinnitus, enhancement was not only in the facial nerve but also in the vestibular and cochlear nerves. In our case also there was enhancement of right VII and VIII nerve in canicular and mastoid segment.

In the treatment of herpes zoster oticus, acyclovir therapy can be expected to improve facial nerve palsy upto House-Brackmann<sub>6</sub> grade I-III in most cases. In our case also patient had partial improvement in Facial nerve palsy from grade V to grade II. Absorption of Acyclovir from the GI tract is only 15% - 25% of the ingested dose. In addition, the blood-brain barrier results in a 50% reduction of circulating acyclovir into cerebrospinal fluid. For these reasons, the oral dose is more substantial than the recommended dose for herpes simplex. A recent randomized prospective clinical study Wood<sub>7</sub> et al compared 7-day treatment of acyclovir to two other treatment arms: 21 day course of acyclovir with and without prednisone. Neither additional treatment reduced the frequency of post-herpetic neuralgia. Valaciclovir is the L-valine ester of acyclovir and essentially an acyclovir prodrug. It is rapidly and almost completely converted to acyclovir in vivo. Valaciclovir (1000mg BD) requires less frequent dosing than acyclovir due to its

superior bioavailability over acyclovir. Systemic antiviral therapy is thus able to shorten the healing process of acute herpes zoster, prevent or alleviate pain and other acute and chronic complications, particularly, when given within 48 h to a maximum of 72 h after onset of the rash<sub>s</sub>. Some studies advocate the use of steroids along with acyclovir to reduce the incidence of post herpetic neuralgia and to enhance facial nerve recovery but should be avoided in immunocompromised or diabetic patients<sub>s</sub>.

### **CONCLUSION**

Severe form of Herpes zoster can involve whole of the of the vestibulocochlear nerve along with facial nerve in its entire course producing picture like Ménière's syndrome. Diagnosis in such cases can be made clinically supplemented by audiometry and MRI. Acyclovir therapy in cases of herpes zoster oticus is effective in control of disease and prevents the incidence of permanent facial palsy and treatment should be started early. Steroids reduce the incidence of post herpetic neuralgia and enhances facial nerve recovery.

### **References**

1. Crabtree JA. Herpes zoster and facial paralysis. *Otolaryngol Clin North Am* 1974; 7:369-373.
2. Devriese PP, Moesker WH. The natural history of facial paralysis in herpes zoster. *Clin Otolaryngol* 1988; 13:289-298.
3. Downie AC, Howlett DC, Koefman RJ, Banerjee AK, Tonge KA. Case report: prolonged contrast enhancement of the inner ear on magnetic resonance imaging in Ramsay Hunt syndrome. *Br J Radiol* 1994; 67:819-821
4. Kinoshita T, Ishii K, Okitsu T, Okudera T, Ogawa T. Facial nerve palsy: evaluation by contrast-enhanced MR imaging. *Clin Radiol*. 2001; 56(11): 926-32.
5. Yanagida M, Ushiro K, Yamashita T, Kumazawa T, Katoh T. Enhanced MRI in patients with Ramsay Hunt's Syndrome. *Acta Otolaryngol Suppl* 1993; 500:58-61.
6. House JW, Brackmann DE. Facial nerve grading system. *Otolaryngol Head Neck Surg* 1985; 93:146-147.
7. Wood MJ, Johnson RW, McKendrick MW, Taylor J, Mandal BK, Crooks J. A randomized trial of acyclovir for 7 days or 21 days with and without prednisone for treatment of acute herpes zoster. *N Engl J Med* 1994; 330:896-900.
8. Dickins JRE, Smith JT, Graham SS. Herpes zoster oticus: treatment with intravenous acyclovir. *Laryngoscope* 1988; 98:776-779.
9. Syal R, Tyagi I, Goyal A. Bilateral Ramsay Hunt syndrome in a diabetic patient. *BMC Ear Nose Throat Disord*. 2004 Dec 2; 4(1):3.

**Author Information**

**Ravi Meher**

Assistant Professor, Department of ENT & Head and Neck surgery,, Himalayan Institute Of Medical Sciences

**Saurabh Varshney**

Professor, Department of ENT & Head and Neck surgery,, Himalayan Institute Of Medical Sciences

**Pratima Gupta**

Associate Professor, Department of Microbiology, Himalayan Institute Of Medical Sciences

**R. K. Srivastava**

Assistant Professor, Department of Radiology, Himalayan Institute Of Medical Sciences