

# Oculomotor nerve: Clinical anatomy

G Milanes-Rodriguez, L Ibañez-Valdés, H Foyaca-Sibat

## Citation

G Milanes-Rodriguez, L Ibañez-Valdés, H Foyaca-Sibat. *Oculomotor nerve: Clinical anatomy*. The Internet Journal of Neurology. 2007 Volume 10 Number 1.

## Abstract

In this article, we illustrate and briefly describe a medial approach, in the sagittally sectioned preserved human brain, to display the oculomotor nerve, in situ and in continuity. The method has been successfully used by Milanes-Rodriguez for several cohorts of our second-year medical students, and can be completed within a 90-min dissecting session. We also review the most common clinical manifestation of oculomotor disorder

## INTRODUCTION

Despite congenital anomaly of oculomotor nerve is a rare condition some reports about oculomotor disorders due to nerve fenestration [1,2,3], abnormal course [4], hypoplasia in congenital fibrosis of the extraocular muscles [5,6,7], in Duane-Radial Ray Syndrome [8] in congenital extraocular muscle misinnervation [9], among others have been published [10,11,12,13,14]

The third, fourth, and sixth cranial nerves innervate the extraocular muscles that position the globes in the orbits. Extraocular muscle paralysis resulting from destructive lesions in one or all of these cranial nerves results in failure of one or both eyes to rotate in concert with the other eye.

CN III is the only cranial nerve with a subnuclear complex that arises in the dorsal mesencephalon at the level of the superior colliculus. Fascicles pass through the parenchyma of the midbrain via the red nucleus and corticospinal tract. They exit the mesencephalon and emerge into the subarachnoid space between the cerebral peduncles.

The primary symptom is diplopia from misalignment of the visual axes, and the pattern of image separation is the key to diagnosing which particular cranial nerve (and extraocular muscle) is involved. With unilateral third cranial nerve palsy, the involved eye usually is deviated down and out (infraducted, abducted), and there is ptosis, which may be severe enough to cover the pupil. In addition, pupillary dilatation can cause symptomatic glare in bright light (if the ptotic lid does not cover the pupil), and paralysis of accommodation causes blurred vision for near objects [12,15,16,17,18].

The oculomotor nerve arises from the anterior aspect of mesencephalon (midbrain). There are two nuclei for the oculomotor nerve:

- The oculomotor nucleus originates at the level of the superior colliculus. The muscles it controls are the ciliary muscle (affecting accommodation), and all extraocular muscles except for the superior oblique muscle and the lateral rectus muscle.
- The Edinger-Westphal nucleus supplies parasympathetic fibres to the eye via the ciliary ganglion, and thus controls pupil constriction.

On emerging from the brain, the nerve is invested with a sheath of pia mater, and enclosed in a prolongation from the arachnoid.

It passes between the superior cerebellar (below) and posterior cerebral arteries (above), and then pierces the dura mater in front of and lateral to the posterior clinoid process, passing between the free and attached borders of the tentorium cerebelli.

It runs along the lateral wall of the cavernous sinus, above the other orbital nerves, receiving in its course one or two filaments from the cavernous plexus of the sympathetic, and a communicating branch from the ophthalmic division of the trigeminal.

It then divides into two branches, which enter the orbit through the superior orbital fissure, between the two heads of the lateral rectus.

Here the nerve is placed below the trochlear nerve and the frontal and lacrimal branches of the ophthalmic nerve, while the nasociliary nerve is placed between its two rami:

- superior branch of oculomotor nerve
- inferior branch of oculomotor nerve

As mentioned before the oculomotor nerve or cranial nerve number III is one of the cranial nerve that together with the trochlear (IV) and abducent (VI) supplies the extra ocular muscles that position the globes in the orbital cavity.

Extraocular muscles paralysis result in failure of one eye to rotate in concert with the other producing misalignment of the visual axis with the resulting diplopia as a primary symptom<sup>[19,20,21,22]</sup>.

These two motor nuclei of origin located in each side of the midbrain tegmentum, under the cerebral aqueduct at the level of the superior colliculi as can be seen in Figure 1

The oculomotor nucleus: The axons of this nucleus contain somatic efferent fibers that supply the following muscles:

- Levator palpebrae superioris (elevates the upper eyelid)
- Superior, medial and inferior rectus and inferior oblique (all act on the eyeball)

Course of the nerve:

The nerve travels through the following parts:

1. Intraparenchymal midbrain part: The axons of the cell bodies course ventrally in close relation with the red nucleus and exit from the midbrain at the medial side of the cerebral peduncle. Any lesion at this level can involve the red nucleus producing ipsilateral hand tremor
2. Subarachnoid part: Once the nerve exits is found in the subarachnoid space at the interpeduncular fossa, the nerve passes between the superior cerebellar and posterior cerebral arteries. Any aneurysm of these arteries can cause palsy of this nerve. (Figure 2)
3. Cavernous sinus part: The nerve runs in the lateral wall of the cavernous sinus superiorly. Any masses at this level coming from the sella can cause dysfunction of the nerve. (Figure 3)

4. Orbital part: The nerve enters the orbit through the superior orbital fissure in the common tendinous ring and divides into two branches one superior and one inferior.

The superior division innervates: (Figure 3)

- The levator palpebrae muscle.
- The superior rectus muscles.
- The middle rectus muscle

The inferior division innervates:

- The inferior oblique.
- Inferior rectus
- Also contain parasympathetic fibers for the ciliary and sphincter of the pupil muscles. [12,23,24,25]

## CLINICAL DEFICIT

### SIGNS AND SYMPTOMS

The patient will usually present with sudden onset unilateral ptosis (or rarely, a bilateral ptosis if the damage occurs to the third nerve nucleus), which is frequently accompanied by significant eye or head pain. The patient rarely complains of double vision because the ptosis obscures the vision in the affected eye; however, if the lid is manually elevated, the patient will experience diplopia. Acuity is typically unaffected unless damage occurs in the superior orbital fissure and cranial nerve II is also involved. The affected eye positions in a non-comitant exotropic, hypotropic position (down and out). <sup>[17,18]</sup>

There will be limitation of elevation, depression and adduction. There is underaction of the superior, inferior, and medial recti muscles and inferior oblique muscle, which may be total or partial. The pupil may be dilated and minimally reactive to light (pupillary involvement), totally reactive and normal (pupillary non-involvement), or may be sluggishly responsive (partial pupillary involvement). The patient is frequently elderly and often has concurrent diabetes and/or hypertension. <sup>[12]</sup>

In a lesion at the level of the nucleus or nerve, the following signs will be seen in the patient:

1. Ptosis in the ipsilateral eye, because of loss of the

levator palpebrae superioris. If the pupil is covered completely the patient will not see with the involved eye.

2. The globe is found fully abducted and downward, due to the action of the lateral rectus that is supplied by the abducent nerve, and the superior oblique supplied by the trochlear nerve.
3. The pupil is dilated (mydriasis) and unresponsive to light due to sphincter pupillae paralysis. The patient will complain of photophobia in bright light.
4. Accommodation difficulties due to ciliary muscle paralysis
5. Diplopia

The visceral oculomotor nucleus, also called Edinger-Westphal nucleus: The axons from this nucleus contain parasympathetic preganglionic fibers that make synapses in the ciliary ganglion. The postganglionic fibers innervate the following intraocular muscles: Pupillary sphincter (Figure 4) and ciliary muscles

Aberrant regeneration occurs when damage to the CN III results in a resprouting and miscommunication of nerve to muscles. Fibers meant for certain muscles innervate the wrong muscles. The inferior rectus and medial rectus both communicate with the levator. As the medial rectus receives stimulation to contract and adduct the eye, it also stimulates the levator. Upon adduction, there will also be lid elevation and widening of the palpebral fissure. With attempted abduction, the medial rectus and the levator will be inhibited. The lid assumes a ptotic state when the eye abducts.

The inferior rectus shares fibers with the levator. When the patient looks down, the eyelid will retract, increasing the interpupillary fissure. The medial rectus shares communication with the pupil. When the patient adducts, the pupil constricts.

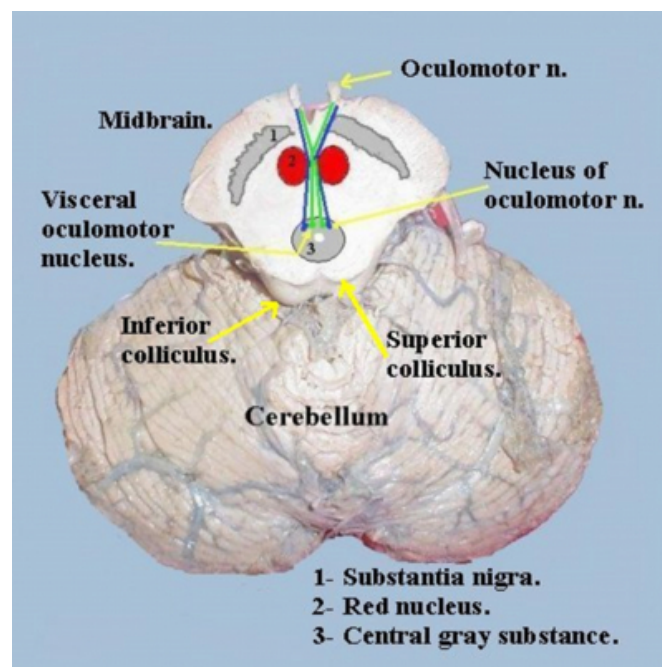
There are two types of CN III aberrant regeneration: primary and secondary. The secondary form commonly occurs after CN III palsy, resulting from direct damage to CN III. Aneurysm, trauma and compression by tumor are typical causes. Inflammatory causes of CN III palsy may result in aberrant regeneration. Aberrant regeneration does not occur after CN III palsy from ischemic infarct.

Primary aberrant regeneration occurs independently of antecedent CN III palsy. A slow-growing mass, such as an aneurysm or meningioma within the cavernous sinus, causes this variant. The mass theoretically exerts subclinical compression on CN III, damaging the nerve fibers with a simultaneous regeneration and aberrant resprouting of fibers to incorrect muscles. The patient may not complain of diplopia or ptosis, or even be aware of the changes occurring.

Our last comment about eye movements and oculomotor pathology is related with the unexpected, strong persistence of the eye movement in the direction of action of the disinserted muscle indicates that anatomy insertion not only occur at the point at which the muscle blends into the sclera but also involves the surrounding connective tissue. Orbital connective tissue can be considered an additional and important locomotor [26] system therefore conservation of some eye movements in oculomotor pathologies can be expected.

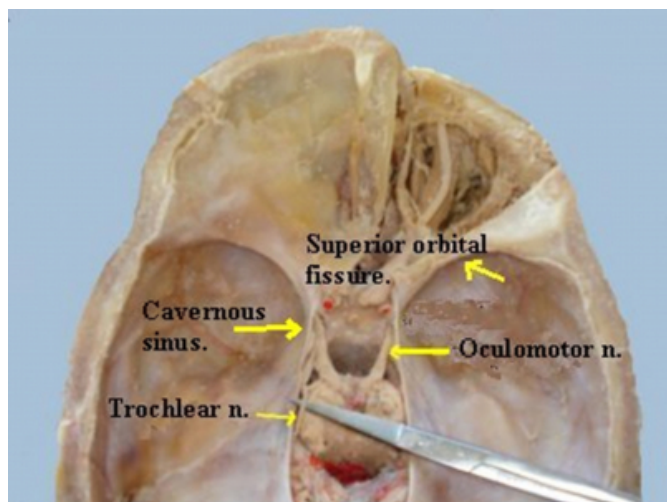
**Figure 1**

Figure 1: Cross-section of the midbrain at the level of the superior colliculi with the cerebellum attached posterior. The nuclei of origin situated in the central gray substance in front of the cerebral aqueduct. The axons travel through the midbrain tegmentum to exit medial to the cerebral peduncle. (Dissection made by Milanes-Rodriguez)



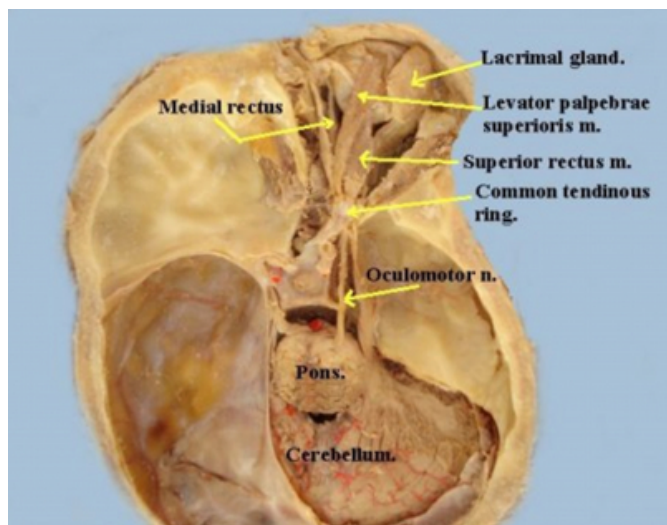
**Figure 2**

Figure 2: Base of the skull showing the exit of the oculomotor nerves and entrance in the cavernous sinus. (Dissection made by Milanes-Rodriguez)



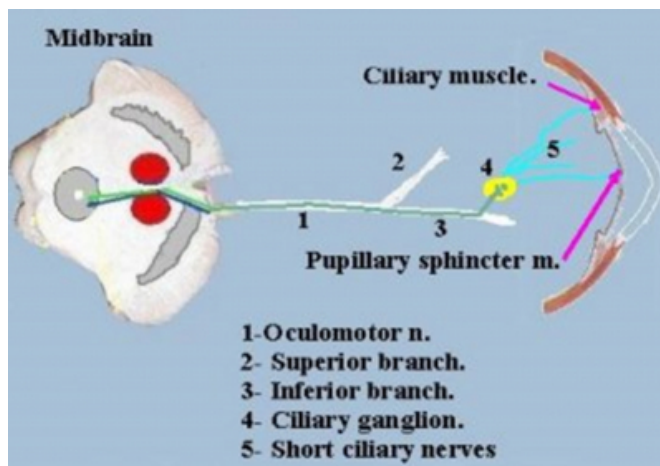
**Figure 3**

Figure 3: Base of the skull, with the cavernous sinus opens showing the path follow by the oculomotor n at this level and entrance through the common tendinous ring to supply the extraocular muscles except superior oblique and lateral rectus muscles. (Dissection made by Milanes-Rodriguez)



**Figure 4**

Figure 4: Axons from Edinger- Westphal nucleus contain preganglionic parasympathetic fibers that make synapses in the ciliary ganglion. Those postganglionic fibers supply the ciliary muscle and the sphincter of the pupil. (Diagram made by Milanes-Rodriguez)



## References

1. Horiuchi T, Kyoshima K, Oya F, Kobayashi S. Fenestrated oculomotor nerve caused by internal carotid-posterior communicating artery aneurysm: case report. *Neurosurgery*. 1997 Feb;40(2):397-399. [PubMed]
2. Ouvrier R, Billson F. Optic nerve hypoplasia: a review. *J Child Neurol*. 1986 Jul;1(3):181-188. [PubMed]
3. Pfeiffer RA, Jünemann A, Lorenz B, Sieber E. Aplasia of the optic nerve in two cases of partial trisomy 10q24-ter. *Clin Genet*. 1995 Oct;48(4):183-187. [PubMed]
4. Masateru K, Takeshi K, Shuzo S, Atsuhiko K, and Kazunari Y. Abnormal Course of the Oculomotor Nerve on the Clivus Combined with a Petroclival Meningioma. *Case Report. Skull Base*. 2002 August; 12(3): 141-144
5. Ouvrier R, Billson F. Optic nerve hypoplasia: a review. *J Child Neurol*. 1986 Jul;1(3):181-188. [PubMed]
6. Key Hwan L, Engle E, Demer J. Abnormalities of the Oculomotor Nerve in Congenital Fibrosis of the Extraocular Muscles and Congenital Oculomotor Palsy. *Investigative Ophthalmology and Visual Science*. 2007;48:1601-1606.
7. Tükel H, A Uzumcu, A Gezer, H Kayserili, M Yuksel Apak, O Uygur, S H Gultekin, H-C Hennies, P Nurnberg, R J Desnick, B Wollnik. A new syndrome, congenital extraocular muscle fibrosis with ulnar hand anomalies, maps to chromosome 21qter. *Journal of Medical Genetics* 2005;42:408-415
8. J. L. Demer, R. A. Clark, K. H. Lim, and E. C. Engle. Magnetic Resonance Imaging of Innervational and Extraocular Muscle Abnormalities in Duane-Radial Ray Syndrome. *Invest. Ophthalmol. Vis. Sci.*, December 1, 2007; 48(12): 5505 - 5511.
9. C. Pieh, A. Berlis, and W. A. Lagreze. Synergistic Convergence in Congenital Extraocular Muscle Misinnervation. *Arch Ophthalmol*, April 1, 2008; 126(4): 574 - 576.
10. E. C. Engle. Genetic Basis of Congenital Strabismus. *Arch Ophthalmol*, February 1, 2007; 125(2): 189 - 195.
11. Umansky F, Valarezo A, Elidan J. The superior wall of the cavernous sinus: a microanatomical study. *J Neurosurg*. 1994 Dec;81(6):914-920. [PubMed]
12. Goddwin J. Oculomotor nerve palsy. *eMedicine* .

Available at URL:

<http://www.emedicine.com/OPH/topic183.htm> [Reviewed on July 18th,2008]

13. Acierno MD, Trobe JD, Cornblath WT, Gebarski SS. Painful oculomotor palsy caused by posterior-draining dural carotid cavernous fistulas. *Arch ophthalmol*. Aug 1995;113(8):1045-9. [Medline].
14. Asbury AK, Aldredge H, Hershberg R, Fisher CM. Oculomotor palsy in diabetes mellitus: a clinico-pathological study. *Brain*. 1970;93(3):555-66. [Medline].
15. Chen PR, Amin-Hanjani S, Albuquerque FC. Outcome of oculomotor nerve palsy from posterior communicating artery aneurysms: comparison of clipping and coiling. *Neurosurgery*. Jun 2006;58(6):1040-6; discussion 1040-6. [Medline].
16. Daniell MD, Gregson RM, Lee JP. Management of fixed divergent squint in third nerve palsy using traction sutures. *Aust N Z J Ophthalmol*. Aug 1996;24(3):261-5. [Medline].
17. Jacobson DM. Pupil involvement in patients with diabetes-associated oculomotor nerve palsy. *Arch Ophthalmol*. Jun 1998;116(6):723-7. [Medline].
18. Jacobson DM, Broste SK. Early progression of ophthalmoplegia in patients with ischemic oculomotor nerve palsies. *Arch Ophthalmol*. Dec 1995;113(12):1535-7.

[Medline].

19. Jacobson DM, McCanna TD, Layde PM. Risk factors for ischemic ocular motor nerve palsies. *Arch Ophthalmol*. Jul 1994;112(7):961-6. [Medline].
20. Keane JR. Aneurysms and third nerve palsies. *Ann Neurol*. Dec 1983;14(6):696-7. [Medline].
21. Keane JR, Ahmadi J. Third-nerve palsies and angiography. *Arch Neurol*. May 1991;48(5):470. [Medline].
22. Leivo S, Hernesniemi J, Luukkonen M, Vapalahti M. Early surgery improves the cure of aneurysm-induced oculomotor palsy. *Surg Neurol*. May 1996;45(5):430-4. [Medline].
23. Miller NR. The ocular motor nerves. *Curr Opin Neurol*. Feb 1996;9(1):21-5. [Medline].
24. Quisling SV, Shah VA, Lee HK. Magnetic resonance imaging of third cranial nerve palsy and trigeminal sensory loss caused by herpes zoster. *J Neuroophthalmol*. Mar 2006;26(1):47-8. [Medline].
25. Trobe JD. Third nerve palsy and the pupil. Footnotes to the rule. *Arch Ophthalmol*. May 1988;106(5):601-2. [Medline].
26. Hakim OM, El-Hays YS, Maher H. Persistence of eyes movements following disinsertion of extraocular muscle. *J AASPO* 2008;12:62-65

**Author Information**

**G. Milanes-Rodriguez**

Department of Anatomy and Neurology Unit, Faculty of Health Sciences, Mandela Academic Hospital. Walter Sisulu University

**LdeF Ibañez-Valdés**

Department of Anatomy and Neurology Unit, Faculty of Health Sciences, Mandela Academic Hospital. Walter Sisulu University

**H. Foyaca-Sibat**

Department of Anatomy and Neurology Unit, Faculty of Health Sciences, Mandela Academic Hospital. Walter Sisulu University