

Multifocal fibrous Dysplasia with enchondroma-like areas: Fibrocartilaginous Dysplasia

V Monappa, R Kudva

Citation

V Monappa, R Kudva. *Multifocal fibrous Dysplasia with enchondroma-like areas: Fibrocartilaginous Dysplasia*. The Internet Journal of Pathology. 2007 Volume 7 Number 2.

Abstract

Fibrocartilaginous dysplasia is a variant of fibrous dysplasia showing extensive cartilaginous differentiation (enchondroma-like areas). The amount of cartilage varies from case to case. This has been reported more commonly in polyostotic disease. We present a 19 year old boy who presented with multifocal osteolytic lesions involving right femoral neck and lower end of left fibula. Curettage of the lesions showed translucent cartilaginous fragments. Microscopy revealed a cartilaginous (70%) and fibro-osseous (30%) component; the former showed focally increased cellularity while the latter showed features of fibrous dysplasia.

INTRODUCTION

Fibrous dysplasia (FD) is an unusual developmental defect of lamellar bone formation characterized by fibro-osseous metaplasia. Monostotic form is six times more common than polyostotic FD¹. Genetic studies have shown that FD is a potentially crippling disease caused by postzygotic, activating missense mutations of GNAS1 gene, which encodes a subunit of the stimulatory G protein^{2,3}. The tumor commonly occurs in 1st and 2nd decades of life. Long bones, ribs and skull are more commonly affected; however any bone can be involved. Histologically it is characterized by irregular shaped immature bony trabeculae without osteoblastic rimming arising from the surrounding spindle cell fibrous stroma. Radiologically, FD shows characteristic groundglass appearance with a rim of host bone sclerosis.

Rarely, nodules of hyaline cartilage can be seen in monostotic and polyostotic cases. Some authors have used the term 'fibrocartilaginous dysplasia' (FCD) to describe FD with extensive cartilaginous differentiation^{3,4,5}. FCD more commonly occurs in lower extremity, especially proximal portion of femur. Radiologically ground glass opacity with ring-like calcifications typical of cartilage, are seen⁴. Sometimes the cartilaginous component is so extensive that it simulates a primary benign or malignant cartilaginous lesion. Thus differentiating FCD from other primary cartilaginous tumors is of significance in the management of these tumors.

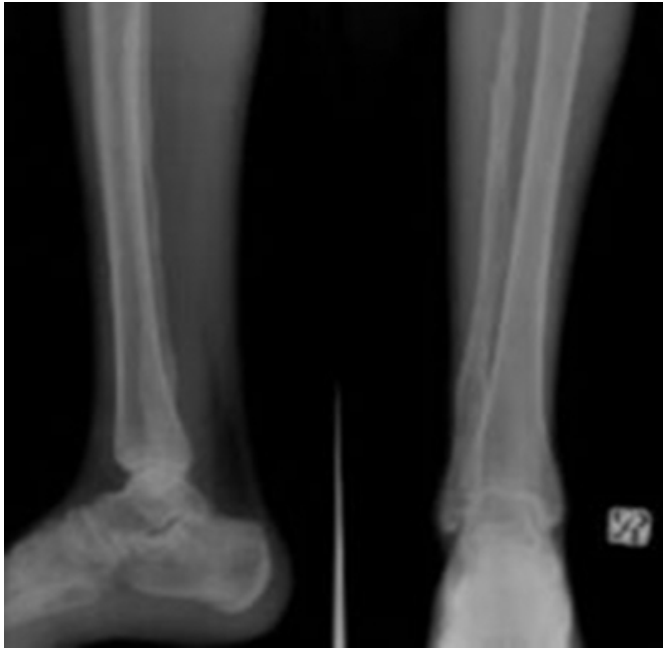CASE REPORT

A 19 year old boy presented with the complaints of pain in the lower part of right leg of 3 months duration. Examination revealed a hyperpigmented patch over the right side of face. Local examination showed no bony tenderness. Serum alkaline phosphatase was raised (309 u/l). Other laboratory parameters were within normal limits.

Radiological examination revealed lucent expansile medullary lesion having ground glass appearance in the distal end of the right fibula with ring like calcifications. Another bony expansion with subtle lucency was seen in the mid diaphyseal region of the same bone (Figure 1).

Figure 1

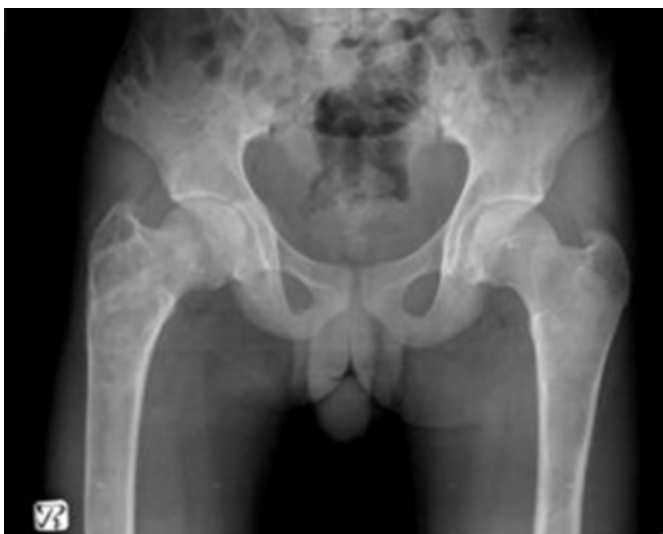Figure 1: Expansile intramedullary groundglass lesions in fibula.



A similar expansile lytic lesion with ground glass matrix was seen involving the right proximal femoral shaft and the greater trochanter with mild deformity seen in the proximal femoral region. Ring-like calcification suggesting cartilage was not well appreciated in our case. Well defined cystic lucencies with thin rim of sclerotic margins seen in the right iliac blade (Figure 2)

Figure 2

Figure 2: Lytic lucencies in proximal right femoral shaft and iliac blades.



Curettages from the femoral and fibular lesions showed multiple grey-white to translucent cartilage-like tissue bits.

Histological examination showed predominantly (70%) nodules of benign hyaline cartilage, showing focal increased cellularity (Figure 3) admixed with areas of fibrous dysplasia with immature bony trabeculae lacking osteoblastic rimming arising from surrounding fibrous stroma. Areas of calcification and endochondral ossification were also seen (Figure 4,5). No pleomorphism or increased mitotic activity was seen in the cartilage islands. A final diagnosis of Fibrous dysplasia with extensive cartilaginous differentiation (Fibrocartilaginous dysplasia) was made after examination of all 5 slides and several recuts.

One year follow-up of the patient showed no evidence of recurrence.

Figure 3

Figure 3: Islands of cartilage showing increased cellularity (H&E, 200X).

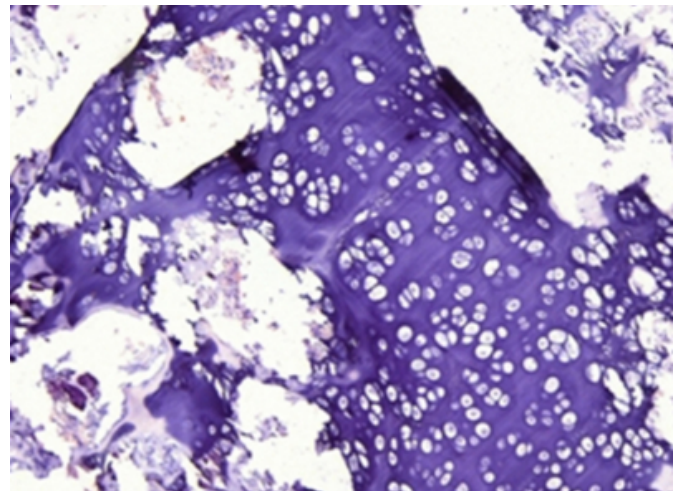


Figure 4

Figure 4: Islands of Fibrous Dysplasia surrounded by nodules of benign hyaline cartilage with focal enchondral ossification (H&E, 100X).

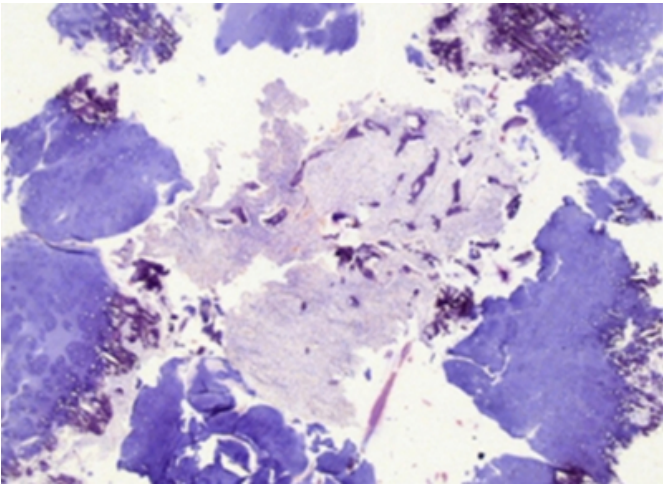
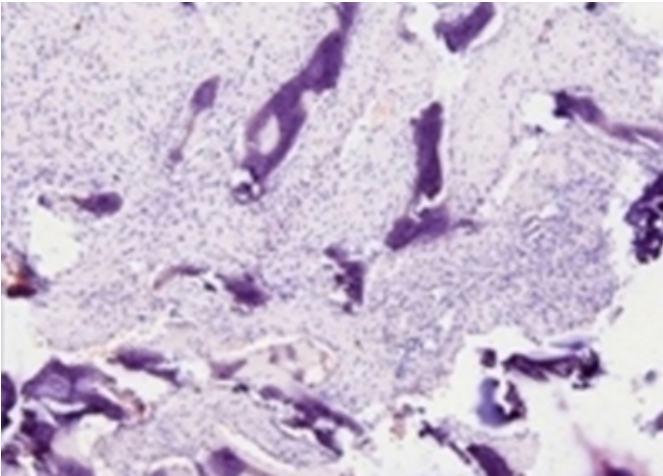


Figure 5

Figure 5: Islands of Fibrous dysplasia with immature bony trabeculae without osteoblastic rimming set in a cellular fibrous stroma (H&E, 400X).



DISCUSSION

It is well recognized that FD may contain cartilage, the amount of which, however, is variable. Lichtenstein and Jaffe in their original article on FD were of the opinion that cartilage was an integral part of the dysplastic process ³. In a review of the English literature Kyriakos et al found 54 cases of FD in which cartilaginous differentiation was observed. At times this cartilage is abundant, such cases being designated under the rubric of either “fibrochondrodysplasia” a term introduced by Pelzmann et al in 1980, or, more frequently as “fibrocartilaginous dysplasia” ⁵.

The origin of cartilage in FCD however remains controversial. Some authors believe their origin as offshoots from the epiphyseal plate ⁶. Others believe that it is a consequence of direct stromal metaplasia ⁷. In the present case direct stromal metaplasia was not evident as the tumor was predominantly composed of cartilage.

Review of the literature showed 12 well defined cases of FCD; the clinical details and treatment offered with follow-up is as summarized in Table 1.

Figure 6

Table 1: Reported cases of FD under the title “fibrocartilaginous dysplasia” or “fibrochondrodysplasia”

NO.	AGE	SITE	SYMPTOMS	TYPE	TREATMENT	FOLLOW UP	REF.
1	20	FF	Mass	PO	Osteotomies	15 yrs	Pelzmann et al
2	23	Tibia (proximal)	NS	PO	NS	NS	Ishida et al
3	8	FF	Pain	MO	NS	NS	Ishida et al
4	20	FF	Pain	MO	NS	NS	Ishida et al
5	26	Ischion	Mass	MO	NS	NS	Ishida et al
6	14	FF	NS	MO	NS	NS	Ishida et al
7	25	FF	Pain, fracture	MO	NS	NS	Ishida et al
8	4	FS	Limp	MO	NS	NS	Ishida et al
9	15	FF	Pain	PO	Tumor excision	NS	Ishida et al
10	53	FF	Pain	MO	NS	NS	Hermann et al
11	21	FF	Progressive deformity	MO	Amputation	18 yrs	Kyriakos et al
12	6	FF	Pain	MO	Curettage	5 yrs	Vargas-Gonzalez et al
13	19	FF, distal fibula	Pain	PO	Curettage	1 yr	Present case

FF- Proximal femur, MO- Monostotic, PO- Polyostotic, FS- Femoral shaft, NS- Not specified

Clinically, FCD occurs more commonly in males as compared to conventional FD. Both occur in patients younger than 30yrs, with proximal femur being the most common site. FCD rarely occurs in craniofacial bones and ribs. The percent of FCD cases associated with Mc Cune Albright syndrome (27%) is greater than conventional FD (3%) ^{6,8}.

Radiologically, FCD has been described as well-demarcated lucent lesions of ground-glass opacity usually containing stippled or ring-like calcifications suggesting cartilaginous elements ⁹. The calcification may be so extensive as to mimic an enchondroma or chondrosarcoma. Cortical expansion may be seen, however cortex is always intact ³, as

was observed in our case.

Gross appearance of the tumor is similar to an enchondroma or low grade chondrosarcoma, and consists of fragments or irregular masses of grey white to translucent tissue with an obvious cartilaginous appearance.

Histologically, FCD differs from conventional FD only by its additional component of cartilage, with benign appearing spindle cell stroma and irregularly shaped trabeculae of metaplastic woven bone found in both. The cartilage islands are well circumscribed, round nodules rimmed by a layer of woven or lamellar bone developing by enchondral ossification^{3,5}. At times the large cartilage islands may show increased cellularity, binucleate cells and nuclear atypia which could lead to a misdiagnosis of chondrosarcoma. The cartilaginous component can be massive as to mimic a chondroid neoplasm. Hence the key to the diagnosis is the identification of the classical areas of FD.

Malignant transformation in FCD is a rare entity. Ozaki et al¹⁰ reported a case of de-differentiated chondrosarcoma arising in a case of Albright's syndrome, probably arising in a pre-existing FCD.

The histologic differential diagnosis of FCD include – enchondroma, osteochondroma, low grade chondrosarcoma, periosteal (chondroblastic osteosarcoma) and fibrocartilaginous mesenchymoma^{3,5}.

Small biopsy specimen may show only cartilaginous foci of the lesion, resulting in the diagnosis of enchondroma. However cartilage nodules rimmed by woven bone is not a feature of enchondroma.

Cartilage cap overlying enchondral ossification is a feature of osteochondroma. Conventional FD like areas are thus necessary to exclude this entity.

Absence of soft tissue extension, peripheral zones of enchondral ossification surrounding nodules of cartilage and presence of metaplastic cartilage help to rule out atypia in FCD from chondrosarcoma.

Periosteal osteosarcoma shows lobules of cartilage with less atypia. Presence of neoplastic osteoid formation is the differentiating feature.

Fibrocartilaginous mesenchymoma is an extremely rare lesion that affects metaphyseal region of bones, particularly the proximal fibula. Roentgenographically, the calcification has a very peculiar longitudinal striation characteristic. The

lesion contains spindle cell proliferation, which has a fibrosarcoma like quality and islands of cartilage that show a pattern of organisation reminiscent of epiphyseal growth plates. It is locally aggressive with a high frequency of recurrence, especially when resection is incomplete^{11,12,3}.

Percentage of cartilage in a case of FD required to make a diagnosis of FCD has not been described in literature. Gonzalez V and Sosa S³ observed 60% cartilage in their case of FCD. The present case had around 70% cartilaginous areas.

Treatment of FCD is similar to FD and consists of surgical curettage with bone grafting. Surgical amputation described as a treatment measure in one case in the literature resulted as a consequence of progressive deformity of the involved limb⁵.

To conclude, FD may show cartilaginous foci, the amount of which is variable. As observed by many authors, presence of cartilage is an indicator of future progressive bone deformity. Extensive cartilaginous differentiation in FCD can be easily mistaken for a benign or malignant chondroid neoplasm, radiology not offering much help to distinguish the two. Accurate histologic diagnosis is thus critical to the management of these cases. This can be achieved by thorough sampling of specimen to demonstrate areas of conventional FD.

ACKNOWLEDGEMENT

We would like to thank Dr Sripathi Rao, Professor and Chief of unit IV, Department of Orthopaedics , Kasturba Hospital Manipal for providing us the clinical details of this patient.

CORRESPONDENCE TO

Dr. Vidya Monappa Assistant Professor Department of Pathology Kasturba Medical College Manipal – 576104 Karnataka, India E-mail : vidsdr@yahoo.co.in Telephone No.: Office : (0820)9222492 Residence : (0820)9222584 Fax NO. : (0820)2570061

References

1. Fletcher CDM, Unni KK, Mertens F : World health organization classification of tumors, Pathology and genetics of tumors of soft tissue and bone. IARC press, Lyon, 2002 : pg 341
2. Wagoner HA, Steinmetz R, Bethin KE, Eugster EA, Pescovitz OH, Hannon TS. GNAS mutation detection is related to disease severity in girls with McCune-Albright syndrome. Padiatr Endocrinol Rev. 2007;4 Suppl 4:395-400.
3. Vargas-Gonzalez R, Sanchez-Sosa S. Fibrocartilaginous dysplasia (Fibrous dysplasia with extensive cartilaginous differentiation). Pathology Oncology Research.

2006;12(2):111-114

4. Ishida T, Dorfman HD. Massive chondroid differentiation in fibrous dysplasia of bone (fibrocartilaginous dysplasia). *Am J Surg Pathol.* 1993;17(9):924-30.

5. Kyriakos M, Mc Donald DJ, Sundaram M. Fibrous dysplasia with cartilaginous differentiation ("fibrocartilaginous dysplasia"): a review, with an illustrative case followed for 18 years. *Skeletal Radiol.* 2004;33(1):51-62.

6. Forest M, Tomeno B, Vanel D : Orthopedic Surgical Pathology : diagnosis of tumors and pseudotumoral lesions of bone and joints. Churchill Livingstone, Edinburgh, pp. 595-612.

7. Hermann G, Klein M, Abdelwahab IF, Kenan S. Fibrocartilaginous dysplasia. *Skeletal Radiol.*

1996;25(5):509-11.

8. Mirra JM. Bone tumors. Clinical, radiologic and pathologic correlations. Philadelphia: Lea & Febiger, 1989.

9. Unni KK. Letter to the editor. *Am J Surg Pathol.* 1993;19:1447-48.

10. Ozaki T, Linder N, Blasius S. Dedifferentiated chondrosarcoma in albright syndrome. *JBJS.* 1997;79:1545-51.

11. Bhaduri A. Letter to the editor. Fibrocartilaginous mesenchymoma versus fibrocartilaginous dysplasia - are these a single entity? *Am J Surg Pathol.* 1995;19:1447.

12. Gedikoglu G, Aksoy MC, Ruacan S. Fibrocartilaginous mesenchymoma of the distal femur: case report and literature review. *Pathol Int.* 2001;51(8):638-42.

Author Information

Vidya Monappa, MD,DNB

Assistant Prof., Department of Pathology, Kasturba Medical College

Ranjini Kudva, MD

Professor, Department of Pathology, Kasturba Medical College