

Idiopathic sclerosing encapsulating peritonitis; rare cause of intestinal obstruction

O Singh, S Gupta, S Shukla, R Mathur

Citation

O Singh, S Gupta, S Shukla, R Mathur. *Idiopathic sclerosing encapsulating peritonitis; rare cause of intestinal obstruction*. The Internet Journal of Surgery. 2008 Volume 20 Number 2.

Abstract

Sclerosing encapsulating peritonitis (SEP) also known as abdominal cocoon is an uncommon condition that is characterized by the encasement of the small bowel by a fibro-collagenic membrane leading to clustering of the bowel, and thus may rarely cause intestinal obstruction. Only few cases of this disease have been reported in world literature. The etiology of this condition is unknown, and it is usually diagnosed incidentally on exploration. Surgery (membrane dissection and extensive adhesiolysis) is the treatment of choice. We report a case of SEP in a 38-year-old male patient.

INTRODUCTION

Sclerosing encapsulating peritonitis (SEP) is an uncommon peritoneal condition that is characterized by the encasement of the small bowel by a fibro-collagenic membrane leading to clustering of the bowel, and thus may rarely cause intestinal obstruction.¹² Only few cases of this disease have been reported in world literature.¹ The disease mainly involves small bowel.¹ Also known as abdominal cocoon: the condition generally affects adolescent girls and has been found to be more common in tropical and subtropical countries of the world.¹⁷ Preoperative diagnosis is difficult and requires a high index of clinical suspicion. Membrane dissection and extensive adhesiolysis is the treatment of choice. We report a case of SEP in a 38-year-old male patient followed by discussion of the case.

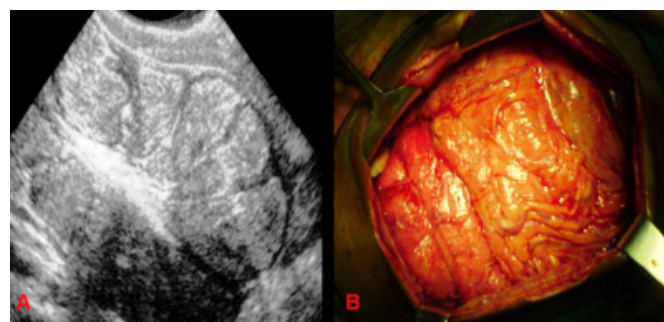
CASE PRESENTATION

A 38-year-old male presented in the emergency room with two-day history of abdominal pain, vomiting and abdominal distension. The abdominal radiograph showed multiple air-fluid levels in the central abdomen. Ultrasonography of the abdomen revealed clumping of small bowel loops covered by an encapsulating membrane (Figure 1-A). The patient gave a history of a similar episode a year back which subsided without treatment in two days. He was explored for acute intestinal obstruction. Intra-operatively, complete encasement of the small bowel loops and omentum by a membrane with loose inter-bowel adhesions was found (Figure 1-B). Using blunt and sharp dissection, the adherent membrane overlying the small bowel loops was stripped off

and adhesiolysis of bowel was performed. Histology of the membrane showed fibro-collagenous tissue with chronic inflammatory reaction. The patient has been followed for ten months post-operatively and is doing well.

Figure 1

Figure 1-A: Abdominal USG of a 38-year-old male showing clumping of bowel loops covered by an encapsulating membrane. B. Intra-operative photograph showing a fibrotic encapsulating membrane covering small bowel loops forming a cocoon.



DISCUSSION

Sclerosing encapsulating peritonitis (SEP), also known in the literature as abdominal cocoon, is an uncommon peritoneal condition that is characterized by the encasement of the small bowel by a fibro-collagenic membrane leading to clustering of the bowel, and thus may rarely cause intestinal obstruction.¹² Only few cases of this disease have been reported in world literature.¹ The disease primarily involves small bowel, but can extend to involve other organs like the large intestine, liver and stomach.¹²³ This condition

can be idiopathic or secondary (most importantly and most frequently due to chronic ambulatory peritoneal dialysis).⁴ The idiopathic form is commoner and was first described by Foo et al.¹⁵⁶ Patients with abdominal cocoon are generally adolescent girls.¹⁷ Only few idiopathic cases in males have been reported.² The condition has been found to be more common in tropical and subtropical countries of the world, especially China, Malaysia, Singapore, Pakistan, India, Nigeria, Kenya, Saudi Arabia, Israel, and South Africa.¹⁷ The typical age range is between 12 and 18 years; however, patient ages range from 6 to 65 years in the literature.⁶

Although the etiology of abdominal cocoon is unknown, subclinical primary viral peritonitis, as an immunological reaction to gynecological infections, or due to retrograde menstruation, and in collagen tissue diseases like scleroderma, have been suggested.¹ Multiple etiologies for abdominal cocoon have been established, although the underlying pathogenesis is not fully understood. It may occur as a serious complication of chronic ambulatory peritoneal dialysis.⁸ It has also been described in association with prolonged praloxone therapy, sarcoidosis, systemic lupus erythematosus, indwelling abdominal catheters (specifically ventriculoperitoneal and peritoneovenous shunts), orthotopic liver transplantation, liver cirrhosis, intraperitoneal instillation of drugs, leiomyomata of the uterus, endometriotic cyst or tumours of the ovary, recurrent peritonitis and tuberculous pelvic inflammatory disease.

²⁶⁹¹⁰¹¹¹² It can rarely occur in the absence of medical or surgical risk factors, as in this case. This condition presents with recurrent episodes of acute or sub-acute small intestinal obstruction that is seldom complete, attacks of colicky abdominal pain, weight loss, nausea and anorexia, and at times with a palpable abdominal mass.¹⁴ Early clinical features of sclerosing peritonitis are generally nonspecific and are frequently not recognized until the patient develops partial or complete small bowel obstruction.⁸

The condition is usually diagnosed incidentally on exploration, as in our case, although a preoperative diagnosis is feasible by a combination of barium follow-through which shows a concertina pattern or cauliflower sign along with delayed transit of contrast medium, and computed tomography of the abdomen. However, preoperative diagnosis is difficult and requires a high index of clinical suspicion. Pre-operative CT findings may include clumping of small bowel loops in the centre of the abdomen encased by a soft-tissue density mantle, peritoneal thickening, calcification, peritoneal enhancement, small bowel tethering,

and loculated fluid collections.²⁸

Surgery (membrane dissection and extensive adhesiolysis) is the treatment of choice, and there is usually no need for bowel loop resection, especially when a preoperative diagnosis is feasible. Resection of the bowel is unnecessary and it increases morbidity and mortality. Resection is indicated only if the bowel is non-viable. Careful dissection and excision of the thick membrane to release the small intestine leads to recovery. An excellent long-term postoperative prognosis is most of the times guaranteed.¹²³¹³

CONCLUSION

Idiopathic sclerosing encapsulating peritonitis, also called abdominal cocoon, is a rare cause of intestinal obstruction in adults.

References

1. Kaushik R, Punia RP, Mohan H, Attri AK. Tuberculous abdominal cocoon – a report of 6 cases and review of the Literature. *World J Emerg Surg* 2006; 1: 18. PMID: 16800898.
2. Deeb LS, Mourad FH, El-Zein YR, Uthman SM. Abdominal cocoon in a man. Preoperative diagnosis and Literature review. *J Clin Gastroenterol* 1998; 26: 148-50. PMID: 9563929.
3. Noor NHM, Zaki NM, Kaur G, Naik VR, Zakaria AZ. Abdominal cocoon in association with adenomyosis and leiomyomata of the uterus and endometriotic cyst: Unusual presentation. *Malaysian J Med Sci* 2004; 11: 81-5.
4. Kawaguchi Y, Kawanishi H, Mujais S, Topley N, Oreopoulos DG. Encapsulating peritoneal sclerosis: definition, etiology, diagnosis, and treatment. *International Society for Peritoneal Dialysis Ad Hoc Committee on Ultrafiltration Management in Peritoneal Dialysis. Perit Dial Int* 2000; 20 Suppl 4: S43-5. PMID: 11098928.
5. Foo KT, Ng KC, Rauff A, Foong WC, Sinniah R. Unusual small intestinal obstruction in adolescent girls: the abdominal cocoon. *Br J Surg* 1978; 65: 427-30. PMID: 656764.
6. Yoon YW, Chung JP, Park HJ, et al. A case of abdominal cocoon. *J Korean Med Sci* 1995; 10: 220-225. MID: 8527051.
7. Akca T, Ocal K, Turkmenoglu O, Bilgin O, Aydin S. Image of the month: Abdominal cocoon. *Arch Surg* 2006; 141: 943. PMID: 16983039.
8. Korzets A, Korzets Z, Peer G et al. Sclerosing peritonitis. Possible early diagnosis by computerized tomography of the abdomen. *Am J Nephrol* 1988; 8: 143-146. PMID: 3394722.
9. Cheijfec G, Reyes C, Stanley MM, et al. Diffuse peritoneal fibromatosis associated with peritoneo-venous shunt in patients with cirrhosis. *Lab Invest* 1983; 48: 15A.
10. Hunt D, Frew JL. Pericarditis and peritonitis associated with praloxone therapy [letter]. *Br Med J*. 1975; 1(5949): 92-3. PMID: 1109672.
11. Maguire D, Srinivasan P, O'Grady J, Rela M, Heaton ND. Sclerosing encapsulating peritonitis after orthotopic liver transplantation. *Am J Surg*. 2001; 182: 151-4. PMID: 11574087.
12. Laloo S, Krishna D, Maharajh J. Case report: Abdominal cocoon associated with tuberculous pelvic inflammatory disease. *Br J Radiol*. 2002; 75(890): 174-176.

PMID: 11893642.

13. Celicout B, Levard H, Hay J, Msika S, Fingerhut A, Pelissier E. Sclerosing encapsulating peritonitis: early and

late results of surgical management in 32 cases. French Associations for Surgical Research. Dig Surg. 1998, 15: 697-702. PMID: 9845640.

Author Information

Onkar Singh, M.B.B.S., MS (Gen Surg)

Senior Resident of Surgery, Department of Surgery, M.G.M Medical College & M.Y. Hospital, Indore, India. (452001)

Shilpi Gupta, M.B.B.S., MS (Gen Surg)

Senior Resident of Surgery, Department of Surgery, M.G.M Medical College & M.Y. Hospital, Indore, India. (452001)

Sumit Shukla, M.B.B.S., MS (Gen Surg)

Associate Professor, Department of Surgery, M.G.M Medical College & M.Y. Hospital, Indore, India. (452001)

Raj Kumar Mathur, M.B.B.S., M.S. (Gen Surg)

Professor of Surgery, Department of Surgery, M.G.M Medical College & M.Y. Hospital, Indore, India. (452001)