

Subglottic Mass: Benign Fibrous Histocytoma- A Rare Clinical Entity Presenting As Stridor

S Kaushik, A Karthikeyan, P Prabhakar

Citation

S Kaushik, A Karthikeyan, P Prabhakar. *Subglottic Mass: Benign Fibrous Histocytoma- A Rare Clinical Entity Presenting As Stridor*. The Internet Journal of Otorhinolaryngology. 2010 Volume 13 Number 1.

Abstract

We present a rare case report of an eight year old female child with stridor, wherein the histopathological examination of the excised subglottic mass proved to be Benign Fibrous Histiocytoma.

INTRODUCTION

Subglottic mass lesion is uncommon in children. We present a case of benign fibrous histocytoma (BFH) presenting as space occupying lesion of subglottic larynx, causing respiratory distress and stridor in an eight year old female child. Management includes confirmation of diagnosis by videolaryngoscopy and CECT neck, relieving of respiratory distress and treatment of underlying cause.

CASE REPORT

An eight year old female child presented in ENT OPD with biphasic stridor since past 8 months. It was insidious in onset, non progressive, whistling in nature, with history of dyspnea on exertion.

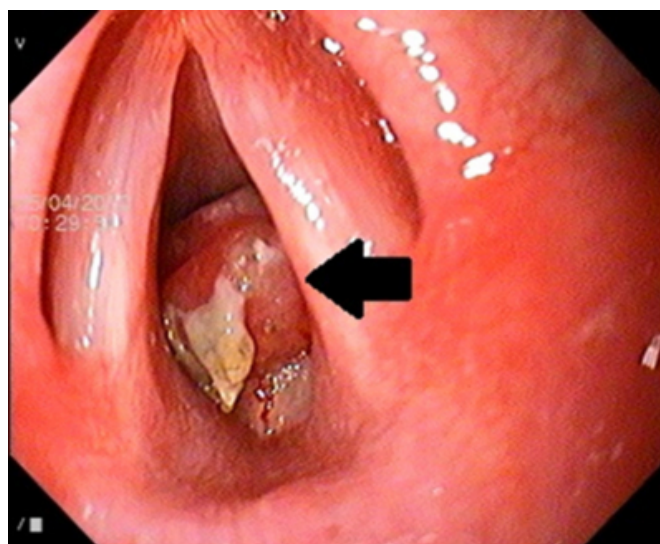
There was no history of foreign body ingestion, cough, hoarseness of voice, dysphonia, dysphagia, aspiration, apnea, cyanotic episodes, fever, diurnal or postural variation in respiratory distress.

On examination general condition was normal, pulse rate 82/min, oxygen saturation 98%. No suprasternal or intercostal recession.

X-ray neck revealed a radio- lucent shadow in subglottis. Flexible video laryngoscopy with 4mm scope showed fleshy globular mass in posterior part of subglottis, occupying more than half of the subglottis. (fig. 1)

Figure 1

Fig.1. flexible video laryngoscopy photograph of the subglottic mass



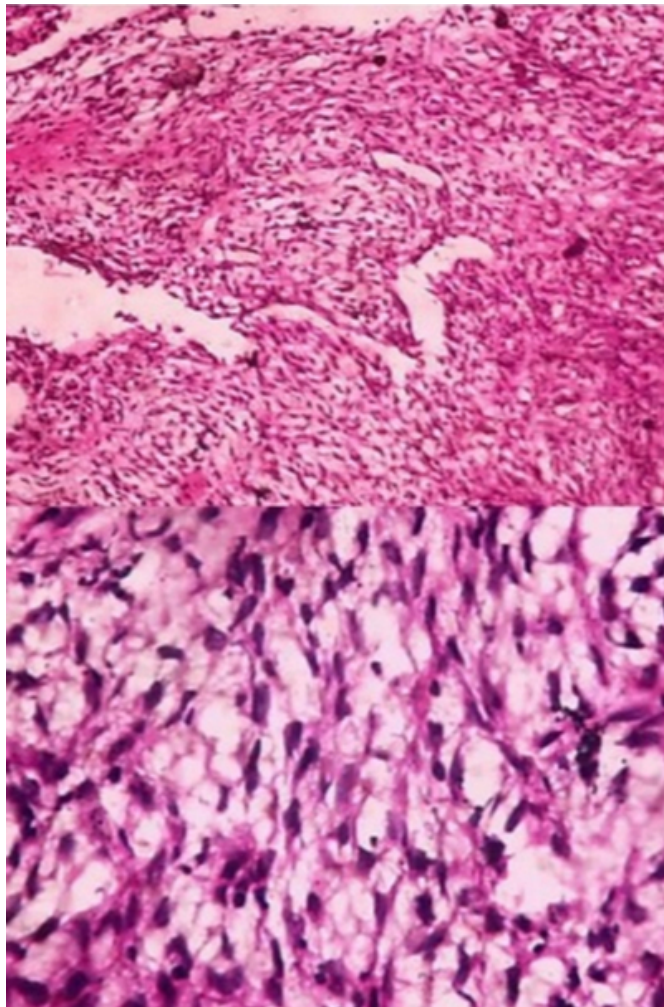
CECT neck showed an enhancing polypoidal, circumscribed, mass with well defined regular outline, broad stalk, intraluminal lesion at level of subglottis, arising from right posterolateral wall, measuring 1x1 cm in antero-posterior and transverse diameter, with vertical height of 6mm.

The patient underwent elective tracheostomy and Micro laryngeal surgical excision under G.A. Similar lesions were absent in the rest of the airway. Tracheotomy removed on 2nd post operative day, the patient was relieved of symptoms, no stridor or respiratory distress seen, discharged on seventh post- operative day. Post-operative video laryngoscopy showed no lesion. The patient is under follow up and doing well.

The histopathology of the excised specimen showed storiform pattern of uniform spindle cells with ill-defined eosinophilic cytoplasm and bland, elongated or plump vesicular nuclei with no atypia and foamy macrophages proving to be a Benign Fibrous Histiocytoma. (Fig.2)

Figure 2

Fig.2. histopathology photograph showing spindle cells and macrophages in “storiform” pattern (above) and in high power magnification foamy macrophages are seen (below)



DISCUSSION

Benign Fibrous Histiocytoma, earlier known as fibroma, is a soft tissue tumor, arising from fibroblast or mesenchymal stem cells and exhibit varying histiocytic features. It is one of the commonest soft tissue tumors. BFH is solitary, slow growing nodule, usually appearing in early or mid adult life. Most common site of occurrence is skin, especially in extremities. They presents as elevated or pedunculated lesions measuring few millimeters to few centimeters in diameter, most being less than 3cm^[1].

Deep seated BFH are rare as compared to cutaneous

counterparts. In a study of 1000, BFH only three cases were reported to be arising from muscles. Deep seated BFH presents as painless slow growing tumor, occurring most commonly between 20 to 40 years of age. Small proportion of cases are seen as intramuscular, subcutaneous or intraabdominal mass^[2].

Primary tumor of subglottis is a rare clinical entity, comprising only 1% of laryngeal tumors^[3]. Common benign SOL lesion of larynx includes leiomyoma, nodular fascitis, hemangioma, papilloma, cystic hygroma, chondroma, neural neoplasm and minor salivary gland tumor that may arise anywhere in laryngotracheal tree.

Foreign body in airway tract or inflammatory disease as retropharyngeal abscess epiglottitis laryngotracheo bronchitis, angiodema & external trauma can lead to clinical picture of stridor and airway mass lesion but accompanying sign & symptoms and detailed history helps differential diagnosis.

Benign Fibrous Histiocytoma is a rare tumor of subglottis; first described in a new born child by Tsui et al in 1976^[4]. O'Connell et al. described Benign Fibrous Histiocytoma as an uncommon disease of adults and a rare disease in children^[6]. Fibroma of the laryngeal subglottic space was encountered by Protasevich^[5] while administering endotracheal anesthesia in the year 1978. Similar case of subglottic fibroma was reported by Klaudel et al^[7].

There has been association of BFH with SLE^[8]. Some suggest it to be a reactive condition, as there is history of trauma prior to appearance of lesion, though neoplastic origin of BFH can't be ruled out and the causative factor for origin of BFH is debatable.

BFH does not involute and local excision is required for removal. There is recurrence of tumor in 5 – 10% of cases of cutaneous BFH^[9] for deep seated BFH the recurrence rate is higher due to large size and incomplete removal^[10].

Rarely metastasis from BFH can occur, producing regional Lymph node metastasis and pulmonary metastasis^[11].

Clinically it can be differentiated from melanoma, by careful palpation, in BFH central dimple appears on palpation^[12].

Careful history, examination and investigation suggest the diagnosis but only endoscopy will confirm the diagnosis.

Other common causes of subglottic mass lesion in children are, subglottic hemangioma, first described by Morrell McKenzie in 1864. Hemangioma is the most common

benign lesion of subglottis in infants, increases in size up to one year of age and then starts to involute, most resolve by 5 years of age. True incidence of hemangioma of airway is unknown; 13 of 846 cases (1.5%) of laryngeal anomalies were reported as hemangioma by Hollinger^[13].

In western world prevalence of recurrent Respiratory papillomatosis is estimated as 7 per million per year. It is most common neoplasm of larynx in children, peak incidence between 2-5 years of age^[14].

Foreign body of airway tract usually passes through larynx and trachea and is lodged distally. Laryngeal foreign body may cause sudden death if complete obstruction is present or in case of partial obstruction stridor, hoarseness and cough are present.

Ductal cyst of larynx occurs due to obstruction of submucous gland is seen in supraglottis^[15]. Saccular cyst is usually congenital and seen in laryngeal ventricle.

Schouchnek reported the first case of schwannoma of larynx in 1925^[16] and lately a case of pleomorphic adenoma in subglottis was reported by Berjs in the year 2006^[3]. It is a rare clinical entity with most of cases arising from supraglottis^[17].

Various surgical approaches are described in literature for removal, varying from endoscopic removal, microlaryngeal surgery, laryngofissure, anterior & lateral Pharyngotomy approach.

CONCLUSION

Benign fibrous histocytoma (BFH), a soft tissue tumor is a rare disease of subglottis. We present a case of a common disease, at uncommon site with uncommon clinical presentation. Careful history, examination and investigation suggest the diagnosis, but only endoscopy will confirm the diagnosis. Treatment is surgical excision of mass to maintain airway patency.

References

1. Gonzalez S, Duarte I. Benign fibrous histocytoma of skin: Morphologic study of 290 cases. *Pathology Research Pract*, 1982; 174:379.
2. Fletcher CDM. BFH of sub cutaneous and deep soft tissue: clinicopathologic analysis of 21 cases. *American Journal of Surgical Pathology*, 1990; 14:801.
3. Berjis N, Haji Malian M. A case of Pleomorphic adenoma presenting as subglottic mass. *Shiraz E_Medical Journal*, 2006; 7(3).
4. Tsui HN, Lore JM Jr. Congenital subglottic fibroma in the newborn. *Laryngoscope*, 1976; 86(4):571-6.
5. Protasevich GS. Fibroma of the laryngeal subglottic space developing after endotracheal anesthesia. *Zh Ushn Nos Gorl Belezn*, 1978; (1):101-2.
6. O'Connell JE, Raafat F, Proops D. Congenital subglottic fibromatosis. *Journal of Laryngo Otology*, 1989; 103(10):983-5.
7. Klaudel A, Zaporowski J, Klaudel Gawlicka G. A case of the laryngeal fibroma. *Otolaryngology Polland*, 1996; 50(2):203-6.
8. New man D.M., Watter J.B. Multiple dermatofibroma in patients on immuno suppressive drugs. *New England Journal of Medicine*, 1973; 289:842.
9. Calonje E, Fletcher CDM. Cutaneous fibrohistiocytic tumors: an update. *Adv Anat Pathol*, 1994; 1:2.
10. Mentzel T, Calonje E, Fletcher CDM. Cellular Dermatofibroma: additional observations with emphasis on differential diagnosis. *British Journal of Dermatology*, 1993; 129:69.
11. Colome Grimmer MI, Evans HL. Metastasizing cellular dermatofibroma: a report of two cases. *American Journal of Surgical Pathology*, 1996; 20:1361.
12. Fitzpatrick TB, Gilchrist BA. Dimple sign, to differentiate benign from malignant pigmented lesions. *New Eng J. Med*, 1977; 296:1518.
13. Hollinger PH, Brown WT. Congenital webs, cysts, laryngoceles and other anomalies of larynx. *Ann Otol Rhinol laryngol*, 1967; 76:744.
14. Strong MS and others recurrent respiratory papillomatosis management with CO2 Lasers. *Ann otol Rhinol Laryngol*, 1976; 85:508.
15. David Albert, Susanna Leighton. Managing stridulous child. In: Charles W. Cummings, Paul W. Flint, Bruce H. Haughey, K. Thomas Robbins, J. Regan Thomas, Lee A. Harker, et al. *Cummings Otolaryngology Head and Neck surgery*. 4th ed. Philadelphia: Elsevier Mosby; 2005. Chapter 186, p.4241-65.
16. Schouchnek, quoted by Whittman DE et al. Neurilemmomas of larynx. *J Laryngol Otol*, 1979; 84:747-49.
17. Supance JS, Quenelle DJ, Crisman J. Endolaryngeal neurofibromas. *Otol Head Neck Surgery*, 1980; 88:74-78.

Author Information

Sandeep Kaushik, MS (ENT)

Head of the Department, Department of ENT, GSVM Medical College

Anand Karthikeyan, MS (ENT)-student

Junior Resident-final year, Department of ENT, GSVM Medical College

Prabhat Prabhakar, MS (ENT)-student

Junior Resident-second year, Department of ENT, GSVM Medical College