

# An Unusual Finger Injury By A Kitchen Utensil

S Saraf

## Citation

S Saraf. *An Unusual Finger Injury By A Kitchen Utensil*. The Internet Journal of Hand Surgery. 2009 Volume 3 Number 1.

## Abstract

We report here an unusual, previously unreported case of an entrapped finger of a child in a kitchen utensil, which resulted in significant injury. The report further discusses the measures to prevent such injuries in pediatric age group.

## INTRODUCTION

Finger injury is one of the commonest encountered injuries in the pediatric age group and the spectrum includes injuries from sharp objects, car and home doors, escalators, paper shredders and exercise related equipments.<sup>[1],[2],[3],[4]</sup> The finger injuries following entrapment are occasionally seen but rarely cause significant injury. The described case of entrapment of a finger in an 'Idly' making plate (Figure 1) probably represents the first reported case of its kind.

## Figure 1

Figure 1: 'Idly' making plate

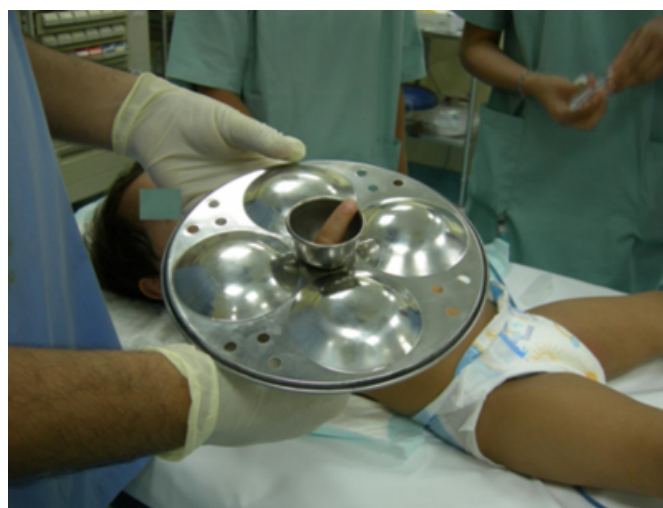

## CASE REPORT

A 2 year old child presented in emergency with entrapped impacted right index finger in the narrow hole of a kitchen utensil having sharp margins. The finger of the child got accidentally entrapped in the central hole of an 'idly' (a South-Indian dish) making stainless steel plate while playing unattended in the kitchen. (Figures 2, 3, 4, 5)

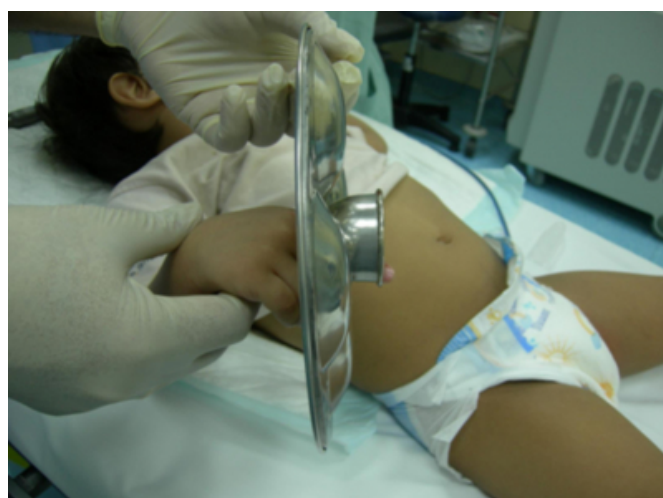## Figure 2

Figure 2



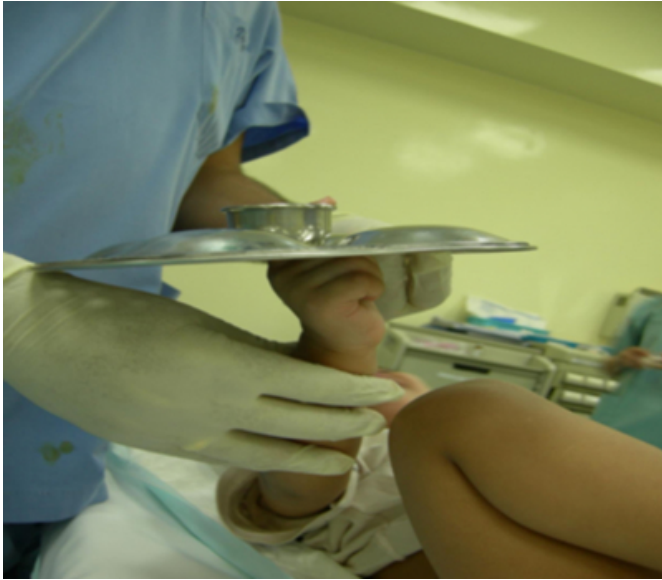## Figure 3

Figure 3



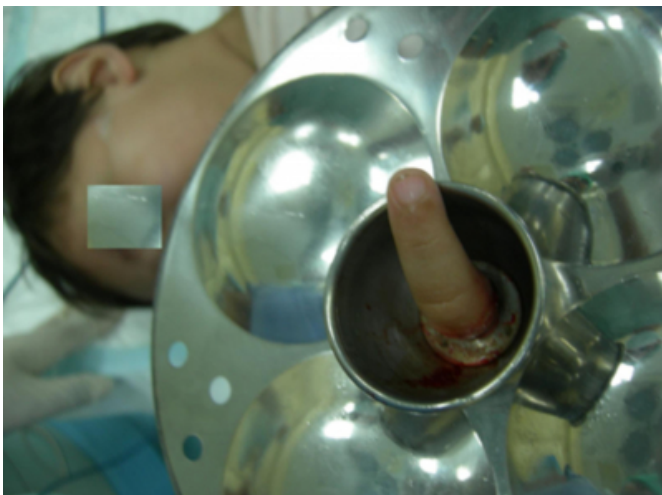
**Figure 4**

Figure 4



**Figure 5**

Figure 5



There were repeated failed attempts to disengage the finger by the parents and other health care providers. On examination, the right index finger was found to be swollen and totally impacted at the level of the proximal phalanx along with a bleeding wound over the volar aspect of the finger. The child was taken up for the procedure of retrieval of the finger under deep sedation. After stabilizing the finger and the kitchen utensil, the plate was cut till the distal part by a combination of heavy K-wire and bone cutters. The remaining part of the plate, adjoining the finger was finally cut with the help of a ring cutter with an inbuilt guard which protected the finger from the impact of the instruments. (Figures 6, 7)

**Figure 6**

Figure 6



**Figure 7**

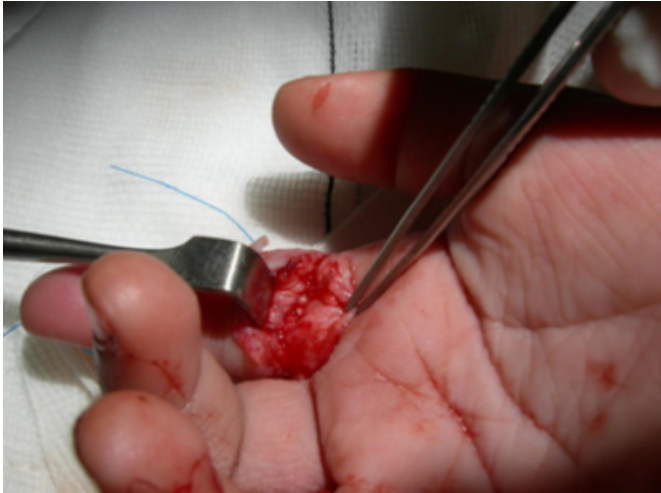Figure 7



The examination of the retrieved finger revealed a deep laceration over the volar aspect of the finger with flexor digitorum superficialis tendon injury (Figure 8) which was later appropriately managed.

**Figure 8**

Figure 8



### DISCUSSION

Finger injuries are common in children, especially at the preschool age. Though they are not life threatening they often lead to physical and emotional pain; interference with daily activities like eating, playing and doing school work; psychological trauma, deformity and sometimes substantial economic impact as well. The parents usually remain concerned about the immediate problem, long-term functional and aesthetic sequelae and financial implications. Most finger injuries tend to occur at home and are usually caused by “jamming/crushing” in the doors, either by their parents or siblings.<sup>[5]</sup> The incidence is seen highest in the younger children and boys in cases of isolated finger injuries.<sup>[6]</sup> The magnitude of the trauma might vary from simple to the complex injuries and may present as soft tissue laceration, avulsion injury, nail injury, fractures and often amputation. The complex injuries are not frequent but require specialized care and place a high demand on the resources.<sup>[7]</sup> Injuries like the entrapment of the finger in kitchen appliances are very unusual. Their management requires special attention as the safe finger retrieval without further damage to underlying neuro-vascular and tendinous structures is of prime most importance. These types of

injuries are essentially preventable if not avoidable. The parental attention, making home environment more conducive to child safety and using greater number of safety practices at home are of great significance. The parenting multi-faceted interventions, use of safety equipments and parental safety practices have a great role to play in preventing such unintentional injuries to the children.<sup>[8], [9]</sup>

### SUMMARY

The pediatric hand injuries should not be dismissed trivially and any significant or atypical injury should be referred to a specialized centre for necessary management. The role of parental attention, supervision and institution of appropriate safety measures in indoor and outdoor settings needs to be overemphasized to avoid such injuries.

### References

1. Macgregor DM, Hiscox JA. Fingertip trauma in children from doors. *Scott* 1999; 44(4):114-5.
2. Adamson C. A mother's tale: escalator amputates four fingers. *Injury Prevention* 1999; 5:87-88.
3. McGeehan J, Shields BJ, Wilkins JR, III, Ferketich AK, Smith GA. Escalator-Related Injuries Among Children in the United States, 1990-2002. *Pediatrics* 2006; 118 (2):279-85.
4. Warren RC, Foltin GL. Toddlers at risk for paper shredder injury in the home: easy access and severe injury. *Pediatrics* 2006; 117(2):535-8.
5. Doraiswamy NV. Childhood finger injuries and safeguards. *Inj Prev* 1999; 5:298-300.
6. Doraiswamy NV, Baig H. Isolated finger injuries in children – incidence and aetiology. *Injury* 2000; 31:571-3.
7. Ljungberg E, Rosberg HE, Dahlin LB. Hand Injuries in Young Children. *J Hand Surg* 2003; 28 (4); 376-80.
8. Kendrick D, Barlow J, Hampshire A, Polnay L, Stewart-Brown S. Parenting interventions for the prevention of unintentional injuries in childhood. *Cochrane* 2007, 17; (4):CD006020.
9. Kendrick D, Barlow J, Hampshire A, Stewart-Brown S, Polnay L. Parenting interventions and the prevention of unintentional injuries in childhood: systematic review and meta-analysis. *Child* 2008; 34(5):682-95.

**Author Information**

**Sanjay Saraf, MS, MCh. (Plastic Surgery) DNB (Plastic Surgery) MNAMS**  
Specialist Plastic Surgeon, Dept. of Plastic Surgery, NMC Specialty Hospital