

Hyperhidrosis: An Unusual Initial Presentation Of Hodgkin's Lymphoma

D Pahuja, M Eustace, P Chadha

Citation

D Pahuja, M Eustace, P Chadha. *Hyperhidrosis: An Unusual Initial Presentation Of Hodgkin's Lymphoma*. The Internet Journal of Hematology. 2004 Volume 2 Number 1.

Abstract

Introduction: Most patients with Hodgkin's disease present with palpable nontender lymphadenopathy in the neck, supraclavicular area and axilla. One third of patients present with fever, recurrent drenching night sweats and/or weight loss - B symptoms in the Ann Arbor Staging classification. Hodgkin's disease can occasionally present with unusual manifestations.

Literature search: We did a Medline search using Hodgkin's lymphoma and hyperhidrosis as subject headings and sweating as additional keyword. The search yielded 11 articles. All of these articles recognize nocturnal sweating as a B symptom. 1 article described the syndrome of neuromyotonia producing muscle stiffness, cramps, and frequently excessive sweating as initial presentation of Hodgkin's lymphoma but none had daytime sweating as initial presentation.

Case: We report a case of a 42-year-old male with complaints of profuse daytime sweating for six months. He said that "sweat pours out of my body." These sweating episodes came in spurts and he had an unusual ability to predict them. He felt this condition was socially embarrassing and described these episodes as "hot flashes". At presentation his physical examination was totally normal. Laboratory workup revealed mild anemia, leukocytosis and elevated platelets. He was initially started on an anticholinergic medication which he said helped him initially. Two months later he started having severe night sweats, and fever at night. He had lost about 40 lbs. At that time examination revealed cervical, supraclavicular, axillary and inguinal lymphadenopathy. Lymph node biopsy revealed classical Hodgkin's disease, best subclassified as nodular sclerosis. His staging CT scan showed extensive chest, abdominal and pelvic lymphadenopathy and hepatosplenomegaly. His serum immunoelectrophoresis showed hypoalbuminemia, but no monoclonal gammopathy. He was started on ABVP treatment with remarkable improvement.

Conclusion: Chronic excessive daytime sweating as the initial presentation of Hodgkin's lymphoma is rarely found in literature. Classical Hodgkin's lymphoma may present with a daytime variant of B symptoms before other manifestations become evident.

CASE REPORT

We report a case of a 42-year-old male with complaints of profuse daytime sweating for six months. He said that "sweat pours out of my body." These sweating episodes came in spurts and he had an unusual ability to predict them. He felt this condition was socially embarrassing and described these episodes as "hot flashes". He denied any headaches, dizziness, vertigo or paresthesia. There was no cough, hemoptysis, wheezing or shortness of breath. Review of systems was negative for chest pain or palpitations. His appetite was good and there was no heartburn. No dysuria or increase in frequency was reported. There were no joint pains, joint swellings, skin rashes or lesions. He denied any feeling of excessive cold. His past medical history was

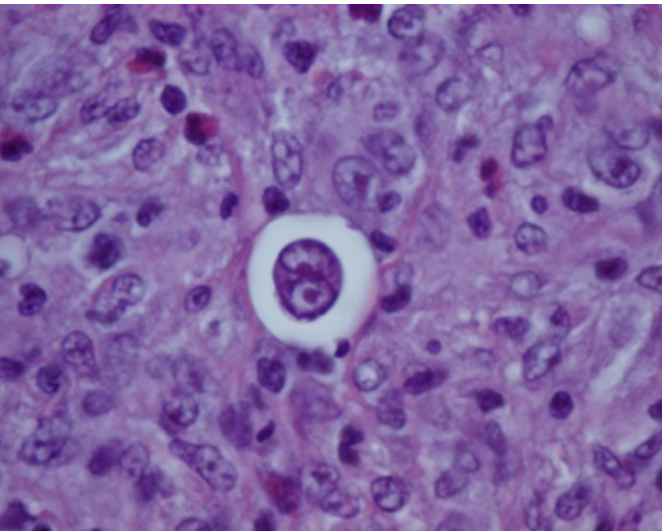
remarkable for undescended testicle which was brought down at 10 years age. He had a thoracotomy 15 years ago for pleural effusion that he assumes was due to motor vehicle accident that he was involved in two years prior to that. He had a history of alcoholic pancreatitis. He was not on any medications and reported no drug allergies. There was no family history of malignancy. He worked as a marketing director. He drank alcohol occasionally, did not smoke and used no recreational drugs. On physical examination he looked healthy, alert and oriented to time, place and person. Head and neck examination showed no jaundice or pallor. There was no nasal congestion. Throat examination was normal with moist and pink tongue. Neck showed no swelling, abnormal pulsations, jugular venous

distension or bruit and there was no lymphadenopathy. Chest showed no deformity and there were bilateral breath sounds with no wheezes or rhonchi. Heart sounds were normal with no murmurs, rubs or gallops. Abdomen was soft, nontender with no palpable hepatosplenomegaly. There was no limb edema or clubbing. Neurological examination was normal with no motor, sensory or cranial nerve deficits. Musculoskeletal examination showed normal range of motion for joints with no joint swelling. He had normal blood count, chem.-9 and thyroid studies.

This patient presented two months later with progressive symptoms of day and night time sweating, generalized weakness and fatigue. He had lost 40 lbs in this period. He denied and abdominal pain, nausea or vomiting. Examination of head and neck revealed prominent 1-1.5 cm cervical and supraclavicular lymphadenopathy with rubbery, firm and mobile lymph nodes. He also had 2 cm size inguinal and axillary lymphadenopathy. Lymphoma was suspected and a lymph node biopsy showed Nodular sclerosis Hodgkin's disease. His staging CAT scan showed extensive chest, abdominal and pelvic lymphadenopathy and hepatosplenomegaly. Pt was diagnosed with Hodgkin's stage III b and started on ABVP treatment with remarkable improvement.

Figure 1

Figure 1 shows a Reed - Sternberg cell with a binucleated cell with classical owl eye appearance. In the background reactive lymphocytes and eosinophils (H & E stain 100 X)



DISCUSSION

The major lymphatic structures involved in Hodgkin's disease are groups and chains of lymph nodes, the spleen and the thymus gland. The digestive system is also an

important lymphoid organ that has collections of lymphoid tissue known as Waldeyer's ring in the oropharynx, Peyer's patches in the ileum and lymphoid nodules in the appendix. Hodgkin's disease can involve almost any organ or tissue, especially the liver, bone marrow, and spleen, in addition to the lymph nodes.

Figure 2

Table 1: Stage Grouping

STAGE GROUPING	
Stage I	Involvement of single lymph node region (I) or localized involvement of a single extralymphatic organ or site (I _E).
Stage II	Involvement of two or more lymph node regions on the same side of the diaphragm (II) or localized involvement of a single associated extralymphatic organ or site and its regional lymph node(s) with or without involvement of other lymph node regions on the same side of the diaphragm (II _E).
Note: The number of lymph node regions involved may be indicated by a subscript (e.g., II ₃).	
Stage III	Involvement of lymph node regions on both sides of the diaphragm (III), which may also be accompanied by localized involvement of an associated extralymphatic organ or site (III _E), by involvement of the spleen (III _S), or both III _(E+S) .
Stage IV	Disseminated (multifocal) involvement of one or more extralymphatic organs, with or without associated lymph node involvement, or isolated extralymphatic organ involvement with distant (nonregional) nodal involvement.

Each stage is subdivided into “A” and “B” categories, “B” for those with defined systemic symptoms and “A” for those without. The B designation is given to those patients with:

- 1. Unexplained loss of more than 10% of body weight in 6 months before diagnosis;
- 2. Unexplained fever with temperatures above 38°C; and
- 3. Drenching night sweats.
- 4. Pruritis alone does not qualify for B classification,

nor does a short febrile illness associated with an infection.

References

1. Earley CJ, Kittner SJ, Fesser BR, Gardner J, Epstein A, Wozniak MA, Wityk R, Stern BJ, Price TR, Macko RF, Johnson C, Sloan MA, Buchholz D. Stroke in children and sickle-cell disease: Baltimore-Washington Cooperative Young Stroke Study. *Neurology*. 1998 July; 51(1): 169-76.
2. Fullerton HJ, Wu YW, Zhao S, Johnston SC. Risk of stroke in children: ethnic and gender disparities. *Neurology*. 2003 July 22; 61(2): 189-94.
3. Chung B, Wong V. Pediatric stroke among Hong Kong Chinese subjects. *Pediatrics* 2004; 114(2): e206-e212.
4. Obama MT, Dongmo L, Nkemayim C, Mbede J, Hagbe P. Stroke in children in Yaounde, Cameroon. *Indian Pediatr*. 1994 July; 31(7): 791-5.
5. Alam M., Lodhi MA, Khan D. Cerebrovascular accident in sickle cell disease. *J Coll Physicians Surg Pak*. 2003 January 13; (1): 55-6.
6. Kirkham F, Sebire G, Steinlin M., Strater R. Arterial ischaemic stroke in children. Review of the literature and strategies for future stroke studies. *Thromb Haemost*. 2004 October 92(4): 697-706.
7. Routhieaux J, Sarcone S, Stegenga K. Neurocognitive sequelae of sickle cell disease: current issues and future directions. *J Pediatr Oncol Nurs*. 2005 May-June; 22(3): 160-7.
8. Diagne I, Diagne-Gueye NR, Fall L, Ndiaye O, Camara B, Diouf S, Signate-Sy H, Kuakuvi N. Acute encephalic manifestations in Senegalese children with sickle cell disease. *Dakar Med*. 2001; 46(2): 116-20.
9. Ohene-Frempong K, Weiner SJ, Sleeper LA, Miller ST, Embury S, Moohr JW, Wethers DL, Pegelow Ch, Gill FM. Cerebrovascular accidents in sickle cell disease: rates and risk factors. *Blood*. 1998 January 1; 91(1): 288-94.
10. Adams RJ, McKie VC, Hsu L, Files B, Vichinsky E, Pegelow C, Abboud M, Gallagher D, Kutlar A, Nichols FT, Bonds DR, Brambilla D. Prevention of a first stroke by transfusions in children with sickle cell anemia and abnormal results on transcranial Doppler ultrasonography. *N Engl J Med*. 1998 July 2; 339(1): 5-11.
11. F J Kirkham. Stroke in childhood. *Arch Dis Child* 1999; July; 81:85-89.
12. Husson B, Lasjaunias P. Radiological approach to disorders of arterial brain vessels associated with childhood arterial stroke-a comparison between MRA and contrast angiography. *Pediatr Radiol*. 2004 January; 34(1): 10-5.
13. Hutchison JS, Ichord R, Guerguerian AM, Deveber G. Cerebrovascular disorders. *Semin Pediatr Neurol* 2004 June; 11(2): 139-46.
14. Abboud MR, Cure J, Granger S, Gallagher D, Hsu L, Wang W, Woods G, Berman B, Brambilla D, Pegelow C, Lewin J, Zimmermann RA, Adams RJ; STOP study. Magnetic resonance angiographies in children with sickle cell disease and abnormal transcranial Doppler ultrasonography findings enrolled in the STOP study. *Blood*. 2004 April 1; 103(7): 2822-6.
15. Fullerton HJ, Adams RJ, Zhao S, Johnston SC. Declining stroke rates in Californian children with sickle cell disease. *Blood*. 2004 July 15; 104(2): 336-9.
16. Pegelow CH, Adams RJ, McKie V, Abboud M, Berman B, Miller ST, Olivieri N, Vichinsky E, Wang W, Brambilla D. Risk of recurrent stroke in patients with sickle cell disease treated with erythrocyte transfusions. *J. Pediatr*. 1995 June; 126(6): 896-9.
17. DeVeber G. In pursuit of evidence-based treatments for paediatric stroke: the UK and Chest guidelines. *Lancet Neurol*. 2005 July 4;(7) 432-6.
18. Carvalho KS, Garg BP. Arterial strokes in children. *Neurol Clin*. 2002 November 20;(4): 1079-100, vii.
19. Gulbis B, Haberman D, Dufour D, Christophe C, Vermeylen C, Kagambega F, Corazza F, Devalck C, Dresse MF, Hunninck K, Klein A, LePQ, Loop M, Maes P, Philippet P, Sariban E, Van Geet C, Ferster A. Hydroxyurea for sickle cell disease in children and for prevention of cerebrovascular events: the Belgian experience. *Blood*. 2005 April 1; 105(7): 2685-90.
20. Gebreyohannis M, Adams RJ. Sickle cell disease: primary stroke prevention. *CNS Spectr*. 2004 June 9(6): 445-9.

Author Information

Deepak Pahuja, M.D.

Michigan State University College of Human Medicine, Hurley Medical Center

Manoharan W. Eustace, M.D.

Hurley Medical Center

Priyanka Chadha, M.B.B.S.