

Sialo-Oral Fistula

S Aravind Warriar, S Sathasivasubramanian

Citation

S Aravind Warriar, S Sathasivasubramanian. *Sialo-Oral Fistula*. The Internet Journal of Dental Science. 2008 Volume 7 Number 2.

Abstract

Sialolithiasis is one of the common diseases which is encountered in the salivary glands and is one of the major causes of salivary gland disorders. The cause for the sialolith remains obscure, but may be caused due to local irritants, inflammation, certain medications etc. The formation of stones in the large salivary glands occurs in 80% of cases in the submandibular salivary gland and only 20% in the parotid gland. Sialolithiasis is most commonly seen in middle aged patients. There are several complication due to sialolithiasis and one of the rarest among them is sialo-oral fistula. The formation of sialo-oral fistula in the floor of the mouth is rare. The present article reports on a rare case of sialo-oral fistula in a middle aged patient.

INTRODUCTION

Salivary gland fistulae are troublesome complications that may occur mainly after trauma (knife or razor cuts, gunshot wounds or road traffic accidents) or surgery, they can be also caused by stones. ¹ Sialolithiasis is the most common disease of the submandibular glands. ²³ Involved gland can be enlarged and tender. Stasis of saliva can lead to infection, fibrosis and gland atrophy. Fistulae, a sinus tract or ulceration may occur over a stone in chronic cases. ⁴⁵

CASE REPORT

A 31 year old male patient had come to the department of oral medicine and radiology at Sri Ramachandra Dental College with a chief complaint of mild pain and swelling in relation to the right lower side of the neck for the past 15-20 days. Pain is mild but continuous in nature. Patient had similar episodes 12 & 4 years ago, during which, he did not visit any doctor. He also gives a history of mild reduction in saliva for the past 7 years. No history of exacerbation of swelling on consumption of food.

On clinical examination, no obvious swelling was noted extraorally. (Fig-1)

Figure 1

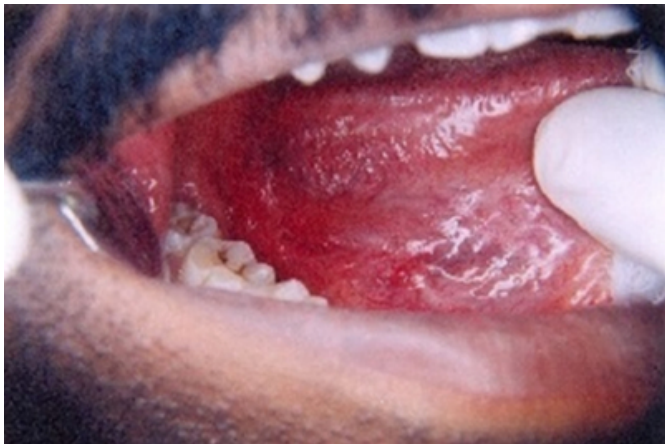Fig.1- Facial profile



Intraorally the floor of the mouth was apparently normal, except in the right posterior lingual aspect in relation to third molar a linear cleft was evident. (Fig-2)

Figure 2

Fig.2- Right posterior lingual aspect of floor of mouth relation to 3 molar, showing the linear cleft



The area was mildly tender. On stimulation, no salivary flow was evident from the submandibular duct. On bimanual palpation of the superficial lobe of the right submandibular gland a small nodule like material was palpable roughly measuring about 0.5 cm in diameter. Keeping the chief complaint, history, and the clinical picture in mind a provisional diagnosis of right submandibular sialolith\ salivary fistula was made.

Gutta percha of size number 25 and length 30mm was introduced gently in the linear cleft (Fig-3), following which occlusal radiograph was taken, which revealed the presence of submandibular sialolith with gutta percha almost approaching the sialolith.(Fig-4)

Figure 3

Fig.3- Right posterior lingual aspect of floor of mouth in relation to 3 molar, showing gutta percha inserted in the linear cleft

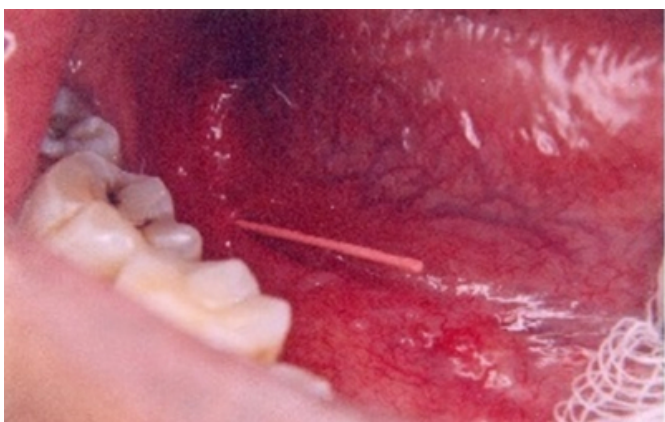
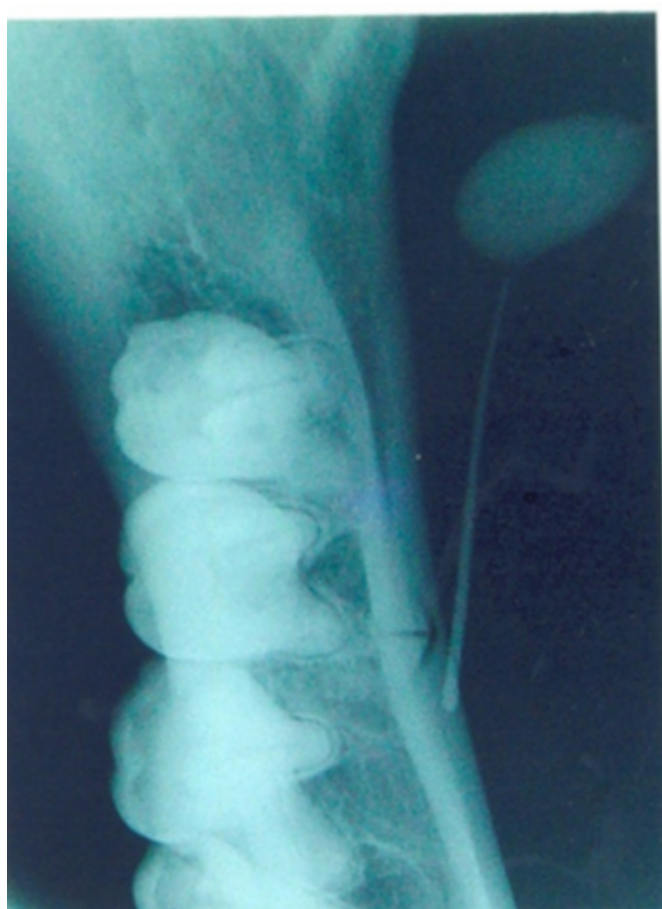

Figure 4

Fig.4- Occlusal radiograph revealing the presence of submandibular sialolith with gutta percha almost approaching the sialolith

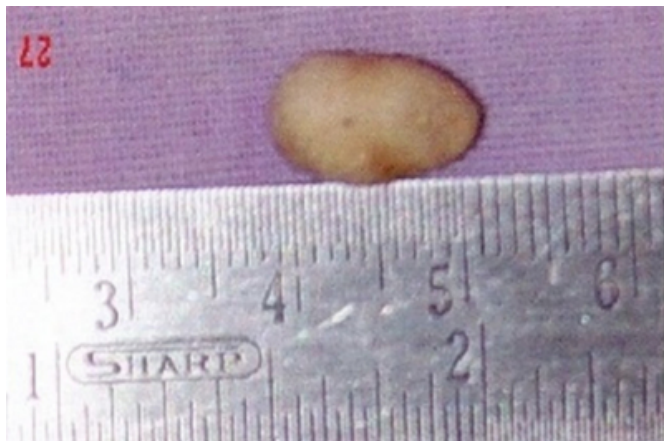

After the radiographic examination a final diagnosis of sialo-oral fistula of the right submandibular gland was made.

After the patients consent excisional biopsy of the right submandibular gland was done in our hospital. Sialolith measuring about 1cm in diameter was present. (Fig-5)

Figure 5

Fig.5- Sialolith measuring 1cm in diameter



It was sent for biochemical examination which revealed the presence of calcium, phosphorus and oxalate. Patient reported back after one month with no obvious complaint, except for the scar in the sutured area.

DISCUSSION

Sialolithiasis affects men more frequently than women in their middle age. ⁶ Sialoliths are calcified and organic matter which is formed within the secretory system of the major salivary gland. It is believed that the higher rate of sialolith formation in the submandibular gland is due to (1) the tortuous course of Wharton's duct, (2) higher calcium and phosphate levels, and (3) the dependent position of the submandibular glands. The etiology sialolith formation remains unknown, however several factors that leads to stone formation, which includes inflammation, irregularities in the duct system, local irritants, and anti-cholenergic medications. ³⁴⁷⁸

Patients with sialoliths most commonly present with a history of acute painful and intermittent swelling of the affected major salivary gland. Typically, eating will initiate salivary gland swelling. The stone totally or partially blocks the flow of saliva, causing salivary pooling within the ducts and gland body. Since the glands are encapsulated, there is little space for expansion, and enlargement causes pain. ⁴⁵⁹ Our patient had given a history of reduction in saliva for past 7 years, it may be due to the atrophy of the salivary gland due to its chronic condition and mild pain due to a low grade infection. Bimanual palpation of the floor of the mouth, in a posterior to anterior direction reveals a palpable stone in large number of cases of submandibular calculi formation. ¹⁰¹¹

The sialoliths could be of varying sizes. Vittal, Udagatti,

Subhash Chandra et al reported the case of sialolith with enormous size (60mm x 50mm) responsible for the submandibular swelling, which indicates a very long formative period. This is the largest asymptomatic submandibular sialolith ever reported in the literature. ⁶ Raskin, described a sialolith measuring 55mm in length. ¹² Hubar reported heaviest stone weighing 17.5gm. ¹³ Paul and Chauhan have reported a megalith with a dimension of 4.5cms x 2 cms and dry weight of 4.230 gm associated with a sialocutaneous and a sialo-oral fistulae. In our case sialolith was measuring about 1cm in diameter. Sialolithiasis is rarely associated with pressure symptoms resulting in sinuses or fistula. The formation of sialo-oral fistula in the floor of the mouth is rare. The pressure exerted by the enlarging stone on the oral mucosa is probably the cause. ¹⁴

Sialoliths are primarily composed of hydroxyapatite. The chemical composition is calcium, phosphate and carbon, with trace amounts of magnesium, potassium chloride and ammonium. Fifty percent of parotid sialoliths and twenty percent of submandibular sialolith are poorly calcified. ⁴¹⁵¹⁶ An occlusal view is recommended view for radiography of submandibular glands. ²¹⁷ In our case we have taken an occlusal radiograph. Other investigation methods were not employed as the occlusal radiograph clearly defined the presence of stone and also considering the financial constraints of the patient. Computed tomography has 10 times the sensitivity of plain-flim radiography for detecting calcifications. ⁴ Sialography is useful in patients showing signs of sialadenitis related to radiolucent stones or deep submandibular/parotid stones. ⁹¹⁵ Yoshimura Y et al, have recommended that preoperative technetium-99m pertechnetate scintigraphy be obtained to determine how functional the gland is and thus to determine its treatment. ¹⁸

Standard care includes analgesics, hydration, antibiotics, and antipyretics as necessary. ⁴ If the stone is sufficiently forward it can be milked and manipulated through the duct orifice. Almost half of the submandibular calculi are in the distal third of the duct and amenable to simple surgical release through incision in the floor of the mouth. ⁹¹⁹ If the stone lies in the intraglandular portion of the duct, it is recommended that entire gland be removed. Lithotripsy is gaining popularity because it offers a noninvasive treatment for sialolith. ⁴ In our case complete excision of the right submandibular gland was done via extraoral approach.

References

1. S.Salerno, F.Cannizzao, A.Lo.Castro, B.Barrsi & R.Speciale: The value of MRI in a fistula of Wharton's duct,

Dento-Maxillo Facial Radiology, 29:125-127,2000

2. Altan Yildirim: Case of giant sialolith of the submandibular salivary gland, Journal of Laryngol Otol, 109: 767-769, 1995
3. Levy.D.M, Remine.W.H, Devine.K.D: Salivary gland calculi, Journal of American medical association, 181: 1115-1119,1962
4. Burket, Oral medicine diagnosis & treatment,(10th edition), B.C.Decker Inc, 2003
5. Stanley.M.W, Bordaes.R.H, Benke.J, et al: Sialolithiasis differential diagnostic problems in fine needle aspiration cytology,Am J clin pathol, 106(2):229-233,1996
6. Vittal, Udagatti, Subhash Chandra et al: Giant sialolith(megalith) of submandibular salivary gland, Journal of Laryngology and Otology, 109: 767-769, 1997
7. Mandel.I.P, Wotnans: The salivary secretions in health and disease, Oral Sci Rev, 8:25-47, 1976
8. Haring.J.I. Diagnosing salivary stones: J Am Dent Assoc, 122(8): 75-76, 1991 Lustman J , Ageve .E , Melamed Y Sialolithiasis : a survey of 245 patients and review of the literature, Int J Oral Maxillofacial Surgery 19:135, 1990
9. Lustman J , Ageve .E , Melamed Y Sialolithiasis : a survey of 245 patients and review of the literature, Int J Oral Maxillofacial Surgery 19:135, 1990
10. J.Siddiquil: Sialolithiasis: an unusually large

submandibular salivary stone. British dental journal, 193:89-91, 2002

11. Williams M F: Sialolithiasis.Otolaryngologic Clinics of North America, 32:819-834, 1999
12. Raskin.S.Z, Gould.S.M, Williams.A.C: Submandibular duct sialolith of unusual size and shape, Journal of oral surgery, 33:142-145,1975
13. Hubar J.S, Guggenheimer J.,Evan M: Megalith, Oral Surgery Oral Medicine and Oral Pathology, 70:245, 1990
14. Paul D. Chauhan SR: Salivary megalith with a sialo-cutaneous and sialo-oral fistula : a case report, The Journal of Laryngology and Otology, 109:767-769, 1997
15. Burstein LS et al: The crystal chemistry of submandibular and parotid salivary gland stones, Journal of Oral Pathology, 8:284, 1976
16. Strubel.G, Rzepka-Glinder.V: Structure and composition of sialoliths, J Clin Chem Clin Biochem, 27:244, 1989
17. van den Akker HP: Diagnostic imaging in salivary gland disease, Oral Surg Oral Med Oral Pathol, 66:625-37, 1988
18. Yoshimura Y , Morishita T , Sugihara T: Salivary gland function after sialolithiasis, Scintigraphic examination of submandibular glands with 99mTc-pertechnetate, J Oral Maxillofac Surg, 47:704-10, 1989
19. McGurk M, Esudier M: Removing salivary stones, Br J Hosp Med, 54:184-185, 1995

Author Information

S. Aravind Warriar, M.D.S.

Lecturer, Dept of Oral Medicine & Radiology, Dental College Zliten, Al Margeb University

S. Sathasivasubramanian, M.D.S

Professor and H.O.D, Dept of Oral Medicine & Radiology, Sri Ramachandra Dental College, Sri Ramachandra University