

# Giant cell tumor of the tendon sheath in a knee

M Sukeik, P Sharda, S Maheswaran

## Citation

M Sukeik, P Sharda, S Maheswaran. *Giant cell tumor of the tendon sheath in a knee*. The Internet Journal of Orthopedic Surgery. 2007 Volume 9 Number 2.

## Abstract

Giant cell tumor of the tendon sheath is an idiopathic benign tumor of the synovial membrane which is rarely seen in large joints. We report a case of a giant cell tumor of the tendon sheath in a knee which presented with persistent anterior knee pain and swelling after trivial injury to the knee with emphasis on the importance of considering such tumors in the differential diagnosis of patients presenting with knee pain and swelling.

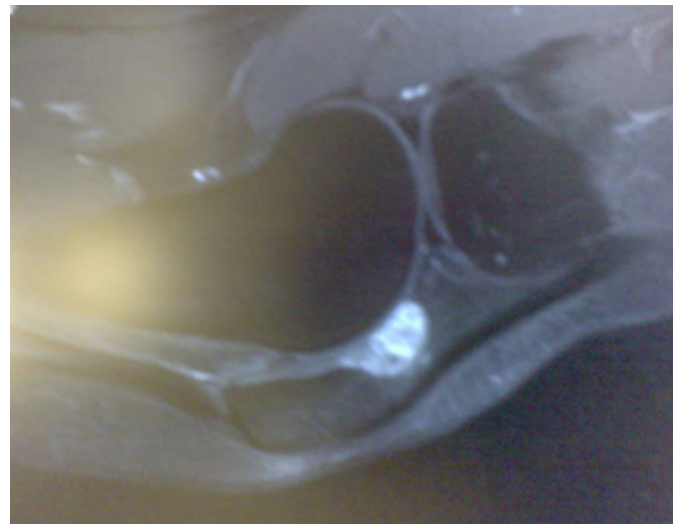
## CASE

A 50-year-old woman normally fit and healthy presented to her general practitioner after a trivial injury to the left knee with persistent anterior knee pain. Physical examination revealed tenderness over the lateral aspect of the patella but with a full range of movement of the knee and a negative McMurray's test. X-rays were normal. She was treated with standard painkillers and quadriceps exercises. After 6 months of conservative management, the patient did not improve. An MRI scan was performed and showed a soft tissue mass, with a differential diagnosis of pigmented villonodular synovitis (PVNS) (fig1, 2). The patient was consequently referred to us for further evaluation and management. We performed an arthroscopy that revealed a bulging mass into the knee joint and a miniature arthrotomy was required to excise the mass completely.

Morphologically it looked like a PVNS, but subsequent histology confirmed a giant cell tumor of the tendon sheath (GCTTS) (fig3). The post-operative period was uneventful and there was no evidence of local recurrence on follow up after one year.

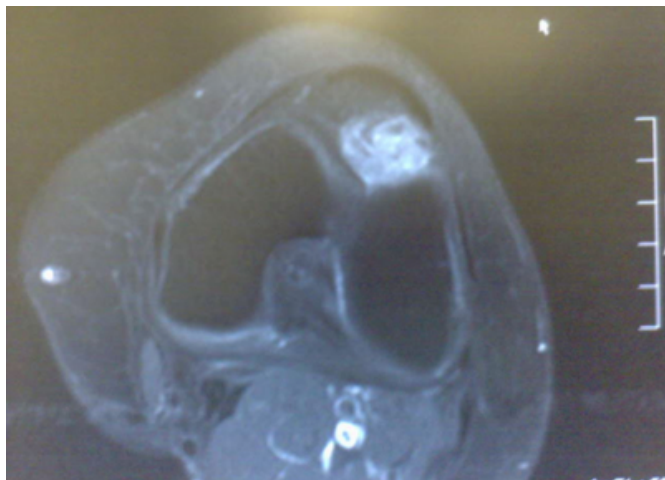
## Figure 1

Figure 1



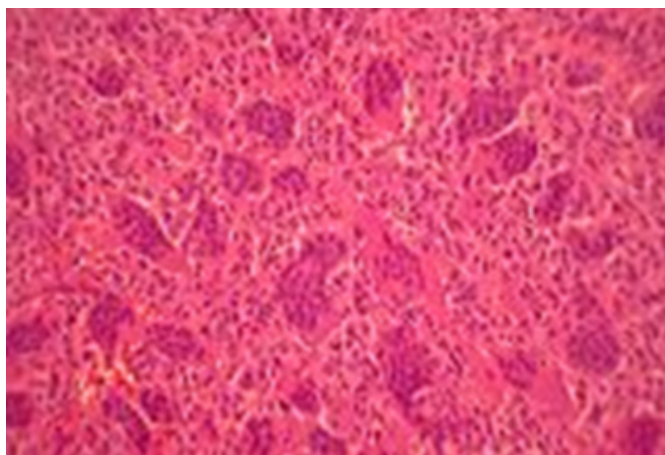
**Figure 2**

Figure 2



**Figure 3**

Figure 3



## DISCUSSION

GCTTS is an idiopathic benign tumor of the synovial membrane and is one of the most common soft tissue tumors in the hand<sup>1, 2</sup>. However, it is seen rarely in large joints<sup>3</sup>. It usually affects adults with a peak incidence in the third to fifth decades of life and is more often seen in women than in men<sup>4,5,6</sup>. It usually presents with soft-tissue swelling and pain<sup>7, 8</sup>. GCTTS is a slowly proliferative tumor that may infiltrate the overlying dermis and erode the bone by pressure or direct invasion<sup>9, 10, 11</sup>. Although rare, a malignant GCTTS can occur<sup>12</sup>. Most giant-cell tumors are treated with surgical excision. The reported recurrence rate varies from approximately 10–20%<sup>7, 13</sup>. In rare, aggressive lesions, local

recurrence may necessitate resection and radiation therapy<sup>7</sup>.

Our case report emphasizes the importance of considering GCTTS in the differential diagnosis of soft tissue swelling and pain in large joints.

## CORRESPONDENCE TO

Mr. Mohamed Sukeik M.D, MRCS Senior House Officer in Trauma & Orthopaedics University Hospital of North Tees, Stockton on Tees, TS20 2AY, United Kingdom Tel: 0044-7792126571 Fax: 0044-1642624978 E-mail: msukeik@hotmail.com

## References

1. Peimer CA. Surgery of the hand. In: Schwartz SI, Shires GT, Spencer FC, Daly JM, Fischer JE, Galloway A, eds. Principles of surgery, 7th ed. New York, NY: McGraw-Hill, 1998:2078
2. Llauger J, Palmer J, Roson N, Cremades R, Bague S. Pigmented villonodular synovitis and giant cell tumors of the tendon sheath: radiologic and pathologic features. *AJR*1999; 172:1087 -1091
3. Rosenberg A. Soft tissue tumors and tumor like lesions. In: Cotran RS, Kumar V, Collins T, eds. Robbins Pathologic Basis of Disease. 6th ed. Philadelphia, Pa: Saunders; 1999:1258-1259.
4. Ushijima M, Hashimoto H, Tsuneyoshi M, Enjoji M. Giant cell tumor of the tendon sheath (nodular tenosynovitis). *Cancer* 1986;57:875-84.
5. Oyemade GAA, Abioye AA. A clinicopathologic review of benign giant cell tumors of tendon sheaths in Ibadan, Nigeria. *Am J Surg* 1977;134:392-5.
6. Karasick D, Karasick S. Giant cell tumor of tendon sheath: spectrum of radiologic findings. *Skeletal Radiol* 1992;21: 219-24.
7. Martin RC 2nd, Osborne DL, Edwards MJ, Wrightson W, McMasters KM. Giant cell tumor of tendon sheath, tenosynovial giant cell tumor, and pigmented villonodular synovitis: defining the presentation, surgical therapy and recurrence. *Oncol Rep*2000; 7:413 -419. (7)
8. Glowacki KA, Weiss AP. Giant cell tumors of tendon sheath. *Hand Clin* 1995;11:245 -253. (8)
9. King DT, Millman AJ, Gurevitch AW, Hirose FM. Giantcell tumor of the tendon sheath involving skin. *Arch Dermatol* 1978;114:944-946. (9)
10. Fletcher AG, Horn RC. Giant-cell tumors of tendon sheath origin. A consideration of bone involvement and report of two cases with extensive bone destruction. *Ann Surg* 1951;133:374-385. (10)
11. Booth KC, et al. Giant cell tumor of tendon sheath with intraosseous invasive case report. *J Hand Surg* 1995;20A:1000-1002. (11)
12. Carstens PHB, Howell RS. Malignant giant cell tumor of tendon sheath. *Virchows Arch A Pathol Anat Histopathol* 1979;382:237-43. (12)
13. Al-Qattan MM. Giant cell tumors of tendon sheath: classification and recurrence rate. *J Hand Surg (Br)*2001; 26:72 -75 (13)

**Author Information**

**Mohamed Sukeik, MD, MRCS**

Senior House Officer in Orthopaedics, Department of Trauma and Orthopaedics, University Hospital of North Tees

**Praveen Sharda, MRCS. M.S. Orth**

Staff Orthopaedic Surgeon, Department of Trauma and Orthopaedics, University Hospital of North Tees

**Shanmuga Maheswaran, FRCS, MCh ORTH**

Consultant Orthopaedic Surgeon, Department of Trauma and Orthopaedics, University Hospital of North Tees