

Deep Neck Space Infections

H K Velankar, P Sancheti, N Mody, Y G Dabholkar, S B Bhalekar, A Saberwal

Citation

H K Velankar, P Sancheti, N Mody, Y G Dabholkar, S B Bhalekar, A Saberwal. *Deep Neck Space Infections*. The Internet Journal of Otorhinolaryngology. 2016 Volume 18 Number 1.

DOI: [10.5580/IJORL.33689](https://doi.org/10.5580/IJORL.33689)

Abstract

This is a case series of 100 patients with deep neck spaces infections, to study its etiology, clinical course, morbidity and mortality. The study was conducted over 5 years and emphasised on the importance of early diagnosis and management of deep neck space infections. This entity is still one of the major health hazard in the field of modern otolaryngology because of their potentially devastating complications as well as the new challenges posed by AIDS epidemic and the resurgence of tuberculosis.

INTRODUCTION

The anatomy of deep neck spaces is highly complex and makes the precise localisation of infections difficult in this region.^{1,2} Superficial tissues have to be crossed to gain surgical access to these spaces, placing all the intervening neurovascular and soft tissue structures at risk.^{1,2,3,4} Suppurative thrombophlebitis, vascular erosion, osteomyelitis are few potential sequelae.⁵

The deep cervical fascia is divided into the superficial or investing layer, the middle or visceral layer and the deep layer, which also known as the prevertebral layer. The deep neck spaces can be divided into those involving the entire length of the neck (the retropharyngeal space, the danger space and the prevertebral space), the ones that are limited to above the hyoid bone (the submaxillary, the sublingual and the parapharyngeal spaces) and below the hyoid bone, limited to the anterior visceral space. These neck spaces can frequently confine and limit the spread of suppurative infections. The infection may gain access to increasingly larger portions of the neck and can also extend to other portions of the body (e.g. - mediastinum, coccyx), placing areas outside of the head and neck at risk, as the spaces are interconnected.^{6,7,8}

REPORT

The study consisted of 100 patients with deep neck space infections. It occurred in all age groups ranging from 4 years to 77 years of age. Significant majority was seen in 41 to 50 years of age (22 percent) and females outnumbered males in

this study (54 females and 46 males). Most common site of presentation was submandibular space (47 percent), followed by peritonsillar space (16 percent), lateral cervical space (14 percent), retropharyngeal space (10 percent), parotid space (9 percent) and Para pharyngeal space (4 percent).

Figure 1

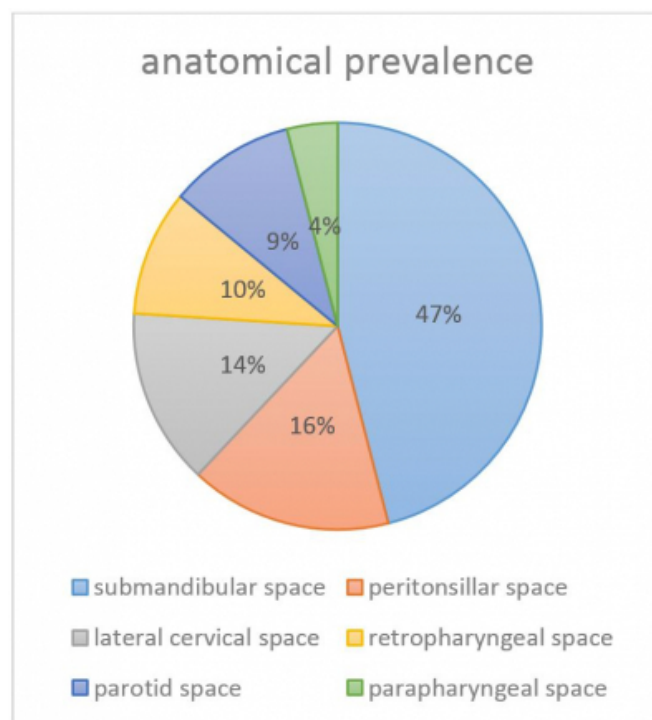
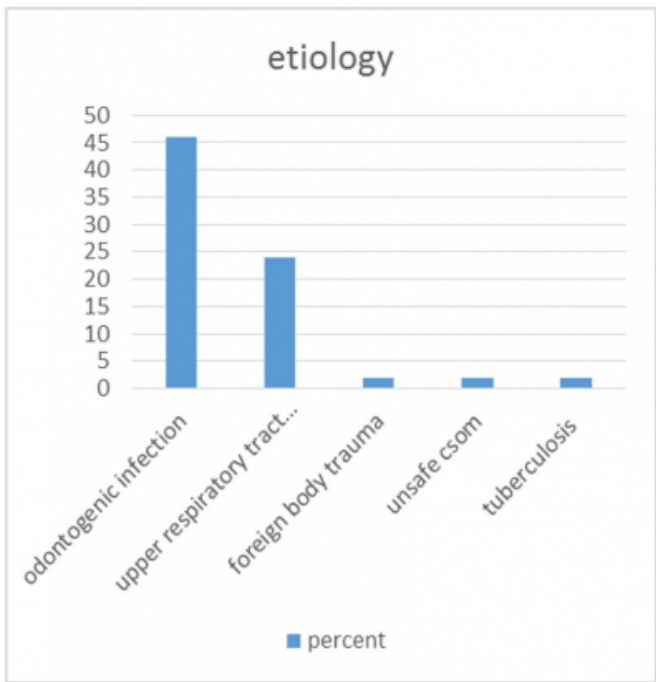


Figure 2



Odontogenic infection/recent dental procedure was the most common predisposing factor seen in 46 patients (46 percent). 24 patients had upper respiratory tract infection. 2 patients had a history of foreign body trauma while 2 had unsafe chronic suppurative otitis media. 2 patients had positive history of tuberculosis contact. 1 patient complained of insect bite in neck prior to abscess formation and needed emergency tracheostomy for dyspnoea.

Blood profile of these patients showed an increase in total leucocyte count. There was lymphocytosis and high erythrocyte sedimentation rate levels in patients having a cold abscess. In HIV positive patients there was leucopenia though there were acute infections.

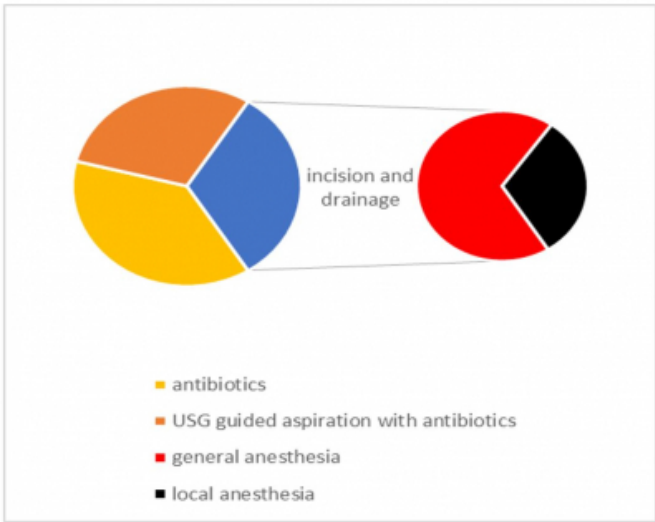
Diabetes mellitus was present in 28 percent of the patients. 4 patients were diagnosed on routine preoperative assessment for incision and drainage of abscess under general anesthesia and 4 were already known cases of diabetes. 6 patients tested positive for HIV by ELISA test, 4 of which had mediastinitis. 2 patients were a known case of pulmonary tuberculosis for which AKT was being given and another 12 patients were diagnosed with extra pulmonary tuberculosis in form of tuberculous lymphadenitis.

Most common organisms causing deep neck space infections were group A beta haemolytic streptococcal organisms (*Streptococcus pyogenes*), and *Staphylococcus aureus*. *Pseudomonas* and *Klebsiella* were specially seen in diabetic

patients and HIV positive patients. Many pus cultures showed a polymicrobial flora. No growth was seen in 4 cases.

38 patients responded to intravenous antibiotics alone. 30 patients with pus pockets diagnosed on ultrasonography were treated with ultrasonography guided aspiration and concurrent antibiotics. 32 patients having frank abscess clinically needed incision and drainage of abscess along with intravenous antibiotics. The 32 patients were taken up for incision and drainage, 10 of them were retropharyngeal abscesses drained under local anesthesia and rest 22 patients were taken under general anesthesia. Out of these 22 patients, 5 had undergone emergency tracheostomy for airway compromise and 12 needed elective tracheostomy before giving general anesthesia in view of difficult intubation.

Figure 3



Post-operative cavity healing was managed with intravenous antibiotics and daily dressing. Wound healing was monitored on 7th, 15th day and 1 month. Post-operative wound cavity healing was good in 20 patients at end of 7 days. There was delayed cavity healing in 8 patients, which healed by secondary intention by 15 days in 4 patients and within one month in 2 patients. Incidence of delayed healing cavity post operatively was seen in 6 cases out of which 4 were diabetic, in whom skin necrosis and secondary infection was seen and 2 were HIV positive. The 2 HIV positive patients had parotid abscess and salivary fistula was seen in them post operatively, one of which had a recurrence in 5 months. Both these patients were lost on follow up at the end of 6 months.

Internal jugular vein thrombosis was seen in one patient having Bezolds abscess with cholesteatoma. The same patient had severe dyspnoea requiring emergency tracheostomy. Patient was treated with intravenous antibiotics and incision and drainage. Modified radical mastoidectomy was done after 48 hours. Patient was asymptomatic at 6 months follow up.

Follow up of patients was done after 15 days, 21 days, 1 month, 3 months and after 6 months. The predisposing factors like odontogenic or oropharyngeal were taken care of in these months. There was recurrence of Ludwigs angina in 2 patients who did not undergo dental procedure as advised.

DISCUSSION

For centuries, the complex anatomy of deep neck spaces, and its infections have challenged physicians and surgeons. The pathophysiology and management of deep neck space infections is based upon the fascial layers and resulting deep spaces of the neck.

In Francis B Quinn. Jr. et al, an analysis of 150 patients, the average age of the patients presenting with Deep Neck Space infections was between 40 to 50 years.⁹ A study of 185 cases of deep neck space infections by Huang TT et al, 97 patients (52.4%) were observed to be older than 50 years. Odontogenic infections and upper airway infections were the most common causes of deep neck space infections (53.2% and 30.5% of the known causes). Pus cultures revealed *Streptococcus viridans* and *Klebsiella pneumoniae* as the most common organisms (33.9%, 33.9%). In patients with diabetes mellitus, *Klebsiella pneumoniae* was also the most common organism (56.1%).¹⁰ In a study by Gidley PW, *Streptococcus*, *Staphylococcus*, *Bacteroides*, *Micrococcus* and *Neisseria* were the most common organisms isolated. Gram negative organisms was the etiology in very few cases.¹¹ The Huang TT et al study showed the Para pharyngeal space (38.4%) was most commonly involved.¹⁰ The same study showed 30 patients (16.2%) had major complications during admission, and among them, 18 patients had to undergo emergency tracheostomy. Delayed wound healing was observed to be more in diabetic patients and those having multiple space infections. 33% of diabetic patients had complications and two of three mortalities in the study were diabetic patients.^{10,12} There were 63 patients (34.1%) with associated systemic disease, with 88.9% (56/63) of those having diabetes mellitus.^{10,12,13} In Plaza Mayor et al study of 31 patients of deep neck space infections, medical treatment was successful in 90.32% (28

patients).¹⁴ Mc Clay et al study also showed that the use of intravenous antibiotics alone in paediatric patients, with definitive abscess on CT Scan, was effective in clinically stable patients.¹⁵ With early diagnosis of cellulitis of deep neck spaces and proper use of antibiotics, more and more cases can be treated by only medical management.¹⁶

CONCLUSION

Odontogenic origin is the most common etiology in adults, today. In spite of advent of broad spectrum antibiotics and new modalities of imaging, complications like airway compromise necessitating emergency tracheostomy, mediastinitis, and internal jugular vein thrombosis do occur. We have become more efficient in the diagnosis and management of these infections due to advances in technology, today.

References

1. Scott Brown's Otorhinolaryngology and Head and Neck Surgery (7th edition) volume 2: part 14- The Neck 1739-1753.
2. Paonessa, DF, Goldstein JC. Anatomy and Physiology of Head and Neck Infections (with emphasis on the Fascia of the Face and Neck). *Otolaryng. Clin N Am.* 1976;9(3): 561-580
3. Greys anatomy 38th edition: chapter 7- Deep Neck Spaces Pg 802-847
4. Stalfors J, Adielsson A, Ebenfelt A. Deep Neck Space infections remain a surgical challenge. A study of 72 patients. *Acta Otolaryngol.* Dec 2004;124(10):1191-1196
5. Alexander DW, Leonard JR, Trail ML. Vascular complications of deep neck abscesses. A report of four cases. *Laryngoscope.* Mar 1968;78(3):361-70.
6. Coller FA, Yglesias L. The relation of the spread of infection to fascial planes in the neck and thorax. *Surgery.* 1937;1:323-337.
7. Linder HH. The anatomy of the fasciae of the face and neck with particular reference to the spread and treatment of intraoral infections (Ludwig's) that have progressed into adjacent fascial spaces. *Ann Surg.* Dec 1986;204(6): 705-14
8. Chaudhary, N, Agarwal, S, Rai, A. Descending Necrotising Mediastinitis: Trends in a Developing country. *Ear Nose Throat.* 2005 84(4):242-250
9. Francis B Quinn, Jr, MD Mathew W, Ryan: Deep Neck Spaces and Infections. A study of 150 cases. *Laryngoscope* 2000;107(5):775-777
10. Huang TT, Liu TC, Chen PR. Deep neck infection: analysis of 185 cases. *Head and Neck.* Oct 2004;26(10):854-60
11. Gidley PW, Ghorayeb BY, Steirnerberg CM. Contemporary management of deep neck space infections. *Otolaryngol Head and Neck Surg* 1997;116(1):16-22.
12. Huang TT, Liu Tc, Chen PR. Deep Neck Infections in Deep Neck Infections in Diabetic patients: comparison of Clinical picture and Outcomes with Nondiabetic Patients. *Otolaryngology Head and Neck Surgery* 2005;13:943-947
13. Chen MK, Wen YS, Chang CC. Deep neck infections in diabetic patients. *Am J Otolaryngol.* May-Jun 2000;21(3):169-73
14. Plaza Mayor G, Martinez-San Millan J, Martinez-Vidal A. Is conservative treatment of deep neck space infections

appropriate? Head Neck 2001;23(2):126-33

15. McClay JE, Murray AD, Booth T. Intravenous antibiotic therapy for deep neck abscesses defined by computed tomography. Arch Otolaryngol Head Neck Surg. Nov

2003;129(11):1207-12

16. Gianoli GJ, Espinola TE, Guarisco JL, Miller RH. Retropharyngeal space infection: changing trends.

Otolaryngol Head and Neck Surg. Jul 1991;105(1):92-100

Author Information

Haritosh K. Velankar, MBBS, MS(ENT), Professor and Head of Department of Otorhinolaryngology

Dr. D. Y. Patil Hospital and Research Centre

Navi Mumbai, Maharashtra, India

drharitosh@yahoo.co.in

Pooja Sancheti, MBBS, MS(ENT- Postgraduate resident), Second Year Post Graduate Resident

Dr. D. Y. Patil Hospital and Research Centre

Navi Mumbai, Maharashtra, India

drpoojasancheti@hotmail.com

Nirav Mody, MBBS, MS(ENT), Post graduate Student

Dr. D. Y. Patil Hospital and Research Centre

Navi Mumbai, Maharashtra, India

drniravmody@yahoo.com

Yogesh G. Dabholkar, MBBS, MS(ENT), Professor at Department of Otorhinolaryngology

Dr. D. Y. Patil Hospital and Research Centre

Navi Mumbai, Maharashtra, India

ygsh@yahoo.com

Sharad B. Bhalekar, MBBS, MS(ENT), Associate Professor at Department of Otorhinolaryngology

Dr. D. Y. Patil Hospital and Research Centre

Navi Mumbai, Maharashtra, India

sharadbhalekar2@gmail.com

Akanksha Saberwal, MBBS, MS(ENT), Assistant Professor at Department of Otorhinolaryngology

Dr. D. Y. Patil Hospital and Research Centre

Navi Mumbai, Maharashtra, India

dr.akanksha.s@gmail.com