

Concomitant Occurrence of the Left Atrial Myxoma and Gastrointestinal Stromal Tumor (GIST): A Case Report

Q Shafiq, I Mohamed

Citation

Q Shafiq, I Mohamed. *Concomitant Occurrence of the Left Atrial Myxoma and Gastrointestinal Stromal Tumor (GIST): A Case Report*. The Internet Journal of Cardiology. 2008 Volume 7 Number 2.

Abstract

Atrial Myxoma is the most common benign primary tumor of the heart. Its reported incidence is 0.5 per million population [1]. The incidence of Intra-abdominal Sarcomas is around 15% and out of these 80% are Gastrointestinal stromal tumors (GIST) [2]. To our knowledge, in the English language literature, concomitant occurrence of the left Atrial Myxoma and GIST has not been reported. Our patient is a 59 year old Hispanic female who was diagnosed with a high grade GIST located on the rectovaginal septum. She was treated surgically followed by adjuvant therapy with Imatinib. One year after the discontinuation of the Imatinib, she developed a local recurrence of her tumor and was simultaneously found to have a left atrial myxoma demonstrated by cardiac echocardiogram. She underwent successful resection of the left atrial myxoma. The locally recurrent GIST regressed six months after treatment with Imatinib.

INTRODUCTION

Atrial myxoma is the most common benign primary cardiac tumor usually occurring among middle age adults.

Compared to men, sporadic Atrial myxomas are more common in women (65%) [3]. Familial cases of Atrial Myxoma have been reported in 4.5 to 10% of the cases [4]. Carney Syndrome is thought to be responsible for most of the familial cases of cardiac myxoma and may represent as many as 7% of all the cases [4]. Carney Syndrome is an autosomal dominant syndrome characterized by

Cardiac myxoma formation, spotty skin pigmentation, endocrine hyperactivity and other tumors such as testicular Sertoli cell tumor, psammomatous melanotic schwannoma, pituitary adenoma, and thyroid tumors. The association of GIST with Atrial Myxoma as a component of Carney syndrome has not been described in the English language literature.

A Carney's triad (gastrointestinal stromal tumors, pulmonary chondromas, and paragangliomas) has been described in the literature as well. This is considered a separate pathological entity [5]. Again, there is no reference to the concomitant presence of the atrial myxoma with GIST.

Our patient was diagnosed with a high grade GIST and had concomitantly presented with a left atrial myxoma. The exact genetic association is not known, and this case may

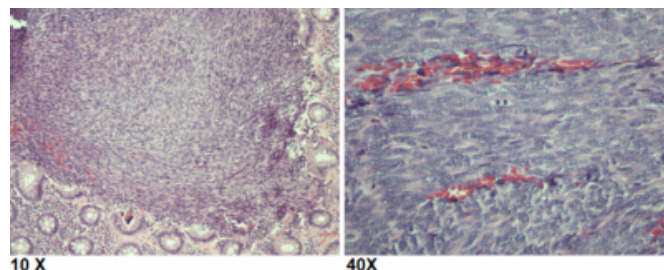
represent an incidental finding or a variant of a syndrome such as Carney's syndrome or triad.

CASE REPORT

The patient is a 59 years old Hispanic female with no past medical or family history of neoplasm. She was noted to have a tumor located on rectovaginal septum which was diagnosed following an abnormal pap smear during routine annual cervical cancer screening. The patient underwent resection of the involved colorectal section, colostomy and hysterectomy. Gross examination of the resected tumor showed a 1.5 x 1.4 x 1.3 cm tumor with involvement of the surgical margins. Microscopic examination of the resected tissue showed high grade (Grade III) gastrointestinal stromal tumor [Figure 1].

Figure 1

Figure 1. Histological section of colon showing gastrointestinal stromal Tumor at 10X and 40 X magnifications



On Immunohistochemical staining the tumor cells were positive for c-kit (CD117), CD34 and actin, but were negative for S-100, HMB-45, MART, Factor VIII and desmin. After the surgery, she was treated with adjuvant Imatinib for four years.

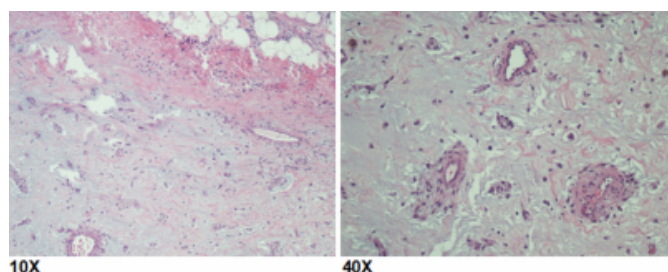
After one year of the discontinuation of Imatinib the patient developed local recurrence

of the GIST detected by a follow up CT scan and confirmed with a PETCT scan. She simultaneously described a vague chest pain and a cardiac echocardiogram was requested. A left atrial intra-cardiac mass attached to the secundum part of the

inter-atrial septum was demonstrated. The locally recurrent GIST was treated with Imatinib. The patient underwent a successful resection of the left atrial mass. Gross examination of the resected left atrial mass showed a 2.4 x 0.9 x 1.4 cm tumor. Microscopic examination showed stellate-shaped cells within an extensive myxoid stroma. Proliferation of the capillaries and some lymphocytes and plasma cells were also found [Figure 2].

Figure 2

Figure 2. Histological section of atrial myxoma showing stellate-shaped cells within an extensive myxoid stroma at 10X and 40 X magnifications



Immunohistochemical staining of the myxoma cells for c-kit (CD117) was negative. Her postoperative course was uneventful.

A repeat CT scan of the abdomen and pelvis approximately six months later showed regression of the locally recurrent disease and no evidence of any new metastatic lesion.

DISCUSSION

Cardiac Myxomas occur most commonly in the left atrium. According to a recent meta-analysis 83 % of the cardiac myxomas occur in the left atrium, 12.7 occur in the right atrium and 1.3 percent are biatrial. The occurrence in the ventricles is uncommon [3]. The majority of cardiac

myxomas are solitary, although multiple tumors can be seen especially in the setting of the Carney Syndrome. Cardiac myxomas are usually attached to the interatrial septum in the region of the fossa ovalis [6] [7]. Histologically, a cardiac myxoma contains sparsely distributed uniform spindle- and stellate shaped cells within an extensive myxoid stroma [8]. The cardiac myxomas associated with Carney syndrome and sporadic cases are histologically indistinguishable [9]. Histochemically, both the stroma and the tumor cells stain positive with PAS, whereas only the stroma shows positive staining with the Alcian blue. Immunohistochemically, the stromal tumor cells show positive reaction to vimentin, however, variably positive to S-100 and NSE [10]. There are cases where calretinin and IL-6 have been used to differentiate between embolic myxoma and myxoid thrombus [11] [12]. Atrial Myxomas have never been reported to be positive for keratin or c-Kit. This patient's atrial myxoma was also negative for c-Kit. The recurrence rate of atrial myxoma associated with Carney syndrome after surgical resection is about 20% as compared to sporadic tumors which recur in about 3% of the cases [9]. GISTs represent about 80% of the sarcomas that arise from the gastrointestinal tract. In 95% of the cases these tumors are positive for c-Kit (CD117) [2]. Our patient's GIST tumor cells were also positive for c-kit (CD117), CD34 and actin, however, negative for S-100, HMB-45, MART, Factor VIII and desmin.

The current management of GIST includes resection of the tumor and adjuvant treatment with Imatinib. Imatinib (marketed as Gleevec® in USA and Glivec® in Europe/Australia) functions as an inhibitor of several tyrosine kinase enzymes including TK domain in abl, c-kit and PDGF-R. In case of treatment failure, the usual sites of recurrence are peritoneum, liver or sometimes both sites. Very rarely, the tumor could metastasize to the lungs [2]. A rare concomitant occurrence of the GIST with pulmonary chondromas and paragangliomas has been described as a "Carney's Triad". However, there is no prior description of concomitant occurrence of Atrial Myxoma and GIST in the English language literature. To our knowledge we are reporting the first such case where Atrial myxoma was diagnosed in a patient with GIST tumor. The exact pathological correlation of concomitant occurrence is not known and it may just be a coincidence or a variant of Carney Syndrome or triad.

References

1. Burke A, Virmani R: Fascicle 16, 3rd series: Tumors of the heart and the great vessels. Atlas of Tumor Pathology, Washington, DC, Armed Forces Institute of Pathology, 1996.
2. Abeloff MD, et al. Abeloff's clinical oncology. 4th ed. Churchill Livingstone. 2008. Chapter 97.
3. Kuon E, Kreplin M, Weiss W, Dahm JB: The challenge presented by right atrial myxoma. Herz 2004; 29:702.
4. Wilkes D, Charitakis K, Basson CT: Inherited disposition to cardiac myxoma development. Nat Rev Cancer 2006; 6:157.
5. Dajee A, Dajee H, Hinrichs S, Lillington G. Pulmonary chondroma, extraadrenal paraganglioma, and gastric leiomyosarcoma: Carney's triad. J Thorac Cardiovasc Surg. 1982 Sep;84(3):377-81.
6. Pinede L, Duhaut P, Loire R: Clinical presentation of left atrial cardiac myxoma. A series of 112 consecutive cases. Medicine (Baltimore) 2001; 80:159.
7. Ipek G, Erentug V, Bozbuga N, et al: Surgical management of cardiac myxoma. J Card Surg 2005; 20:300.
8. Grebenc ML, Rosado-de-Christenson ML, Green CE, et al: Cardiac myxoma: Imaging features in 83 patients. Radiographics 2002; 22:673.
9. Aspres N, Bleasel NR, Stapleton KM: Genetic testing of the family with a Carney-complex member leads to successful early removal of an asymptomatic atrial myxoma in the mother of the patient. Australas J Dermatol 2003; 44:121.
10. Pucci A, Gagliardotto P, Zanini C, et al: Histopathologic and clinical characterization of cardiac myxoma: Review of 53 cases from a single institution. Am Heart J 2000; 140:134.
11. Acebo E, Val-Bernal JF, Gomez-Roman JJ, Revuelta JM: Clinicopathologic study and DNA analysis of 37 cardiac myxomas: A 28-year experience. Chest 2003; 123:1379.
12. Val-Bernal JF, Acebo E, Gomez-Roman JJ, Garijo MF: Anticipated diagnosis of left atrial myxoma following histological investigation of limb embolectomy specimens: A report of two cases. Pathol Int 2003; 53:489.

Author Information

Qaiser Shafiq, MD

Department of Internal Medicine University of Toledo Medical Center Toledo, OH 43614, USA

Iman Mohamed, MD, MRCP (UK), FACP, MPH

Chief Division of Hematology & Oncology Department of Internal Medicine University of Toledo Medical Center Toledo, OH 43614, USA