

Diagnosis Of Multiple Endocrine Neoplasia Type 1 In A Patient With Back Pain; Case Report And Review Of Literature

C Gutierrez, C Lopez, R Lind, V Mohan

Citation

C Gutierrez, C Lopez, R Lind, V Mohan. *Diagnosis Of Multiple Endocrine Neoplasia Type 1 In A Patient With Back Pain; Case Report And Review Of Literature*. The Internet Journal of Internal Medicine. 2008 Volume 8 Number 1.

Abstract

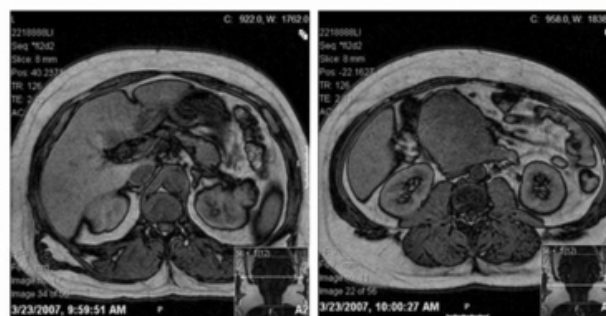
Multiple endocrine neoplasia syndrome 1 (MEN1) is a paracrine genetic autosomal dominant disease consisting of tumors in parathyroid, pancreas and pituitary glands. We report a case of a 44 year old male with MEN1 presenting insulinomas, parathyroid adenomas and a pituitary prolactin producing microadenoma. A 44 year old male presented to the emergency department with complaints of back pain. Initial imaging of the abdomen to rule out nephrolithiasis showed an 11cm mass at the head of the pancreas. On further questioning, the patient reported to have frequent symptoms suggestive of hypoglycemia for more than 20 years. Laboratory data on admission showed low glucose (46 mg/dl) and high calcium (12 mg/dl). A 72 hour fasting test confirmed the diagnosis of insulinoma. Hypercalcemia work-up revealed an elevated PTH (Calcium 12.6 mg/dl and PTH 200 pg/ml); a parathyroid scan showed multiple adenomas. A pituitary MRI did not reveal any tumors. However, labs were remarkable for decreased total testosterone (144 ng/dl), and elevated prolactin (104 ug/L). CT-guided biopsy of the mass at the head of the pancreas was consistent with a neuroendocrine tumor. The patient subsequently underwent resection of the pancreatic mass and parathyroidectomy. His hypercalcemia resolved after surgery and his hyperprolactinemia improved with dopamine agonist therapy. Unfortunately, his hypoglycemia did not resolve. We report the case of a 44 year old male patient with a new presentation of tumors of the parathyroid, pancreas and pituitary glands. Excellent history taking, further testing, and clinical suspicion lead to the diagnosis of MEN1 syndrome.

CASE PRESENTATION

A 44 year old male presented to the Emergency Department complaining of severe left flank and back pain of approximately 1 month duration. Nephrolithiasis was suspected and further workup was performed. An abdominal CT scan failed to demonstrate renal calculi, but was remarkable for an 11 centimeter mass at the head of the pancreas, a 2 centimeter mass at the tail of the pancreas, and portal hepatic lymph nodes (figure 1). The patient was admitted for further evaluation of these abdominal masses. Initial laboratory data noted hypoglycemia (glucose of 46 mg/dL) and hypercalcemia (calcium of 12 mg/dL).

Figure 1

Imaging Pancreatic mass



On further questioning, the patient reported to have frequent episodes of dizziness and sweating for more than 20 years. He had grown accustomed to these spells and would often ingest candy to prevent or resolve the symptoms. He had never before sought medical attention for these episodes. He denied any previous diagnosis of diabetes, use of insulin, oral hypoglycemics, herbal remedies or other prescription medications. He also reported decreased libido for the past

few years. Physical exam revealed a well-nourished, obese male in no distress. Vital signs were stable. His skin exam was remarkable for acanthosis nigricans, and no masses were palpable on abdominal examination. The rest of his physical exam was within normal limits. His family history was remarkable for type 2 diabetes in his mother and colon cancer in his aunt.

A 72 hour fast was initiated and within 12 hours the patient had a symptomatic hypoglycemic episode. Simultaneous laboratory testing confirmed the diagnosis of insulinoma (glucose 35 mg/dl, insulin 17 IU/ml, pro-insulin 27.8 pmol/L, c-peptide 3.3 ng/ml, sulfonylurea screen negative, ketones negative, post-glucagon glucose 93 mg/dl).

A hypercalcemia work-up was also pursued, revealing both elevated calcium (12.6 mg/dl) and PTH (200 pg/ml) levels. A parathyroid scan revealed intense radiotracer activity in the upper and lower left poles, suggestive of adenomas. To evaluate for pituitary involvement, pituitary imaging and anterior pituitary hormone levels were obtained. The pituitary MRI did not reveal any tumors. However, findings of decreased total testosterone (144 ng/dl) and elevated prolactin (104 ug/L), were indicative of a microprolactinoma. The remainder of the anterior pituitary function was normal.

CT-guided biopsy of the mass at the head of the pancreas was consistent with a neuroendocrine tumor. The patient subsequently underwent a modified Whipple procedure to resect the 11 centimeter mass in the pancreatic head and a three and one half gland parathyroidectomy. His hypercalcemia resolved after surgery and his hyperprolactinemia improved with dopamine agonist therapy. His back pain, which was likely secondary to compression of the celiac plexus from the pancreatic mass, improved after surgery. Unfortunately, his hypoglycemia did not resolve.

Genetic screening for MEN1 was positive, showing a known mutation in the MEN1 gene. The patient continues to receive medical treatment, and his children have been referred for genetic counseling.

REVIEW OF LITERATURE

MEN1 syndrome is a rare genetic autosomal dominant disease, with an incidence of 2 in 100000 (1, 2). It consists of tumors of three glands; parathyroid, pancreas, and anterior pituitary (3). At least two gland involvement is required to

make the diagnosis. The disease originates from mutations of the MEN1 gene, which codes for the menin protein found on chromosome 11q13 (4, 5). The function of this protein is not fully understood but is thought to be important for tumor suppression. Patients with MEN1 usually present with detectable gene mutations (up to 75% of cases) (3). Failure of detection of this mutation in MEN1 kindred does not rule out the possibility carrier status, but reflects mutations located at unrecognized sites of the gene (3, 6). There is currently little evidence that early screening of asymptomatic family members will reduce morbidity or mortality in MEN1 (6). However, if one decides to screen family members of affected individuals, measurement of serum calcium is the most cost-effective approach (6).

Hyperparathyroidism is the most common finding in MEN1 patients and presents with over 90% penetrance by the age of 50 (1, 7). Hyperparathyroidism in MEN1 is usually associated with multiple adenomas, which is consistent with our patient's findings. Treatment for hyperparathyroidism is aggressive surgical resection. Indications for surgery include symptomatic or marked hypercalcemia, nephrolithiasis, or diminished bone density (7). Surgery however, is also considered an acceptable alternative for patients with asymptomatic hypercalcemia in MEN1 (1). Initial surgery often involves three and one-half gland removal and occasionally thymectomy to resect possible intrathymic parathyroid glands (8). Recurrence is common and is as high as 30% (2, 8).

The second most common finding in MEN1 patients, comprising almost 70% of the cases, are enteropancreatic tumors (1, 3). The most common type of tumor is a gastrinoma (Zollinger Ellison Syndrome). Patients with MEN1 and Zollinger Ellison Syndrome have higher incidence of esophageal stricture, Barrett's esophagus and dysplasia when compared to patients with only Zollinger Ellison Syndrome (11). Insulinomas, as our patient had, are usually small, multiple and are less common. The diagnosis of insulinoma depends upon the documentation of symptomatic hypoglycemia that is reversed by the administration of glucose. These findings should be accompanied with inappropriately normal or elevated serum insulin concentrations (9). The preferred treatment for insulinoma is surgery. However, treatment is complicated by the possible presence of multiple small insulinomas and continuing risk of persistent hypoglycemia even after surgery (1, 9). Therefore, it is recommended that patients

undergo excision of tumors at the head of the pancreas as well as a distal sub-total pancreatectomy (9). In our case, removal of the mass at the head of the pancreas did not resolve the hypoglycemia. The other pancreatic masses were not resected during the initial procedure due to concern for intraoperative complications. Re-exploration was discussed with the patient, but he has refused further surgery at this time.

Approximately 15-20% of MEN1 patients have clinically apparent pituitary tumors (3). MEN1 pituitary tumors share the same clinical profile as sporadic tumors (2). The most common is a prolactinoma, but GH-secreting, ACTH-secreting, and non-secreting tumors can occur (3, 10). Our patient had typical laboratory and imaging findings consistent with a microprolactinoma. Treatment for prolactinomas in MEN1 should be no different as of isolated prolactinomas; initial medical therapy with dopamine agonists is the treatment of choice (1). If treatment is successful, it is important to continue regular biochemical evaluation of the pituitary for possible recurrence (3).

We report the case of a 44 year old male patient with a presentation of a very rare disease, MEN1 syndrome. He had evidence of tumors of the parathyroid, pancreas and pituitary glands. Usually MEN1 patients are first diagnosed when they present with hypercalcemia. Our patient's diagnosis was made only after he presented with back and flank pain, and imaging of his abdomen incidentally noted multiple abdominal tumors. Careful history taking, clinical suspicion, and further testing led to making an important diagnosis. This case is a good reminder of how a patient can present with common symptoms, but may in fact have a very unusual and uncommon disease underlying the condition.

LIST OF ABBREVIATIONS

MEN1- Multiple Endocrine Neoplasia 1

CT scan- Computer tomography scan

MRI- Magnetic Resonance Imaging

PTH- Parathyroid hormone

LH- Luteinizing hormone

FSH- Follicle-stimulating hormone

GH-Growth hormone

ACTH- Adrenocorticotrophic hormone

References

1. Doherty, G.M. Multiple endocrine neoplasia type 1. *J Surg Oncol* . 2005;89:143-150.
2. Schussheim, D.H., M.C. Skarulis, S.K. Agarwal, et.al. Multiple endocrine neoplasia type 1: new clinical and basic findings. *Trends Endocrinol Metab*. 2001; 12:173-178.
3. Brandi, M.L., R.F. Gagel, A. Angeli, et.al. Guidelines for diagnosis and therapy of MEN type 1 and type 2. *J Clin Endocrinol Metab*. 2001; 86:5658-5671.
4. Balogh, K., K. Racz, A. Patocs, et.al. Menin and its interacting proteins: elucidation of menin function. *Trends Endocrinol Metab*. 2006; 17:357-364.
5. Hoff, A.O., O.M. Hauache. Multiple endocrine neoplasia type 1 (MEN 1): clinical, biochemical and molecular diagnosis and treatment of the associated disturbances]. *Arq Bras Endocrinol Metabol*. 2005; 49:735-746.
6. Burgess, J.R., T.M. Greenaway, and J.J. Shepherd. Expression of the MEN-1 gene in a large kindred with multiple endocrine neoplasia type 1. *J Intern Med*. 1998; 243:465-470.
7. Malone, J.P., A. Srivastava, and R. Khardori. Hyperparathyroidism and multiple endocrine neoplasia. *Otolaryngol Clin North Am*. 2004; 37:715-736, viii.
8. Lambert, L.A., S.E. Shapiro, J.E. Lee, et.al. Surgical treatment of hyperparathyroidism in patients with multiple endocrine neoplasia type 1. *Arch Surg*. 2005; 140:374-382.
9. Grant, C.S. Insulinoma. *Best Pract Res Clin Gastroenterol*. 2005; 19:783-798.
10. Hao, W., M.C. Skarulis, W.F. Simonds, et.al: Multiple endocrine neoplasia type 1 variant with frequent prolactinoma and rare gastrinoma. *J Clin Endocrinol Metab*. 2004; 89:3776-3784.
11. Pipeleers-Marichal, M, Somers, G, Willems, G, et al. Gastrinomas in the duodenums of patients with multiple endocrine neoplasia type 1 and the Zollinger-Ellison syndrome. *N Engl J Med*. 1990; 322:723.

Author Information

Cristina Gutierrez, MD

Lincoln Hospital Affiliated with Weill Medical College of Cornell University House Staff, Department of Internal Medicine
234 East 149th Street Bronx, New York 10451 USA

Cesar A Lopez, MD

Lincoln Hospital Affiliated with Weill Medical College of Cornell University House Staff, Department of Internal Medicine
234 East 149th Street Bronx, New York 10451 USA

Robert Lind, MD

New York University School of Medicine Assistant Professor, Division of Endocrinology, Diabetes, and Metabolism 301
East 17th Street New York, New York 10003 USA

Vinuta Mohan, MD

Lincoln Hospital Affiliated with Weill Medical College of Cornell University Assistant Professor, Department of Internal
Medicine 234 East 149th Street Bronx, New York 10451 USA