

Jejunal Atresia and Cystic Fibrosis in a Newborn Male Infant: A Case Report

P Katzman, J Villalona, T Rossi, M Brown

Citation

P Katzman, J Villalona, T Rossi, M Brown. *Jejunal Atresia and Cystic Fibrosis in a Newborn Male Infant: A Case Report*. The Internet Journal of Pediatrics and Neonatology. 2008 Volume 9 Number 2.

Abstract

Intestinal atresia is largely a surgical disease and therefore most case reports have been the subjects of surgical reports. We present a case of an infant with cystic fibrosis associated with meconium ileus and jejunal atresia with histologic evidence supporting the vascular accident theory.

CLINICAL HISTORY

A full-term (38 1/2 weeks) male infant was found on prenatal ultrasound to have an enlarging peritoneal cystic structure and had a markedly distended abdomen at birth. Gastrografin enemas demonstrated a microcolon with some impacted meconium pellets, no migration of contrast material into the distal small intestine and no passage of meconium. On day of life 2 he had exploratory laparotomy secondary to meconium ileus. The abdominal cavity contained numerous adhesions associated with volvulus, meconium peritonitis, and perforation of an atretic distal jejunal segment. The appendix and proximal end of the ileum were sampled and ganglion cells were identified in both specimens on intraoperative frozen section. Jejunal resection with proximal jejunostomy and an end ileal mucous fistula were performed. An 18 cm segment of residual terminal ileum was salvaged with an intact ileocecal valve. The proximal bowel measured 61 cm in length beginning at the ligament of Treitz to the level of the exteriorized jejunal enterostomy. Although the jejunal-ileal re-anastomosis was reconnected 2 months later, it appeared to be obstructed less than one month after the procedure and lysis of adhesions was required. The patient had newborn screen positive for cystic fibrosis and confirmatory mutation analysis. Due to the bowel resection the child developed short bowel syndrome and liver failure. At about a year of age the patient required liver, small bowel, stomach, and pancreas transplantation. He has had an uncomplicated post-transplant course but at age 5 he is well below the 5th percentile for age for both weight (13.1 kg) and height (87 cm).

PATHOLOGY

The jejunal surgical specimen contained a 7.5 x 5.5 x 1 cm perforated blind pouch that narrowed to a fibrous band. Microscopically, the blind pouch contained a loss of mucosa (Figure 1A, along edge with arrow) with submucosal fibrosis, and an attenuated muscularis propria (Figure 1B, arrow) associated with hemosiderin-laden macrophages as shown on hematoxylin-eosin (Figure 1C) and iron stain (Figure 1D) (both figures, thin arrow). Inspissated mucus of the type seen in cystic fibrosis was admixed with meconium in this region of the specimen (Figure 2). Ganglion cells were present at all levels of the specimen that were examined.

Figure 1

Figure 1: Atretic jejunal segment shows mucosal epithelial loss (arrow), submucosal fibrosis and hemorrhage, and muscularis propria atrophy consistent with ischemic injury (H+E, 12.5x). Focally the attenuated muscularis is seen to disappear amidst fibrosis (arrow) (H+E, 40x). Evidence of injury includes hemosiderin-laden macrophages (H+E, 100x) that are seen more clearly on iron stain (thin arrow, and) to accumulate adjacent to the residual muscularis propria (thick arrow, and) (, Iron stain, 100x).

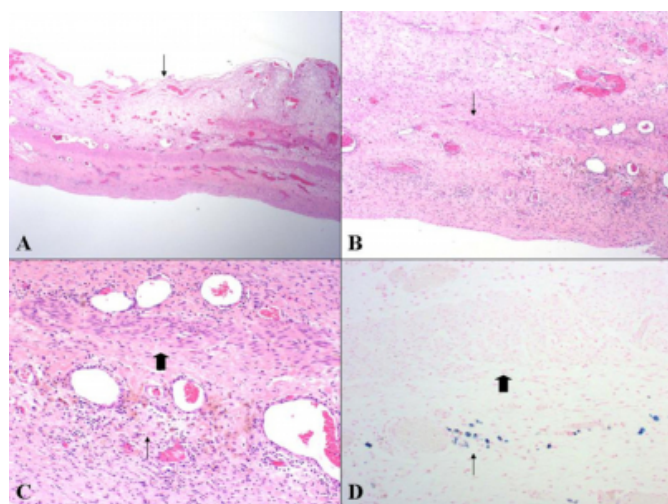
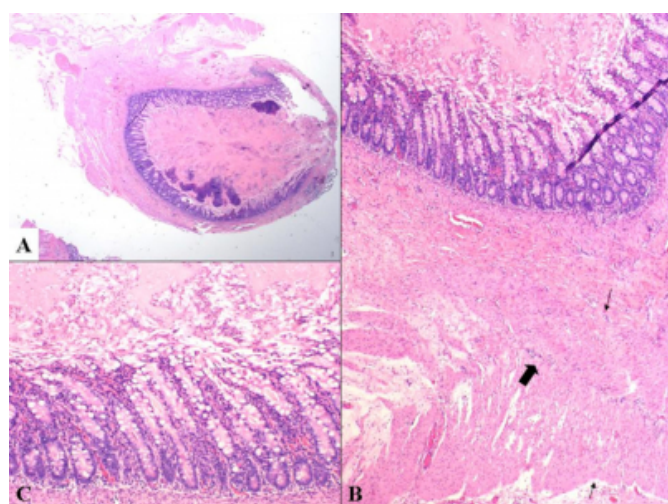


Figure 2

Figure 2: Cross-section of jejunum with lumen containing inspissated mucus (H+E, 12.5x). Muscularis propria appears of normal thickness (between thin arrows), and with intermyenteric ganglion cells (thick arrow) in this segment of jejunum proximal to the atretic lesion (H+E, 100x). Higher power photomicrograph shows pink inspissated mucus in the mucosal crypts (H+E, 200x).



DISCUSSION

Intestinal atresia has been, to a large extent, a subject of the surgical literature because it is a surgically treated disease

[1,2,3,4,5,6]. This case provides pathological evidence supporting the generally accepted theory that was established by the early work of Louw and Barnard [7], that most jejunal and ileal atresias are due to a vascular accident with resorption of previously developed bowel. Loss of mucosa, an attenuated muscle layer, and hemosiderin-laden macrophages are consistent with prior injury. The presence of meconium in the distal ileum also supports the notion that the proximal bowel had been patent prior to injury [1]. The cause for bowel ischemia in any individual case is not always clear, but any insult that compromises the superior mesenteric blood supply to the small bowel can cause single or multiple atresias. In cystic fibrosis, meconium ileus may provide a nidus for volvulus [8]. In this case, as has been described in a past report [5], there was distal ileal sparing probably due to retrograde blood flow from either the right colic or ileocolic artery.

Congenital atresias of the small intestine are malformations that almost always present in the immediate postnatal period with persistent vomiting, absent stools, and distended abdomen, although intestinal stenosis may not be identified until solid food becomes part of the diet [9]. Whereas duodenal atresia is most often a congenital malformation that occurs due to failure of recanalization of the solid epithelial plug of the precursor to the gut in embryogenesis, jejunal and ileal atresias have been shown to arise from a fetal vascular accident secondary to intussusception, fetal umbilical defect, or persistent omphalomesenteric duct [4]. Similarly, whereas duodenal atresia is often associated with other congenital anomalies and can be seen in up to 25% of cases of trisomy 21 [9,10], jejunal and ileal atresias usually occur in otherwise normal newborns.

This patient's underlying disease was cystic fibrosis that was complicated by meconium ileus, bowel perforation with meconium peritonitis, volvulus, and jejunal atresia. Meconium ileus is seen in up to 20% of patients with cystic fibrosis and accompanying intestinal atresias occur in a subset of these patients [9]. This patient, who was at high risk for cystic fibrosis with carrier parents, had three unaffected siblings. He had the typical inspissated eosinophilic mucus in the intestinal lumen and mucosal crypts seen in cystic fibrosis patients (Figure 3). Hirschsprung disease and pancreatic and biliary duct abnormalities can also be associated with both meconium ileus and bowel atresia [9]. Pseudo-meconium ileus due to antenatal cytomegalovirus infection has also been described [11].

Cystic fibrosis is an autosomal recessive trait caused by the mutation of the cystic fibrosis transmembrane regulator (CFTR) gene on chromosome 7. Although the most common mutation creates a defective protein at position 508 (F508), numerous other mutations have been identified [12]. The mutation results in decreased transport of chloride, sodium, and water in the epithelial cells that line the gastrointestinal, pancreatobiliary, respiratory, and reproductive tracts [12]. This defect results in viscous secretions, luminal obstruction and scarring, and altered defense mechanisms. Dysfunction of the gastrointestinal tract is the most common presentation in infancy, but pulmonary and upper respiratory tract pathology can develop with time. Meconium ileus, the most severe early complication of the disease, can lead to bowel perforation and meconium peritonitis. The need for early multiorgan transplant after bowel resection before deterioration of pulmonary function has been addressed by Fidell JA et al [13]. In 2003 they published that the 1- and 5-year composite graft survival was 67% and 47% with the majority no longer needing total parental nutrition [13]. They also note that the need for these types of grafts may become more commonplace as prophylactic treatment for pulmonary disease postpones the need for lung transplant.

This report has identified a case of jejunal atresia in a patient with cystic fibrosis complicated by meconium ileus and meconium peritonitis. The histologic findings in this patient's bowel resection specimen at day 2 of life support the theory that a vascular accident in pre-existing bowel is the etiology of jejunal atresias. The patient's outcome of short gut syndrome with subsequent need for multiorgan

transplant is unusual but is a more recognized treatment in this subgroup of cystic fibrosis patients.

References

1. Santulli TV, Blanc WA. Congenital atresia of the intestine: pathogenesis and treatment. *Ann Surg* 1961;154(6):939-48.
2. Weitzman JJ, Vanderhoof RS. Jejunal atresia with agenesis of the dorsal mesentery with "Christmas tree" deformity of the small intestine. *Am J Surg* 1966;111:443-9.
3. DeLorimier AA, Fonkalsrud EW, Hays DM. Congenital atresia and stenosis of the jejunum and ileum. *Surg* 1969;65(5):819-27.
4. Nixon HH, Tawes R. Etiology and treatment of small intestinal atresia: analysis of a series of 127 jejunoileal atresias and comparison with 62 duodenal atresias. *Surg* 1971;69(1):41-51.
5. Zerella JT, Martin LW. Jejunal atresia with absent mesentery and a helical ileum. *Surg* 1976;80(5):550-3.
6. Dalla Vecchia LK, Grosfeld JL, West KW, Rescorla FJ, Scherer LR, Engum SA. Intestinal atresia and stenosis: a 25-year experience with 277 cases. *Arch Surg* 1998;133:490-7.
7. Louw JH, Barnard CN. Congenital intestinal atresia: observations on its origin. *Lancet* 1955; Nov. 19:1065-7.
8. Roberts HE, Cragan JD, Cono J, Khoury MJ, Weatherly MR, Moore CA. Increased frequency of cystic fibrosis among infants with jejunoileal atresia. *Am J Med Genet* 1998;78:446-9.
9. Dahms, BB. Gastrointestinal tract and pancreas in: Gilbert-Barness, E, ed. *Potter's Pathology of the Fetus and Infant*, Mosby, New York, 1997, 774-822.
10. Bates MD, Deutsch GH. Molecular insights in to congenital disorders of the digestive system. *Pediatr Develop Pathol* 2003;6:284-98.
11. Dechelotte PJ, Mulliez NM, Bouvier RJ, Vanlierferinghen PC, Lemery DJ. Pseudo-meconium ileus due to cytomegalovirus infection: a report of three cases. *Pediatr Pathol* 1992;12:73-82.
12. Lewis MJ, Lewis EH III, Amos JA, Tsongalis GJ. Cystic fibrosis. *Am J Clin Pathol* 2003;120(Suppl):S3-S13.
13. Fidell JA, Mazariegos GV, Orenstein D, Sindhi R, Reyes J. Liver and intestinal transplantation in a child with cystic fibrosis: a case report. *Pediatr Transplant* 2003;7:240-2.

Author Information

Philip J. Katzman, MD

Department of Pathology and Laboratory Medicine, University of Rochester Medical Center

Juan Villalona, MD

Division of Pediatric Gastroenterology, Virginia Commonwealth University Children's Medical Center

Thomas M. Rossi, MD

Department of Pediatrics, Division of Pediatric Gastroenterology/Nutrition, University of Rochester Medical Center

Marilyn R. Brown, MD

Department of Pediatrics, Division of Pediatric Gastroenterology/Nutrition, University of Rochester Medical Center