

Difficult Diagnosis in a Case of Pulmonary and Peritoneal Sarcoidosis

L Burke, J Badie

Citation

L Burke, J Badie. *Difficult Diagnosis in a Case of Pulmonary and Peritoneal Sarcoidosis*. The Internet Journal of Pulmonary Medicine. 2008 Volume 11 Number 2.

Abstract

Pulmonary and associated peritoneal sarcoidosis is a rare presentation. A 49-year-old man presented with persistent cough and exertional dyspnoea. Following radiological and pathological investigations he was diagnosed with pulmonary fibrosis related to previous dust exposure in the textile industry. Histology was reported to show chronic inflammation, fibrosis, and foreign body giant cells, but no granulomas. Two years later white spots were seen on the peritoneal surface during a routine right inguinal hernia repair. These were biopsied and showed a few neat well-defined granulomata. He continued to complain of breathlessness, and was referred back to the respiratory physicians. Further investigation revealed bilateral ground glass shadowing on HRCT, and re-examination of the original transbronchial biopsy revealed further findings consistent with a diagnosis of sarcoidosis. The patient was started on oral prednisolone to good effect. This case illustrates the importance of reviewing the patient history and investigations to diagnose patients with persistent symptomatology.

CASE REPORT

In 2004, a 49-year-old male was referred by the ENT surgeons with persistent cough. He gave a 9-month history of cough, mainly dry in nature, but occasionally productive of yellow sputum, especially in the morning. He was breathless on strenuous exertion and had experienced a left sided chest ache along with bilateral knee joint pains. There was also a history of 10kg weight loss over the last 9 months. Past medical history revealed hypertension and there was a family history of ischaemic heart disease and diabetes.

This gentleman was born in East Africa and brought up in India, and came to the UK in his mid-teens. He married and currently works as a shop keeper. Prior to this he worked in a textile mill as a weaver for 20 years. Here he had significant dust exposure. He is a never smoker and drinks about 36 units of alcohol per week.

On examination there was evidence of mild conjunctivitis, but no lymphadenopathy. Cardiovascular system was normal and on auscultation of the chest there were bibasal inspiratory crackles.

INVESTIGATIONS

Chest radiograph showed hazy diffuse miliary shadowing and a suggestion of right paratracheal lymphadenopathy. In

addition, CT confirmed diffuse, fine reticulo-nodular opacities bilaterally, with septal thickening towards the bases in association with ground glass change and some right paratracheal, aortopulmonary and subcarinal lymphadenopathy (Figure 1).

Figure 1

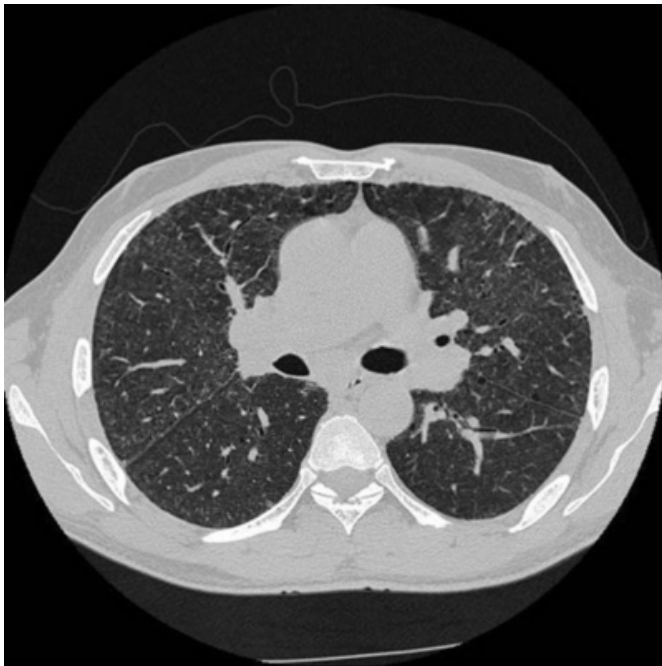

Figure 1. Lymphadenopathy, ground glass change and subtle beading with nodules.

Autoimmune and RAST testing were negative, and U+Es, FBC, glucose, LFTs and aspergillous antibodies were normal. Serum ACE was 172 (range 8-52). Heaf test was negative and he had a BCG scar. He went on to have a transbronchial biopsy which showed chronic inflammation and fibrosis and foreign body giant cells, but no granulomas. Full pulmonary function tests revealed normal spirometry with reduced lung volumes (RV 58% predicted, TLC 69% predicted, TLCO 53% predicted and KCO 84% predicted). It was felt at this point that the appearances on his CT were consistent with his previous dust exposure and not sarcoidosis.

FURTHER INVESTIGATION AND MANAGEMENT

Two years later he went onto have a right inguinal hernia repair. During the operation white nodules were noted on the peritoneal surface and consequently biopsied. Again this showed chronic inflammation (foreign body reaction). He was re-referred to a respiratory physician at this time and he described further increase in his breathlessness with an exercise tolerance of about 15m and he was also noted to be clubbed. A second CT suggested progression in ground glass change at the bases. He was started on corticosteroid treatment and a bronchoscopy was arranged. Endobronchial biopsy was done and showed giant cells, granuloma and Schaumann bodies consistent with advanced-stage sarcoidosis (Figure 2).

Figure 2

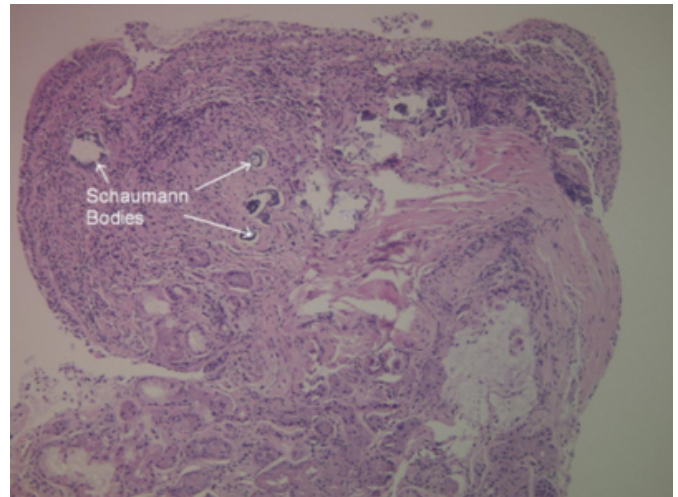


Figure 2. Bronchial biopsy showing rounded calcified material (Schaumann Bodies) but no granulomas.

The original transbronchial biopsies were re-reviewed. Foreign body type giant cells with refringent material within them were readily identified. In addition tiny granulomas with giant cells were seen (Figure 3).

Figure 3

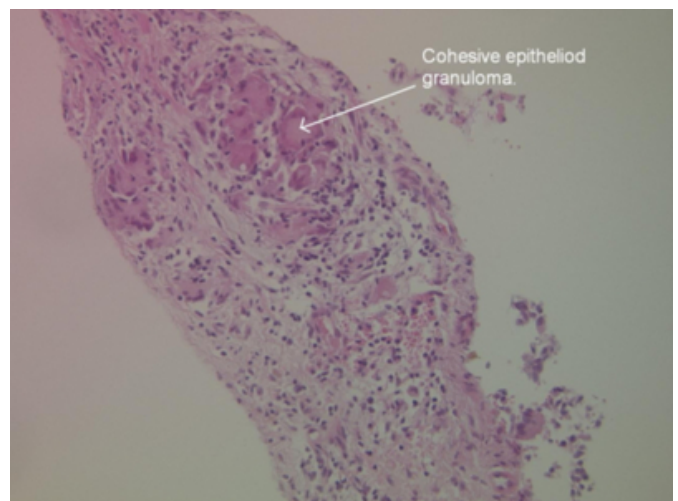


Figure 3. Cohesive epithelioid granuloma is present in a bronchial biopsy.

This appearance could represent sarcoidosis. The peritoneal biopsy was also reviewed. It showed collections of foreign body type giant cells together with a few well defined neat granulomata (Figure 4).

Figure 4

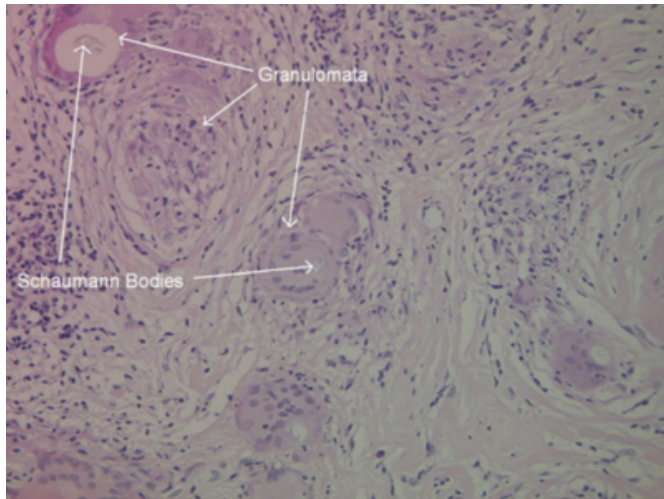


Figure 4. Peritoneal biopsy showing a small, well-defined, epithelioid granuloma with multiple Langerhans giant cells in the background. Several of the giant cells contain calcified material (Schaumann Bodies).

Currently he has had some improvement in his symptoms and is now weaning off steroids. A recent CT showed significant improvement in the widespread ground glass change and mediastinal lymphadenopathy. This case illustrates the importance of reviewing the patient history and investigations to diagnose patients with persistent symptomatology.

PULMONARY AND PERITONEAL SARCOIDOSIS

Pulmonary and associated peritoneal peritonitis is an unusual presentation. Sarcoidosis is a granulomatous disorder of unknown cause, affecting multiple organs, most commonly lung, eye and skin. Peritoneal involvement is an uncommon manifestation of sarcoidosis, especially in the absence of splenic, hepatic, adnexal, or small intestinal involvement ¹. Most cases present with ascites, which usually have a benign

course, resolving either spontaneously or with a short course of corticosteroid therapy. ² Rarely, an exudative ascites may occur from studding of the peritoneum with nodules. ³ Patients usually complain of abdominal pain and the peritoneal fluid is more often lymphocyte predominant. They are usually female and present between the second and fourth decade of life. ¹. Corticosteroids can be given when there is an association with pulmonary sarcoidosis to good effect. ⁴ There are few cases of this association reported in the literature; to our knowledge only 20 cases of peritoneal sarcoidosis alone have been reported in the English language. ⁵ Our case highlights the importance of identifying and treating pulmonary sarcoidosis and that extra-pulmonary associations can give you clues to the diagnosis.

ACKNOWLEDGEMENTS

We would like to thank Dr Faisal Ali with his help providing the histology slides and Dr Mark Kon with the radiology images

References

1. Iyer, S, Afshar, K, Sharma, OP. Peritoneal and pleural sarcoidosis: an unusual association - review and clinical report. *Curr Opin Pulm Med* 2008; 14:481.
2. Uthman, IW, Bizri, AR, Shabb, NS, et al. Peritoneal sarcoidosis: case report and review of the literature. *Semin Arthritis Rheum* 1999;28,351-354.
3. Ebert EC, Kierson M, Hagspiel KD. Gastrointestinal and hepatic manifestations of sarcoidosis. *The American journal of gastroenterology*, December 2008, vol./is. 103/12(3184-92; quiz 3193), 1572-0241.
4. Bernaciak J, Spina JC, Curros ML, Maya G, Venditti J, Chacon. Case report: peritoneal sarcoidosis in an unusual location. *Seminars in respiratory and critical care medicine*, December 2002, vol./is. 23/6(597-600), 1069-3424.
5. Bourdillon L, Lanier-Gachon E, Stankovic K, Bancel B, Lapras V, Broussolle C, Sève P. Lofgren syndrome and peritoneal involvement by sarcoidosis: case report. *CHEST*, 01 July 2007, vol./is. 132/1(310-312).

Author Information

Leanne Burke, MRCP

The Royal College of Physicians (London), Bradford Royal Infirmary

Jacob K Badie, FRCP

The Royal College of Physicians (London), Bradford Royal Infirmary