

# Focal Nodular Hyperplasia: Case Report

S Singh, V Chowdhury, R Dixit, A Prakash

## Citation

S Singh, V Chowdhury, R Dixit, A Prakash. *Focal Nodular Hyperplasia: Case Report*. The Internet Journal of Radiology. 2008 Volume 9 Number 2.

## Abstract

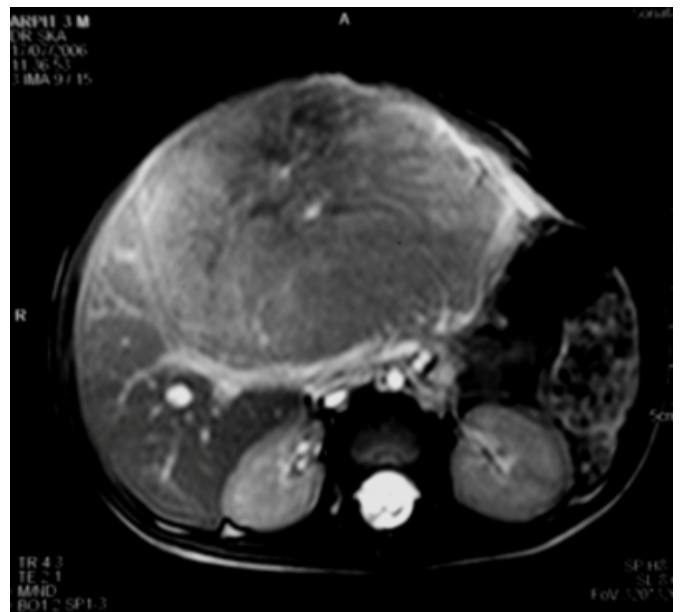
## INTRODUCTION

It is the second most common benign lesion of the liver after haemangioma and contains hepatocytes, bile duct elements, Kupffer cells and fibrous tissue. It is usually found incidentally on abdominal imaging studies, although about one-third of tumours are discovered because of clinical symptoms. Its aetiology is unknown but it is postulated that a congenital vascular malformation may trigger the development of hepatocyte hyperplasia because pathologic studies have shown the existence of anomalous arterial branches unaccompanied by portal venous branches feeding the numerous small lobules comprising FNH. A hormonal influence may also be the aetiological factor because FNH is more common in women in their 3rd-5th decades. It is rare in the paediatric age group.

## CASE REPORT

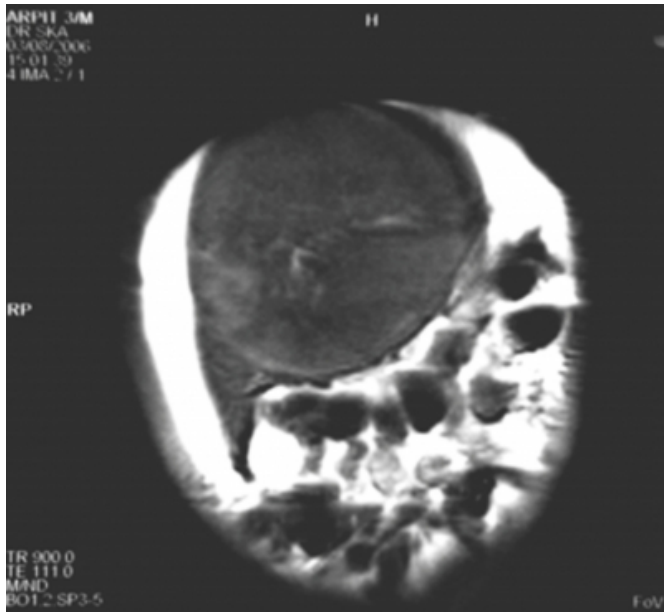
A- 3 year old child presented with progressively increasing abdominal mass. There was no history of fever or weight loss. The child was subjected to a MRI examination.

Figure 1



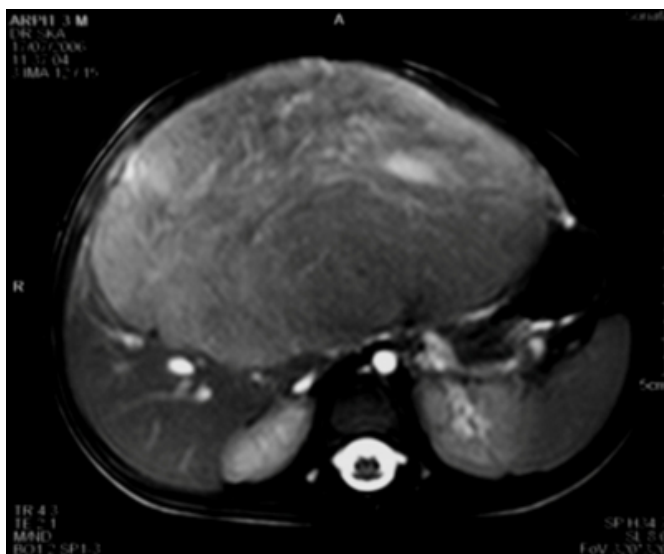
Axial TRUFISP MR image showing a large mass occupying the entire left lobe of liver and splaying the portal vein with mass effect on the portal vein.

**Figure 2**



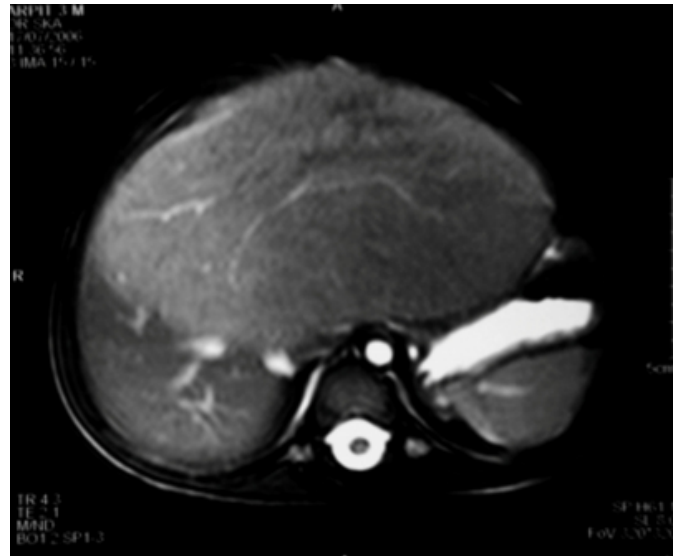
Coronal Haste MR image showing the mass in the liver.

**Figure 3**



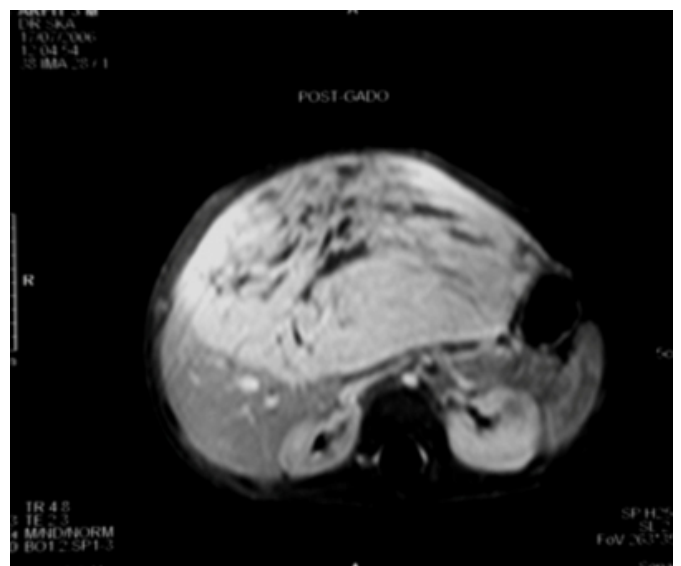
Axial TRUFISP MR image showing the central stellate radiating scar,

**Figure 4**



Axial TRUFISP MR image showing the central stellate radiating scar. The scar is hyperintense on T2 W images.

**Figure 5**



Postcontrast MR image showing enhancement in the mass with the central scar non – enhancing.

Based on the MRI findings a diagnosis of focal nodular hyperplasia was given which was proved on biopsy.

## **DISCUSSION**

FNH is well-circumscribed, non-encapsulated and usually solitary (95%) mass that is characterized by a centrally located scar surrounded by nodules of hyperplastic hepatocytes. Histologically, it is characterized by the presence of normal hepatocytes, with a malformed biliary

system that leads to slowing of biliary excretion. It is often present on the liver surface or it may be pedunculated. The majority of lesions are smaller than 5 cm having a mean diameter of 3 cm. Occasionally FNH may replace an entire lobe of liver when it is known as lobar FNH.

### **IMAGING FEATURES**

#### **US**

FNHs appear homogeneous and isoechoic to normal liver and may be visible only because of the mass effect they exert on adjacent hepatic vessels.<sup>2</sup> In some cases, FNH appears as an inhomogeneous mass containing hypoechoic and hyperechoic areas. An echo complex corresponding to the central fibrous scar, although classical is infrequently demonstrated.

#### **COLOUR DOPPLER**

FNHs are hypervascular tumours. Numerous scattered arterial and venous Doppler signals may be seen throughout the tumour exhibiting a 'comet tail' appearance.

#### **CONTRAST ENHANCED US**

FNH manifests as a hypervascular liver mass during the arterial phase of contrast enhanced US. FNH shows a stellate lesion and a central non-enhancing scar. On the portal venous phase the lesion remains isoechoic to the liver with a central non-enhancing scar. On further delayed images there is accumulation of contrast within the scar. Portal venous phase imaging is critical to confident confirmation of the diagnosis. As apposed to HCC, in which rapid washout is generally seen FNH is isoechoic to the liver parenchyma into the portal venous phase and beyond.<sup>3</sup>

### **FOCAL NODULAR HYPERPLASIA AND HEPATIC ADENOMA : DIFFERENTIATION WITH LOW INDEX CONTRAST ENHANCED SONOGRAPHY.**

Recent advances in contrast enhanced sonography using a low mechanical index (<0.2) and perfluorocarbon contrast agents enable real time imaging of perfusion and vascularity in liver tumours. FNH is predicted on the basis of arterial phase centrifugal filling as opposed to the centripetal filling seen in adenomas. Stellate linear or plicated non enhancing area suggests the diagnosis of FNH. Also sustained portal phase enhancement is more common in FNH than in adenoma.<sup>4</sup>

#### **CT**

Non-contrast CT of FNH demonstrates a non-specific low

density lesion, often located adjacent to the liver capsule. They may deform the liver contours or possess a prominent stellate-shaped central scar which is seen as a central low density area. FNH is a hypervascular lesion with a prominent arterial blood supply. There is rapid enhancement of FNH appearing hyperdense relative to liver in the arterial phase (approx first 30 seconds) with a steady decrease in attenuation during the portal phase during which it appears relatively isodense to hypo-dense to the normal liver tissue and the central scar remains of low density. On delayed images there is accumulation of contrast within the scar which appears hyperdense. This sign is highly indicative of FNH.

### **HAEMODYNAMIC CHARACTERIZATION OF FOCAL NODULAR HYPERPLASIA**

Focal nodular hyperplasia is supplied by an enlarged anomalous hepatic artery and its drainage is always into the hepatic veins.<sup>5</sup> Multiphasic multidetector CT allows greater spatial and haemodynamic characterization of focal hepatic lesions. The three-dimensional (3D) multidetector CT angiography using volume rendering displays the haemodynamics and angioarchitecture of focal nodular hyperplasia, features that help in distinguishing these lesions from malignant masses.<sup>6</sup>

#### **NUCLEAR SCINTIGRAPHY**

On sulphur colloid scan 60 per cent of FNH lesions will have uptake of radiotracer indicating intratumoural Kupffer cell. This is infrequent with adenomas. Using trimethyl bromoimino diacetic acid (TBIDA) hepato-biliary scanning, the sensitivity of scintigraphy for FNH has been reported to be 92 per cent.

Angiography reveals a hypervascular mass possessing a centrifugal or spoke wheel pattern of vascular supply.

MRI FNH is mostly slightly hypointense on T1-weighted images and hyperintense on T2-weighted images. MRI may demonstrate FNH by its mass effect and displacement of hepatic vessels as well as by subtle differences in signal intensity compared with adjacent liver. FNH often contains a central scar which is hyperintense on T2 due to presence of oedema and hypointense on T1 weighted images.<sup>7</sup> This is because the scar is composed of vascular and myxoid tissue, both of which are rich in free water. (D/D fibrolamellar HCC— central scar is of low signal on both T1 and T2-weighted images). On administration of IV Gadolinium FNH frequently shows a homogeneous tumour

blush with rapid wash out to isointensity with surrounding liver tissue. Contrast enhanced 3D GRE MR imaging demonstrates characteristic enhancement patterns that are helpful in the characterization. Three dimensional GRE imaging have several advantages over two dimensional dynamic imaging. 3D images can be reformatted in any plane, high quality thin sections with no gaps can be obtained and the detection and localization of small hepatic lesions is superior. In addition the small data set can be used to generate high quality images depicting the vasculature.<sup>8</sup> Dynamic post-gadolinium images frequently depict the central scar not seen on unenhanced images. The scar shows a delayed and persistent enhancement after administration of Gd. Contrast agents with hepato-specific properties have been shown to increase the sensitivity of MR imaging for the detection of focal hepatic lesions, though the role of these agents is to be fully elucidated. Gadobenate dimeglumine (Gd-BOPTA) is a gadolinium based contrast agent in common with other gadolinium agents, has a vascular interstitial distribution in the first few minutes after injection. Thereafter, some 2 to 4 per cent of the administered dose is taken up by functioning hepatocytes and contrast is excreted in the bile, while the remaining dose undergoes renal excretion. The fraction taken up by the hepatocytes brings about a marked hyperintensity of the liver that persists for at least 120 minutes (3 hrs) after the injection. Gd BOPTA accumulates selectively in hepatocytes.<sup>9</sup> In FNH, there is prolonged and excessive accumulation of this contrast agent because FNH lacks a well-formed canalicular system to permit normal excretion. There is much less enhancement of the hepatocellular adenoma on dynamic phase MR images and a markedly hypointense appearance on delayed images as compared to FNH. Although adenomas have functioning hepatocytes they lack bile ducts. Altered hepatocellular metabolism may inhibit the uptake of Gd-BOPTA in the adenoma thereby accounting for its hypointense appearance on delayed MR images.

#### **HEPATIC ADENOMA AND FOCAL NODULAR HYPERPLASIA: MR FINDINGS WITH SUPERPARAMAGNETIC IRON OXIDE ENHANCED MRI (SPIO)**

SPIO is a contrast agent that undergoes phagocytosis by the reticuloendothelial system (Kupffer cells).<sup>10</sup> The use of SPIO results in shortening of T2-relaxation time of lesions containing Kupffer cells causing decreased signal intensity on T2-weighted images. These properties are of use in

characterizing hepatic liver lesions. The distinction between FNH and hepatocellular adenoma (HA) is important because FNH can be treated conservatively, whereas HA is often resected because of its propensity for haemorrhage. On T2W SPIO enhanced MRI, FNH shows a dramatic decrease in signal intensity (60 to 70%). SPIO uptake is expected in FNH as the lesion contains Kupffer cells and has an excellent vascular supply. The uptake of SPIO in hepatic adenomas is poor compared to FNH.<sup>11</sup> Only 20 per cent of signal loss on T2W is usually seen in adenomas. Tumour heterogeneity, T1 hyperintensity and only slight uptake of SPIO are MR features suggestive of adenomas while tumour homogeneity, T1 isointensity presence of central scar and the pronounced uptake of SPIO are highly suggestive of FNH.

#### **References**

1. Bartolozzi C, Cioni D, Donati F, et al: Focal liver lesions: MR imaging—Pathologic correlation. *Eur Radiol* 11: 1374-88, 2001.
2. Harvey CJ, Albrecht T: Ultrasound of focal liver lesions. *Eur Radiol* 11: 1578-93, 2001.
3. Wilson SR, Jang HJ, Kim TK, Burns PN: Diagnosis of focal liver masses on ultrasonography: comparison of unenhanced and contrast enhanced scans. *J Ultrasound Med* 26: 775 – 787, 2007.
4. Kim TK, Jang HJ, Burns PN, Lavalley JM, Wilson SR: Focal Nodular hyperplasia and hepatic adenoma: differentiation with low mechanical index contrast enhanced sonography. *Am J Roentgenol* 190 : 58 – 66, 2008.
5. Rangheard AS, Vilgrain V, Audet P, et al: Focal nodular hyperplasia inducing hepatic vein obstruction. *AJR* 179:759-62, 2002.
6. Brancatelli G, Federle MP, Katyal S, et al: Haemodynamic characterization of focal nodular Hyperplasia using three dimensional volume rendered multidetector CT angiography. *AJR* 179: 81-85; 2002.
7. Macky MD, Frazer C, deBoer WB: Magnetic resonance features of focal nodular hyperplasia of the liver. *Australasian Radiology* 43: 315-20, 1999.
8. Elsayes KM, Narra VR, Yin et al: Focal hepatic lesions: Diagnostic value of enhancement pattern approach with contrast enhanced 3D gradient Echo MR imaging. *Radiographics* 25: 1299 – 1320, 2005.
9. Grazioli L, Morana G, Federle M, et al: Focal nodular hyperplasia: Morphologic and functional information from MR Imaging with Gadobenate Dimeglumine. *Radiology* 221: 731-39, 2001.
10. Ba Ssalamah A, Schima W, Schmook MT, et al: Atypical focal nodular hyperplasia of the liver: Imaging features of nonspecific and liver specific MR contrast agents. *AJR* 179: 1447-56, 2002.
11. Beets Tan RGH, Van Engelshoven JMA, Greve JWM: Hepatic adenoma and focal nodular hyperplasia: MR findings with superparamagnetic iron oxide enhanced MRI. *Clin Imaging* 22: 211-15, 1998.

**Author Information**

**Sapna Singh, M.D., D.N.B. (Radiodiagnosis)**

Assistant Professor, Deptt. of Radiology, MAMC

**Veena Chowdhury, M.D. (Radiodiagnosis)**

Director Professor Head, Deptt. of Radiology, MAMC

**Rashmi Dixit, M.D. (Radiodiagnosis)**

Professor, Deptt. of Radiology, MAMC

**Anjali Prakash, D.M.R.D – D.N.B. (Radiodiagnosis)**

Associate Professor, Deptt. of Radiology, MAMC