

# Rhabdoid Meningioma: Rare And Highly Aggressive

V Kakar, A Elsmore

## Citation

V Kakar, A Elsmore. *Rhabdoid Meningioma: Rare And Highly Aggressive*. The Internet Journal of Neurosurgery. 2005 Volume 3 Number 2.

## Abstract

Rhabdoid meningioma was designated anaplastic (grade III) in 2000 in recognition of its biological aggressive potential. We present the case of a caucasian man with this extremely rare sub-type of malignant meningioma which had a very aggressive clinical course. Mangement of malignant meningiomas should at least consist of radical surgery with adjuvant radiotherapy and other therapeutic modalities may further improve outcome.

## INTRODUCTION

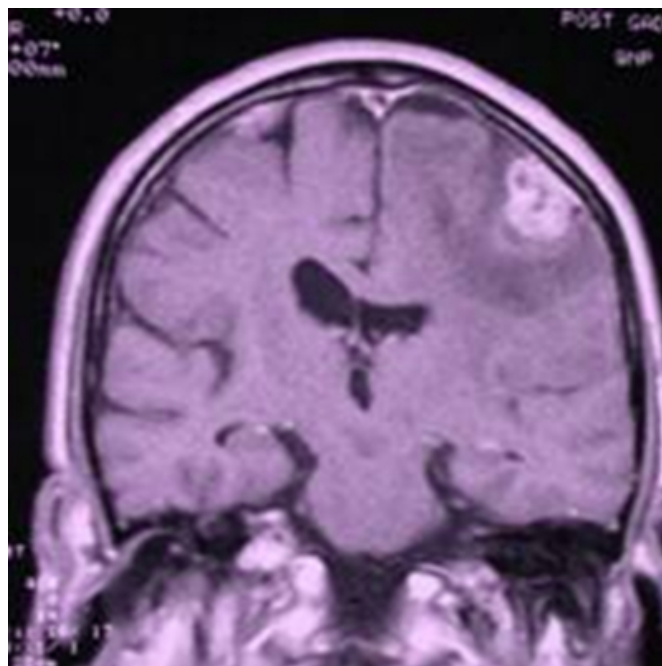
In 1998 Keppes et al<sub>9</sub> and later Perry et al<sub>13</sub> described two series of 4 and 15 cases respectively with clinically aggressive tumours that were a histologically distinct subgroup of malignant meningioma. They suggested the term Rhabdoid meningioma which was adopted into the WHO classification (grade III) in 2000<sub>10</sub>. In both series, median survival was less than 3 years after surgical resection (often multiple) with adjuvant treatment given in about half of all cases.

## CASE REPORT

A 59 year old Caucasian man with severe learning difficulties presented to his district hospital with 2 months of progressively worsening right sided weakness, increasing frequency of grand mal seizures (known history of epilepsy) and cognitive decline. On examination, he was drowsy but obeyed commands and had a right sided hemiparesis. No other abnormal neurological signs were elicited. MRI with contrast revealed an extrinsic left fronto- parietal enhancing mass with extensive surrounding oedema (figure 1). Neuronavigation guided left fronto-parietal craniotomy was performed and a well circumscribed mass which penetrated pia with loose arachnoidal attachment was excised with a 2cm margin of adjacent dura. Gross total resection was achieved. The post-operative course was uneventful, and the patient returned to his pre-morbid condition.

## Figure 1

Figure 1: Enhanced T1 weighted coronal MRI showing a durally based left fronto-parietal tumour but no abnormality in the right middle fossa. An additional right convexity lesion was unchanged on serial scans

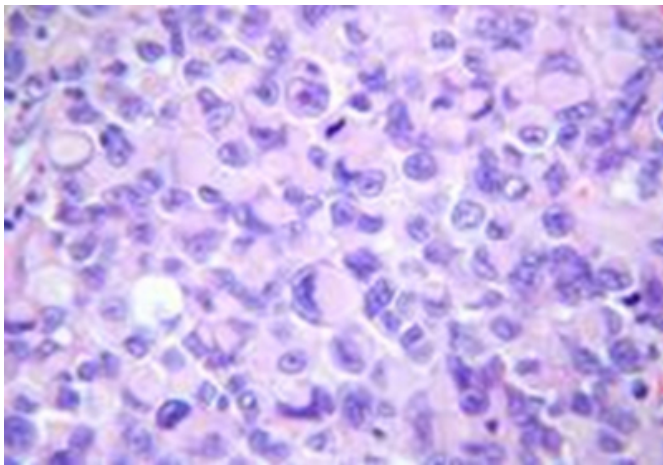


Histology showed classical rhabdoid morphology with nuclear anaplasia, very high mitotic rate, marked pseudopalisading of tumour cells and necrosis (figure 2). Tumour cells were immunoreactive to s100, vimentin and focally to EMA. Stains for GFAP, MNF116, HMB45, Desmin and SMA were negative, excluding the possibility of glioma, melanoma and metastatic carcinoma. Immunohistochemically, MIB-1 (Ki-67) proliferative index of greater than 20% is strongly suggestive of recurrence<sub>8</sub>; it

exceeded 50% in some areas of tumour in this case (figure 3). Oncology referral was made for adjuvant radiotherapy. Unfortunately, the patient was not co-operative enough to undergo treatment.

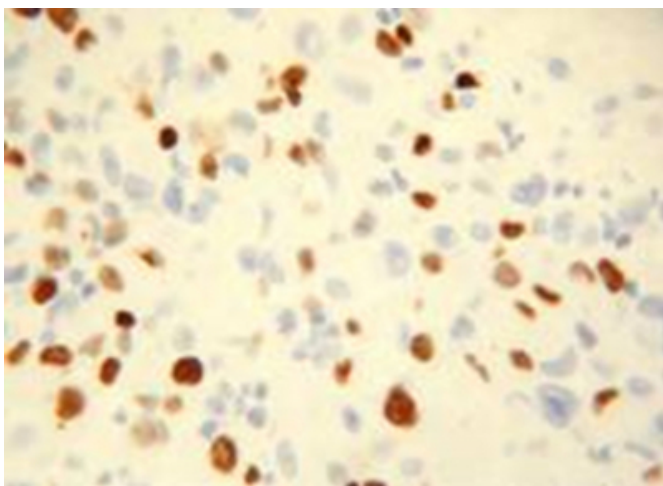
### **Figure 2**

Figure 2: H&E section showing typical rhabdoid appearance of cells with eccentric nuclei, some with prominent nucleoli, copious eosinophilic cytoplasm and a whorled appearance



### **Figure 3**

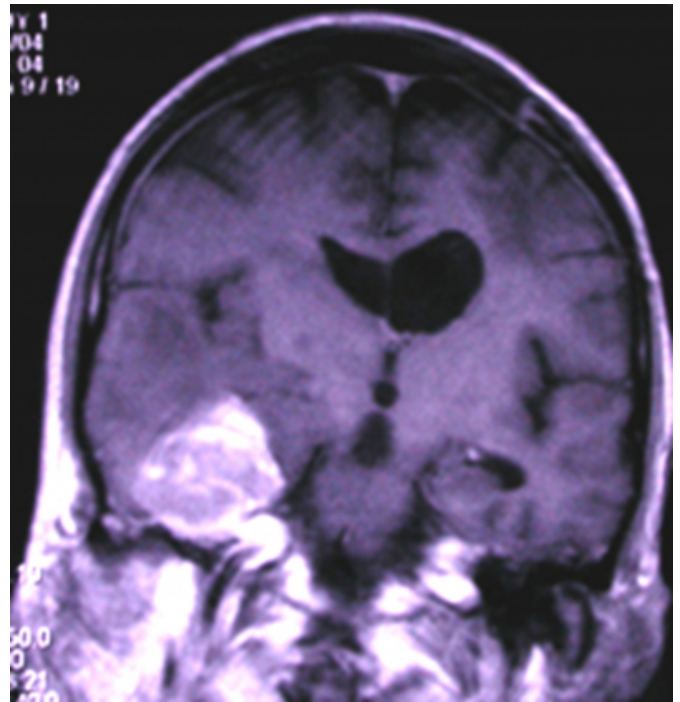
Figure 3: Immunoperoxidase for Ki67 showing high proliferation index



Five months later he suffered further cognitive decline, prior to his first planned follow up scan. MRI showed a large dural based lesion with surrounding oedema on the floor of the right middle fossa (figure 4).

### **Figure 4**

Figure 4: Enhanced T1 weighted coronal MRI showing a large right middle fossa tumour



There was enhancement across the upper surface of the tentorium to the tentorial hiatus suggesting tumour extension. This lesion was entirely new on review of the original imaging. Lymphadenopathy on chest CT scan may have been suggested extracranial metastases. Further management options were considered by the multi-disciplinary team at The London Radiosurgery clinic and discussed with the patient's relatives and carers. Treatment of any tumour residuum by gamma knife radiosurgery was deemed inappropriate. Given the highly malignant nature of the original tumour, the extent of recurrence and the patient's poor quality of life and inability to comprehend or consent to further treatment with only sub-optimal adjuvant therapy being possible, no further surgery was offered and palliative care was instituted in accordance with family members and carers' wishes.

## **DISCUSSION**

Up to 3% of meningiomas are frankly anaplastic (grade III) and a further 5-7% described as atypical (grade II). The most objective criteria demonstrating a progressive spectrum of malignant potential are microscopic brain invasion, high mitotic rate, nuclear pleomorphism, small cell cytology and sheeting. Increased expression of Ki-67 antigen correlates with recurrence and even in meningiomas with minimal atypical features should prompt closer surveillance after

excision.

Borovich et al, reported that meningiomas may appear to be single tumours in a regional neoplastic field extending about 4cm around the insertion zone. They postulated that local 'recurrences' may in fact be new primary tumours due to the presence of microscopical regional multicentric cell nests at the time of primary operation. However, recurrence may be due instead to metastases from the original globular tumour mass; along the subdural space, via CSF, drop metastases or haematogenous spread. Others have suggested the development of tumour spurs, visible at operation, as causal and predictive of recurrence rather than new primaries caused by regional multicentricity<sup>2</sup>. The likely rapid recurrence is in keeping with the aggressive appearance of the tumour histologically, particularly the MIB-1 (Ki-67) index of greater than 50%.

Radical surgery (Simpson grade 1) has been shown to significantly enhance prognosis in atypical and malignant meningiomas. Some surgeons advocate preoperative embolization to reduce intraoperative blood loss. However, with this technique there is the risk of embolic stroke and haemorrhage into a necrotic tumour.<sup>7</sup> Early conventional radiotherapy is recommended for atypical and anaplastic meningiomas irrespective of completeness of surgical excision with numerous studies showing improved disease free survival. Median survival exceeding 5 years with combined radiochemotherapy has been reported, the majority of that survival benefit probably being due to radiotherapy as current chemotherapeutic regimens are poorly effective against atypical/ anaplastic meningiomas.<sup>3,5,12</sup>

Other therapeutic modalities are being increasingly explored; Stereotactic radiosurgery (SRS) has been reported to be beneficial, even as a primary alternative to patients unable to undergo surgery<sup>11</sup>. However, a recent series showed no benefit for anaplastic tumours and poor control of atypical tumours<sup>15</sup>. It seems reasonable to use SRS as an adjunct immediately postoperatively for any tumour residuum, but not as a replacement for standard radiotherapy. Moreover, the use of both significantly increases the incidence of radiation complications. Brachytherapy has been tried with Iodine 125 sources intraoperatively with mixed results<sup>14</sup>. Complications include a rate of radiation necrosis requiring further surgical resection of 13% in one series. Immunotherapy with Interferon alpha, hydroxyurea and antiprostaglandins such as Mifepristone have been

administered in unresectable tumours.<sup>4,6</sup> None have shown efficacy in treating atypical/ anaplastic meningiomas. Recent interest in molecular therapies, including targeting tumour angiogenesis by inhibiting Vascular Endothelial Growth Factor (VEGF) or its receptor, shows future promise.

## **CONCLUSION**

Rhabdoid meningioma is an anaplastic, very rare subtype of malignant meningioma. It has menacing histology, early recurrence and a likely poor outcome. Current imaging techniques do not demonstrate any consistent hallmarks of malignancy and improved functional imaging/ MRS may provide more information on the biological activity of malignant meningiomas. Adjuvant therapy is essential in prolonging survival and management should at least consist of radical surgery and post-operative radiotherapy. There may be a role for SRS or even brachytherapy. Current conventional chemotherapy has little role and future targeted molecular therapies are required to improve outcomes.

## **CORRESPONDENCE TO**

Mr. Vishal Kakar 137 South Mossley Hill Road Liverpool L19 9bq, Uk E-Mail: Vishalkakar2005@Yahoo.Co.Uk Telephone: +44 151 494 0942 Fax: +44 151 494 0942

## **References**

1. Borovich B, Doron Y, Braun J, Guilburd JN, Zaroor M, Goldsher D, Lemberger A, Gruszkiewicz J, Feinsod M (1986): Recurrence of intracranial meningiomas: the role played by regional multicentricity part 2: clinical and radiological aspects J Neurosurg 65:168-171.
2. De Vries J, Wakhloo AK (1994) Repeated multifocal recurrence of grade I, grade II, and grade III meningiomas: Regional multicentricity (Primary new growth) or metastases? Surg Neurol 41:299-305.
3. Goldsmith SM, Wara WM, Wilson CB, Larson DA (1994) Postoperative irradiation for subtotally resected meningiomas. A retrospective analysis of 140 patients treated from 1967 to 1990. J Neurosurg 80:195-201.
4. Grunberg SM, Weiss MH, Spitz IM, Ahmadi J, Sadun A, Russell CA, Lucci L, Stevenson LL (1991) Treatment of unresectable meningiomas with the antiprogesterone agent mifepristone. J Neurosurg 74(6):861-866.
5. Jaaskelainen J, Hailtia M, Servo A (1986) Atypical and anaplastic meningiomas: radiology, surgery, radiotherapy and outcome. Surg Neurol 25:233-242.
6. Kaba SE, DeMonte F, Bruner JM, Kyritsis AP, Jaeckle KA, Levin A, Yung WK (1997) The treatment of recurrent unresectable and malignant meningiomas with interferon alpha-2B. Neurosurgery 40(2):271-275.
7. Kallmes DF, Evans AJ, Kaptain GJ, Mathis JM, Jensen ME, Jane MA: Hemorrhagic complications in embolization of a meningioma: Case report and review of the literature. Neuroradiology 40:271-275, 1997.
8. Kayaselcuk F, Zorludemir S, Gumurduhu D, Zeren H, Erman T (2002) PCNA and Ki-67 in central nervous system tumors: correlation with the histological type and grade. J Neurooncol 57:115-121.

9. Keppes JJ, Moral LA, Wilkinson SB, Abdullah A, Llena JF (1998) Rhabdoid transformation of tumor cells in meningiomas: A histologic indication of increases proliferative activity. Report of four cases. *Am J Surg Pathol* 22:231-238.
10. Kleihues P, Louis DN, Scheithauer BW, Rorke LB, Reifenberger G, Burger PC, Cavenee VK (2002) The WHO classification of tumors of the nervous system. *J Neuropathol Exp Neurol* 61:215-225.
11. Kondziolka D, Lunsford D, Coffey RJ, Flickinger JC (1991) Stereotactic radiosurgery of meningiomas. *J Neurosurg* 74:552-559
12. Marc C, Chamberlain MD (1996) Adjuvant combined modality therapy for malignant meningiomas. *J Neurosurg* 84:733-736.
13. Perry A, Scheithauer BW, Satfford SL, Abell-Aleff PC, Meyer F (1998) "Rhabdoid" Meningioma; An aggressive variant. *Am J Surg Pathol* 22:1482-1490
14. Rogano LA, McDermott MW, Larson DA (1995) Permanent I-125 implants for recurrent malignant tumors (abstract). *Proc Congress Neurol Surg 45th Annual meeting*, San Francisco 382
15. Stafford SL, Pollock BE, Foote RL, Link MJ et al (2001) Meningioma radiosurgery: Tumor control, outcomes, and complications among 190 consecutive patients. *Neurosurgery* 49:1029-1037.

**Author Information**

**Vishal Kakar, MRCS**

Department of Neurosurgery, Royal London hospital

**Andrew Elsmore, FRCS**

Department of Neurosurgery, Royal London hospital