

# Lateral Advancement Flap with Burow's triangle: An Ideal treatment for Pilonidal Sinus Disease

S Dalal, R Dahiya, Nityasha, V Kathuria, R Singh

## Citation

S Dalal, R Dahiya, Nityasha, V Kathuria, R Singh. *Lateral Advancement Flap with Burow's triangle: An Ideal treatment for Pilonidal Sinus Disease*. The Internet Journal of Plastic Surgery. 2007 Volume 5 Number 1.

## Abstract

Pilonidal sinus has been accepted as an acquired condition that can present in many ways and bears a significantly high postoperative morbidity. Various methods of treatment have been proposed in past ranging from non-surgical methods (Phenol injection, cryosurgery etc.) to complex surgical procedures like various flaps and plastic procedures. But the management of pilonidal sinus still frequently remains unsatisfactory, as all the methods have met with varying degree of recurrences. In our study we have evaluated the effectiveness of Lateral Advancement flap with excision of burow's triangles in 29 patients of pilonidal sinuses. The results revealed that this is a very reliable and simple technique removing almost all causative factors of the disease leading to good cosmesis and early return to work and almost nil recurrences.

## INTRODUCTION

Pilonidal sinus is not just a sinus tract but a disease complex which can present in various ways like acutely as an abscess or an infected sinus or chronically as poorly draining abscesses or sinuses.<sup>1</sup> Management of pilonidal sinus is frequently unsatisfactory. Though various modalities of treatment have been described, no consensus has emerged, as all have met with varying degrees of recurrence. The oldest and simplest surgical procedure is laying open of the wound after excision. Other surgical options are wide excision with primary closure, Bascom's procedure, Karydakis operation and Rotational/Transpositional flaps.<sup>2,3</sup> It is natural that the surgeon should select the method of treatment which, in his own hands will give the best results but his clinical judgment should also be influenced by more recent experiences by a careful and critical analysis of all end results.

The recent treatment of PNSD is based on general principles of wound healing like primary healing of wounds is probably more satisfactory when wounds are sutured rather than being left open to heal by secondary intention. Surgical procedures that keep the main wound away from midline are more likely to succeed.<sup>4</sup> The lateral advancement flap used in our study has been derived from the Karydakis flap adding the requirement of natal cleft lift to make it shallow.<sup>5</sup> A prospective study was carried out to evaluate the efficacy and results of lateral advancement flaps with burow's

triangle for treating pilonidal sinus cases.

## MATERIAL AND METHODS

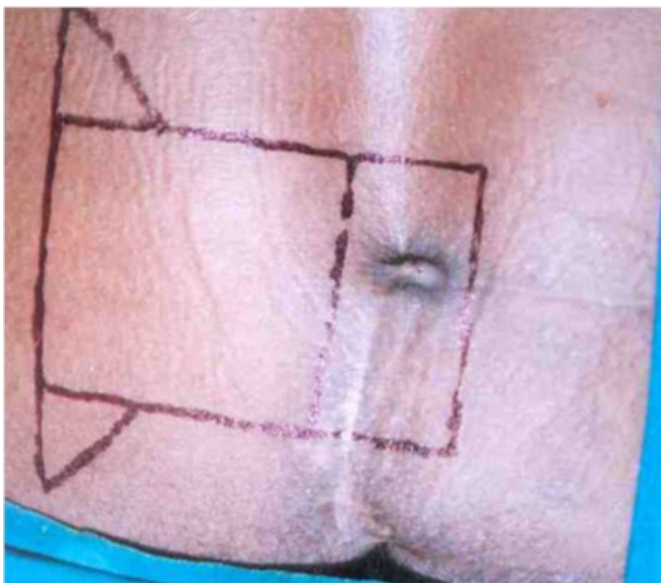
The study was planned on 25 cases of pilonidal sinuses, but ultimately 29 patients were channeled into study. All patients were attending the Outpatient Department of different surgical units and they included primary as well as recurrent cases. Thorough general and local examination of all patients was carried out including identification of risk factors like their occupation and type of hairs etc. The parameters recorded on local examination were site of sinus, duration, number of external openings, depth of natal cleft and local hygiene status.

Preoperative preparation included shaving on the day of surgery followed by thorough bathing and prophylactic I.V. antibiotic at the time of induction of anaesthesia. After giving spinal anaesthesia, the jack knife position was made and buttocks were widened apart using adhesive tape. A rectangular excision and flap with burow's triangle was marked with a marker (Fig.1). A rectangular excision containing the diseased tissue was performed including all sinuses and their ramifications along with surrounding indurated tissue till the postsacral fascia (Fig.2). Optimum size of flap was kept about 1.5-2 times the defect to be closed. The flap contained skin, adipose tissue with its underlying fascia not including muscle (Fig.3); hence also known as Fascio-Adipo-Cutaneous (FAC) flap. The flap raised was of uniform thickness till its base. The perforators

found during flap raising were cauterised and the wound was washed with diluted betadine followed by normal saline. Two triangles known as burow's triangle were cut at the corners of the base of flap for proper approximation of flap and to avoid dog ears. Vicryl 2 'o' sutures were used to fix the undersurface of the flap to postsacral fascia to avoid tension on flap and to obliterate the dead space. Closed suction drain was placed via a separate stab and skin closure was done with prolene sutures to achieve the asymmetric closure of the wound approximately 2 cm lateral to midline (Fig.4).

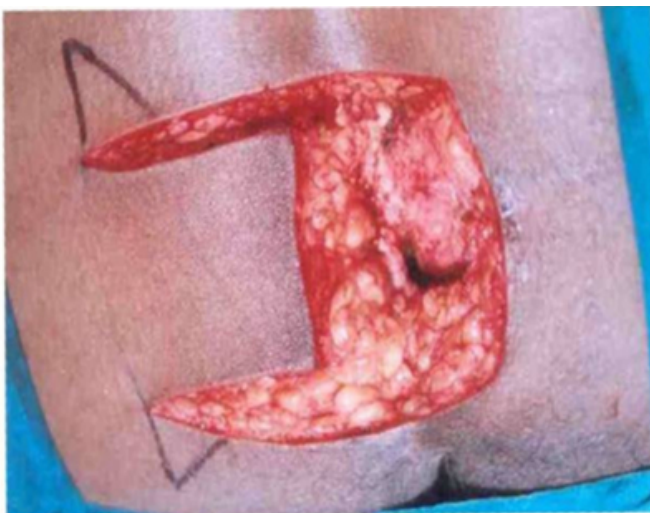**Figure 1**

Figure 1: Markings of sinus tract, flap and burow's triangles.



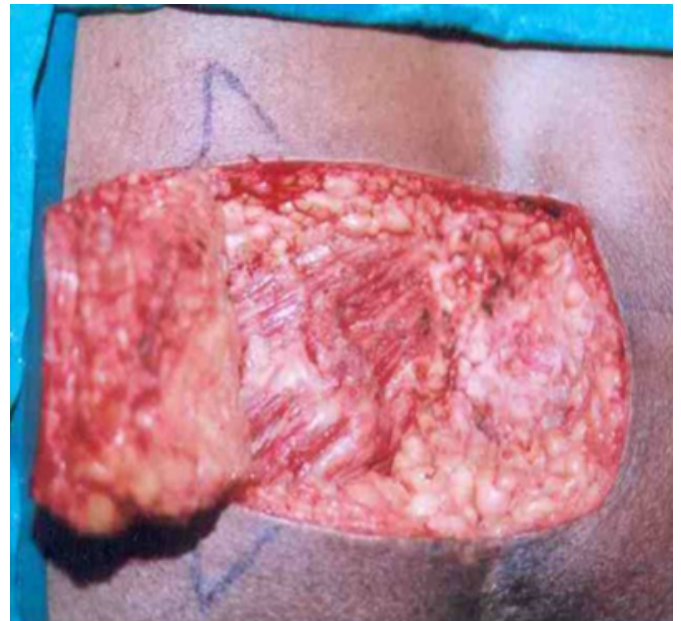
**Figure 2**

Figure 2: Showing excised rectangle including all sinus tracts.



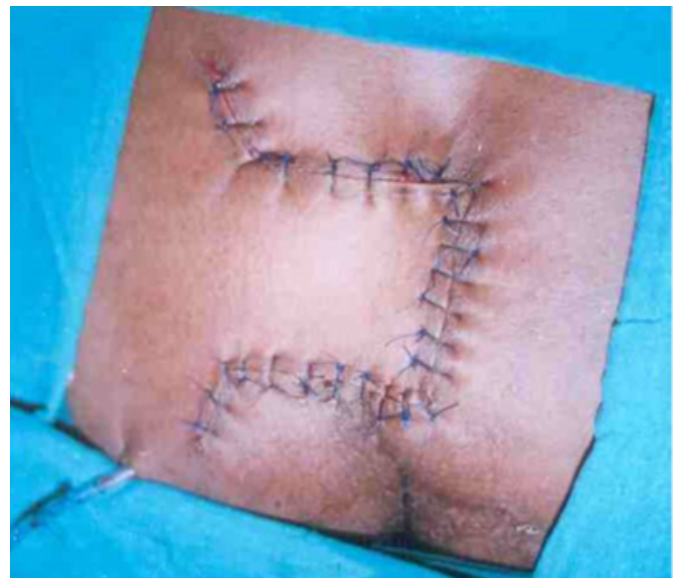**Figure 3**

Figure 3: Showing raised FAC flap leaving behind gluteal muscles



**Figure 4**

Figure 4: Showing final closure with eccentric suture line



Postoperative management included low residue diet for 3 days to avoid passage of stools and mobility was restricted for 48 hours. Supine position was preferred because the added compression was helpful in decreasing dead space and promoting flap adherence. Drain was not removed before 5<sup>th</sup> postoperative day even if the drain output was <10 ml/24 hour, because the vacuum created by negative suction drain helps in adhering the flap to postsacral fascia. Patients were discharged on 5<sup>th</sup>/6<sup>th</sup> postoperative day after drain removal

with compression bandage and necessary instructions regarding defecation sitting, local hygiene etc. All patients were called up for stitch removal on 14<sup>th</sup> postoperative day and for follow up at 6 weeks, 6 months and 1 year. The effectiveness of Lateral FAC Flap was evaluated in terms of

- Postoperative hospital stay
- Haematoma/seroma collection,
- Infection/sepsis,
- Flap necrosis/dehiscence of flap, and
- Recurrence

## RESULTS

Twenty nine patients underwent this procedure out of which 25 were primary and 4 were recurrent cases. The disease was mainly confined to young adults (mean age 26.4 years) and males outnumbered females by huge margin (Table I). Hygiene and depth of natal cleft was observed in all patients. Hygiene was good only in 14% patients and in rest of patients it was moderate or poor, while natal cleft was deep in majority (86%) of patients (Table I).

**Figure 5**

Table 1: FAC Flap Repair for PNSD : Patient Demographics, Occupation and Local Examination

<b>Total No. of Patients</b>	<b>29</b>
<b>Age (years)</b>	
Range	17-42
Mean	26.4
<b>Gender</b>	
Male	26 (89.6%)
Female	3 (10.4%)
<b>Occupation</b>	
Student	16
Shopkeeper	3
Driver	2
Clerk	2
<b>Natal Cleft depth</b>	
Deep	25 (86%)
Shallow	4 (14%)

The average duration of surgery was 43 minutes ranging

from 35-60 minutes. The patients having multiple sinuses, recurrent sinuses and those having deeper sinuses required little longer operative time. The mean hospital stay was 6.8 days (5-15 days). The average duration of resumption of work was 11.86 days (10-12 days). Out of 29 patients, 21 patients were having no complications, while remaining 8 had one or more complications in postoperative period. At first dressing on 3<sup>rd</sup> postoperative day, 3 patients had serous discharge out of which one had seroma formation probably due to blockage of drain. The seroma was drained and the same patient developed partial flap dehiscence (Table II). The flap necrosis mainly at corners was observed in 3 patients which was in patches and recovered completely without any further intervention. In 2 patients, the suture line got infected in perianal area for which swab culture sensitivity was done and antibiotics were given accordingly (Table II).

**Figure 6**

Table 2: FAC Flap Repair for PNSD : Operative Procedure and Complications

<b>Total No. of Patients</b>	<b>29</b>
<b>Average duration of surgery (minutes)</b>	<b>43</b>
<b>Average hospital stay (days)</b>	<b>6.8</b>
<b>Early Complications</b>	
<u>Minor</u> - Discharge (Serous)	3 (10%)
with seroma	1 (3.4%)
- Flap necrosis (at margins)	3 (10%)
<u>Significant</u> - Flap dehiscence	1 (3.4%)
- Wound Infection	2 (7%)

During follow-up numbness was noted in one patient and scar hypertrophy in two patients at 6 months (Table II). One patient had chronic neurological pain in gluteal region till 6 months which gradually subsided by itself. No patient was found to have recurrence of the disease at 1 year.

## DISCUSSION

Pilonidal sinus is generally accepted to be an acquired condition that bears high postoperative morbidity. Various methods of treatment have been proposed ranging from nonsurgical techniques like Phenol Injection<sup>6</sup>, Silicon foam<sup>7</sup>, cryosurgery<sup>8</sup> to surgical procedures like simple laying open of sinus tract and complex asymmetric operations where suture line falls away from midline.<sup>4</sup> In our study we have used the flap proposed by Singh RB, with the addition of

cutting of burow's triangles at the base of lateral advancement flap, so that it fulfills almost all the requirements for adequate treatment of PNSD.<sup>5</sup>

The mean age of presentation in our study was 26.4 years, which is in accordance with other studies.<sup>3,9</sup> As per literature the condition is rare below 15, rises sharply to peak between 20-30 years and declines after 30 years. The males outnumbered females and the sex ratio was 8.5:1 in favour of males. This again was comparable with other studies.<sup>9,10</sup> The disease has been mainly noted in patients having deep natal cleft and poor hygiene of the area, causing accumulation of hairs and macerating the area leading to dekeratinization and breaking the epithelial barrier. Most of the patients in our study also belonged to the occupation which involved prolonged sitting.

The average duration of surgery was 43 minutes, which was little more as compared to other studies like Karydakis and Bascom<sup>3,11</sup> (approx. 30 minutes). This was due to extra time consumed in making and fixing the flap and excision of scar tissue in recurrent cases. The mean hospital stay was 6.8 days, due to sticking to a protocol of keeping the drain for atleast 5 days. Except for first 48 hours the controlled mobility was permitted with instructions to avoid squatting, brisk walking and prolonged sitting etc.

Overall complications occurred in 8 out of 29 patients (27.6%), which is significantly higher than other studies. This is due to the fact that other studies did not included serous discharge, minimal flap necrosis etc. as significant complications in their studies.<sup>10,11</sup> The actual comparable complications included major flap necrosis, flap dehiscence, gross infection and early or late recurrence. There was no case of major flap necrosis. If we exclude minor serous discharge and flap necrosis at margins from our list, only 3 patients (10.4%) are left with significant complications. One had significant seroma collection because of blockade of negative suction drain in postoperative period ultimately leading to flap dehiscence, while other two patients had significant wound infection. So overall complication rate was approximately 10% which was comparable with the studies of Akinei (7.1%)<sup>10</sup> and Karydakis (8.5%).<sup>3</sup>

The wound healing time was 13.2 days. Other studies also show that complete healing occurs by the end of 2<sup>nd</sup> week. The recurrence noticed in study was nil (0%) whether early

or late. As the procedure makes the wound to heal within 2 weeks, the recurrence time shifts nearer to the operative period, as against the procedure with excision alone which takes about two months in complete healing, and so observation for recurrence starts thereafter. Here the early recurrence can be identified even before one month. Early recurrences are due to inadequate excision or wound complications while late recurrences are because of multifactors including life style and hygiene.

So excision of pilonidal sinus enblock upto postsacral fascia and making eccentric closure using FAC flap with burow's triangles ensures reliable wound healing removing almost all causative factors like deep natal cleft and midline stitchline. The advantages like early return to work, good cosmesis, cost effectiveness, prevention of early and late recurrence, and suitability for recurrent cases makes this technique as future radical treatment of PNSD.

### **CORRESPONDENCE TO**

Dr. Satish Dalal 9J/54, Medical Campus, PGIMS, Rohtak-124001 (Haryana) INDIA Tel. No. +91-1262-213459, Mobile : 09315326802 E-mail : drsatishdalal@rediffmail.com

### **References**

1. Raffman R. A reevaluation of the pathogenesis of pilonidal sinus. *Ann Surg* 1959; 150: 895-903.
2. Healy MJ, Hoffert PW. Pilonidal sinus and cyst. A comparative evaluation of various surgical methods in 229 consecutive cases. *Am J Surg* 1954; 87: 578-88.
3. Karydakis GE. Easy and successful treatment of pilonidal sinus after explanation of it's causative process. *Aust N Z J Surg* 1992; 62: 385-89.
4. Senapati A. Does closure of the wound after excision of a pilonidal sinus improve the result? *Boulos PB, Wexner SD. Current challenges in colorectal surgery. First ed. 2000. WB Saunders Harcourt, London. p. 34-45.*
5. Singh RB, Pavithran NM. Adipo-fascio-cutaneous flaps in the treatment of pilonidal sinus: Experience with 50 cases. *Asian J Surg* 2005; 28(3): 198-201.
6. Stausby G, Greatorer R. Phenol treatment of pilonidal sinuses of the natal cleft. *Br J Surg* 1989; 76: 729-30.
7. Wood RAB, Hughes. Silicone foam storage for pilonidal sinus; a new technique for dosing open granulating wounds. *Br Med J* 1975; 4: 131-33.
8. Gage AA, Dutta P. Cryosurgery for pilonidal disease. *Am J Surg* 1972; 133: 249-54.
9. Mersher Allen TG. Pilonidal sinus : finding the right track for treatment. *Br J Surg* 1990; 77: 123-32.
10. Akinci OF, Coskun A, Uzunkoy A. Simple and effective surgical treatment of Pilonidal sinus. *Dis Colon Rectum* 2000; 43(5): 701-07.
11. Bascom J, Bascom T. Failed pilonidal surgery. *Arch Surg* 2002; 137: 1146-51.

**Author Information**

**Satish Dalal**

Associate Professor, Department of General Surgery, Pt. B.D. Sharma Postgraduate Institute of Medical Sciences (PGIMS)

**R.S. Dahiya**

Senior Professor, Department of General Surgery, Pt. B.D. Sharma Postgraduate Institute of Medical Sciences (PGIMS)

**Nityasha**

Assistant Professor, Department of General Surgery, Pt. B.D. Sharma Postgraduate Institute of Medical Sciences (PGIMS)

**Vikas Kathuria**

Senior Resident, Department of General Surgery, Pt. B.D. Sharma Postgraduate Institute of Medical Sciences (PGIMS)

**R.B. Singh**

Senior Professor, Department of Plastic Surgery, Pt. B.D. Sharma Postgraduate Institute of Medical Sciences (PGIMS)