

# Retained appendicoliths after laparoscopic appendectomy

A Nejmeddine, F Najla, M Rafik, B Salah, B Issam

## Citation

A Nejmeddine, F Najla, M Rafik, B Salah, B Issam. *Retained appendicoliths after laparoscopic appendectomy*. The Internet Journal of Surgery. 2008 Volume 20 Number 1.

## Abstract

Appendiceal fecaliths are composed of inspissated fecal material, mucus with trapped calcium phosphate, and inorganic salts. Appendicoliths favour appendicitis. Abscesses or fistulas secondary to retained appendicoliths will likely continue to increase in frequency with the more widespread use of laparoscopic appendectomy. We report the case of a patient who developed a fistula caused by appendicoliths that were accidentally dropped during appendectomy. After extraction of the fecalith and antibiotic therapy, the patient attained definitive healing.

## INTRODUCTION

Appendicoliths are composed of inspissated fecal material, mucus with trapped calcium phosphate, and inorganic salts. Dropped appendicoliths from appendectomy are rare, but the radiologist and surgeon should consider them as a potential source of intra-abdominal complications. Abscesses or fistulas secondary to retained appendicoliths will likely continue to increase in frequency with the more widespread use of laparoscopic appendectomy. We report the case of a patient who developed a fistula caused by appendicoliths that were accidentally dropped during appendectomy.

## CASE REPORT

A 70-year-old previously healthy woman presented to our emergency department complaining of a 5-day history of colicky abdominal pain, fever, chills, vomiting, and increasing abdominal girth. Findings of physical examination and laboratory studies were consistent with a diagnosis of complicated appendicitis.

The patient had undergone laparoscopic appendectomy and drainage for gangrenous and perforated appendicitis. Microscopic examination of the appendix confirmed appendicitis. After surgery, there was no serious problem and the patient was discharged from hospital after 6 days in a good condition.

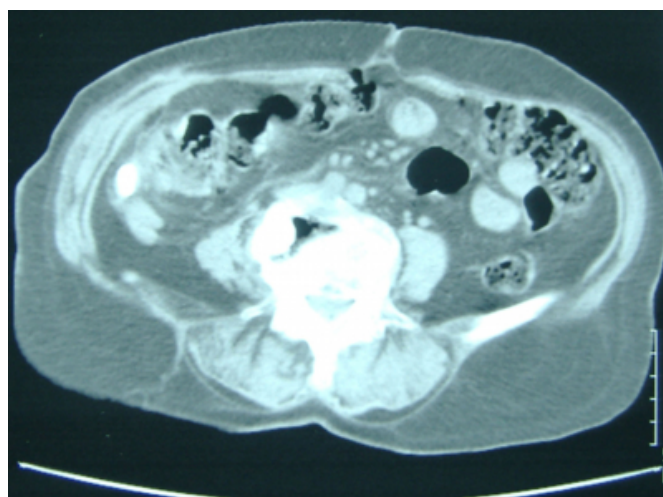
One month later, she was referred because of copious discharge of pus from the drainage site. On examination, the patient had fistulous tracts; ultrasonography of the abdomen demonstrated a small internal opening at the right lower quadrant without collection.

Colonoscopy was normal. Fistulogram showed a fistulous tract from the skin to the peritoneal cavity. There was no communication of the fistulous tract with the bowel.

CT revealed a calcified appendicolith at the right lower quadrant, measuring about 2cm in diameter (Figure). To extract the appendicolith, the fistulous tracts was dilated and provided access to the retained appendicolith. The fecalith was found and removed. The patient was discharged several days later in stable condition, afebrile and with normal WBC.

## Figure 1

Figure 1: Abdominal CT scan showing an opaque fecalith in the right lower quadrant



## COMMENT

Weisfog first described the radiographic characteristics of calcified appendicoliths in 1906. Appendicoliths are

composed of inspissated fecal material, mucus with trapped calcium phosphate, and inorganic salts (1, 2). Until recently, the presence of an appendicolith was considered 100% specific for the diagnosis of acute appendicitis. However, 13% of patients without acute appendicitis showed an appendicolith on CT (3). About 60% of resected appendices contain appendicoliths (1). Presence of an appendicolith is also associated with a high incidence of perforation, especially in children. However, appendicoliths can be detected by plain abdominal X-ray in only 10 to 15% of patients with acute appendicitis. With the recent popularity of ultrasound and computed tomography, the rate of detection has increased (3).

The appendicoliths can drop at the time of resection of the appendix, during forceful extraction through the umbilical cannula or if the appendix perforates. Complications associated with retained fecaliths following appendectomy are becoming more prevalent with the increased use of the laparoscopic technique, similar to the increase in dropped gallstones following the introduction of laparoscopic cholecystectomy (3).

The time between laparoscopic appendectomy and representation with abscess ranged from 2 months to 4 years (3).

The natural history of dropped appendicoliths is not yet known but there is some early evidence that they have a significant association with abscess formation, with the appendicolith acting as a nidus for infection. The appendicolith remains a focus of infection, which only resolves when it is removed. CT-guided percutaneous drainage of intra-abdominal abscess secondary to retained appendicoliths is only successful in the short term. Formal surgical drainage and removal of the appendicolith is

required for long-term success (3). A second laparoscopic surgery can be used (4). Lossef et al. demonstrated the effective use of Kopans breast localisation hookwire in the preoperative localisation of retained appendicoliths (5). If patients have fistulous tracts, they can be dilated and provide access to the retained stones. The appendicoliths were retrieved using endoscopic extraction baskets. But fecaliths may be fragile and can break into small irretrievable fragments, once the basket is tightened around the appendicoliths. The prevention of retained appendicoliths after laparoscopic appendectomy requires a systematic double ligature of the appendiceal base (6) or extraction of the appendix in a plastic bag.

### CONCLUSION

When an appendix is discovered to be gangrenous or perforated at surgery, it should be manipulated gently to avoid dropping any appendicoliths, and an attempt should be made to retrieve any appendicoliths that spill.

### References

1. Buckley O, Geoghegan T, Ridgeway P, Colhoun E, Snow A, Torreggiani WC. The usefulness of CT guided drainage of abscesses caused by retained appendicoliths. *Eur J Radiol* 2006; 60: 80-3.
2. Strathern DW, Jones BT. Retained fecalith after laparoscopic appendectomy. *Surg Endosc* 1999; 12: 287-289.
3. Newrhee K, William PR, Maher A, Douglas SK. CT identification of abscesses after dropped appendicoliths during laparoscopic appendectomy. *AJR* 2004; 182: 1203-1205.
4. Smith AG, Ripepi A, Stahlfeld KR. Retained fecalith: laparoscopic removal. *Surg Laparosc Endosc Percut Technol* 2002; 2: 441-442.
5. Lossef S. C-guided Kopans hookwire placement for preoperative localisation of an appendicolith. *AJR* 2005; 185: 81-83.
6. Guillem P, Mulliez E, Proye C, Pattou F. Retained appendicolith after laparoscopic appendectomy: the need for systematic double ligature of the appendiceal base. *Surg Endosc* 2004; 18: 717-718.

**Author Information**

**Affes Nejmeddine**

Assistant Professor, Department of General Surgery, Habib Bourguiba Hospital

**Feriani Najla, MD**

Department of General Surgery, Habib Bourguiba Hospital

**Mzali Rafik**

Professor, Department of General Surgery, Habib Bourguiba Hospital

**Boujelben Salah**

Professor, Department of General Surgery, Habib Bourguiba Hospital

**Beyrouti Mohamed Issam**

Professor, Department of General Surgery, Habib Bourguiba Hospital