

Histological Studies of the Effects of Monosodium Glutamate on the Superior Colliculus of Adult Wistar Rats

A Eweka, F Om'Iniabohs

Citation

A Eweka, F Om'Iniabohs. *Histological Studies of the Effects of Monosodium Glutamate on the Superior Colliculus of Adult Wistar Rats*. The Internet Journal of Neurology. 2006 Volume 8 Number 2.

Abstract

Histological effects of Monosodium glutamate (MSG) commonly used as food additive on one of the visual relay centre namely the superior colliculus (SC) of adult Wistar rat was carefully studied. The rats of both sexes (n=24), average weight of 185g were randomly assigned into two treatments (n=16) and control (n=8) groups. The rats in the treatment groups received 3g and 6g of MSG thoroughly mixed with their feeds for fourteen days, while the control rats received equal amounts of feeds without MSG added. The rats were fed with growers' mash purchased from Edo Feeds and Flour Mill Ltd, Ewu, Edo State and were given water liberally. The rats were sacrificed on day fifteen of the experiment. The superior colliculus was carefully dissected out and quickly fixed in 10% formal saline for routine histological study after H&E method.

The histological findings after H&E method indicated that the treated section of the superior colliculus (SC) showed some varying degree of reduced cellular population based on its sparse distribution, degenerative changes, cellular hypertrophy, and intercellular vacuolations appearing in the stroma.

These findings indicate that MSG consumption may have a deleterious effect on the neurons of the intracranial visual relay centre and this may probably have some adverse effects on visual sensibilities by its deleterious effects on the cells of the superior colliculus (SC) of adult Wistar rats. It is recommended that further studies aimed at corroborating these observations be carried out.

INTRODUCTION

Pathological processes frequently involve the body's normal responses to abnormal environmental influences. Such noxious external influences as pathogenic microorganisms, trauma, dietary deficiencies and hereditary factors acting alone or in a complex interaction with environmental factors, cause diseases₁. Various environmental chemicals, industrial pollutants and food additives have been implicated as causing harmful effects₂. Most food additives act either as preservatives or enhancer of palatability. One of such food additive is monosodium glutamate (MSG) and it is sold in most open markets and stores in Nigeria as "Ajinomoto" marketed by West African Seasoning Company Limited.

The safety of MSG's usage has generated much controversy locally and globally₃. In Nigeria, most communities and individuals often use MSG as a bleaching agent for the removal of stains from clothes. There is a growing apprehension that its bleaching properties could be harmful or injurious to the body, or worse still inducing terminal diseases in consumers when ingested as a flavor enhancer in food. Despite evidence of negative consumer response to

MSG, reputable international organizations and nutritionist have continued to endorse MSG, reiterating that it has no adverse reactions in humans. Notably of such is the Directorate and Regulatory Affairs of Food and Drug Administration and Control (FDA&C) in Nigeria, now NAFDAC has also expressed the view that MSG is not injurious to health₄.

MSG improves the palatability of meals and thus influences the appetite centre positively with it resultant increase in body weight₅. Though MSG improves taste stimulation and enhances appetite, reports indicate that it is toxic to human and experimental animals₆. MSG has a toxic effect on the testis by causing a significant oligozoospermia and increase abnormal sperm morphology in a dose-dependent fashion in male Wistar rats₇. It has been implicated in male infertility by causing testicular hemorrhage, degeneration and alteration of sperm cell population and morphology₈. It has been reported that MSG has neurotoxic effects resulting in brain cell damage, retinal degeneration, endocrine disorder and some pathological conditions such as addiction, stroke, epilepsy, brain trauma, neuropathic pain, schizophrenia,

anxiety, depression, Parkinson's disease, Alzheimer's disease, Huntington's disease, and amyotrophic lateral sclerosis. It cannot be stated that MSG is the cause of such varied conditions as epilepsy and Alzheimer's disease, although there may be concerns of its involvement in its etiology.

The superior colliculus and lateral geniculate body constitutes the intracranial visual relay centre. The superior colliculus has a critical role in visual localization, orientation tracking movements, accommodation and pupillary reflex¹⁰. An analysis of effective connectivity demonstrated that the search-dependent variance in the activity of the superior colliculus was significantly influenced by the activity in a network of cortical regions including the right frontal eye fields and bilateral parietal and occipital cortices¹¹. Cerebral nuclei such as the medial and lateral geniculate bodies, inferior and superior colliculi have higher glucose utilization than other structures¹². There is also a correlation between functional activity and metabolic rate such as in the visual and auditory system¹³.

The effects of MSG on the intracranial visual relay centre may not have been documented, but there have been reports that it may be implicated in varied symptoms of dizziness, itching, vomiting, abdominal pain, headaches, diarrhea, tinnitus, increase hearing loss, macular rash, neutropenia and convulsion. It is probable that the adverse effects of MSG on vision such as dizziness may be due to direct effect of MSG on this visual relay centre. This present study was to elucidate the histological effects of MSG on the superior colliculus of adult Wistar rats.

MATERIALS AND METHODS

ANIMALS: Twenty four (24) adult Wistar rats of both sexes with average weight of 185g were randomly assigned into three groups A, B and C of (n=8) in each group. Groups A and B of (n=16) serves as treatments groups while Group C (n=8) is the control. The rats were obtained and maintained in the Animal Holdings of the Department of Anatomy, School of Basic Medical Sciences, University of Benin, Benin city, Nigeria. They were fed with growers' mash obtained from Edo feed and flour mill limited, Ewu, Edo state) and given water liberally. The rats gained maximum acclimatization before actual commencement of the experiment. The Monosodium glutamate (3g/ sachet containing 99+% of MSG) was obtained from Kersmond grocery stores, Uselu, Benin City.

MONOSODIUM GLUTAMATE ADMINISTRATION: The rats in the treatment groups (A and B) were given 3g and 6g of MSG, thoroughly mixed with the g growers' mash, respectively. The control © group received equal amount of feeds (growers' mash) without MSG added for fourteen days. The rats were sacrificed on the fifteenth day of the experiment. The superior colliculus was quickly dissected out and fixed in 10% buffered formaldehyde for routine histological techniques. The 3g and 6g MSG doses were chosen and extrapolated in this experiment based on the indiscriminate use here in Nigeria due to its palatability. The two doses were thoroughly mixed with fixed amount of feeds (550g) in each group, daily.

HISTOLOGICAL STUDY: The tissue were dehydrated in an ascending grade of alcohol (ethanol), cleared in xylene and embedded in paraffin wax. Serial sections of 7 microns thick were obtained using a rotatory microtome. The deparaffinized sections were stained routinely with haematoxyline and eosin (H&E) method¹³.

Photomicrographs of the desired sections were made for further observations.

RESULTS

The control sections of the superior colliculus showed normal histological features with the neurons appearing distinct and the glial cells normal without vacuolations in the stroma (Figure 1).

The sections of the superior colliculus from the treatment groups showed some varying degree of reduced cellular population, based on its sparse distribution, degenerative changes, cellular hypertrophy, and intercellular vacuolations appearing in the stroma. The degenerative changes were more pronounced in the group that received 6g of MSG. (Figure 2, 3)

Figure 1

Figure 1: Control section of the superior colliculus (Mag. x400).

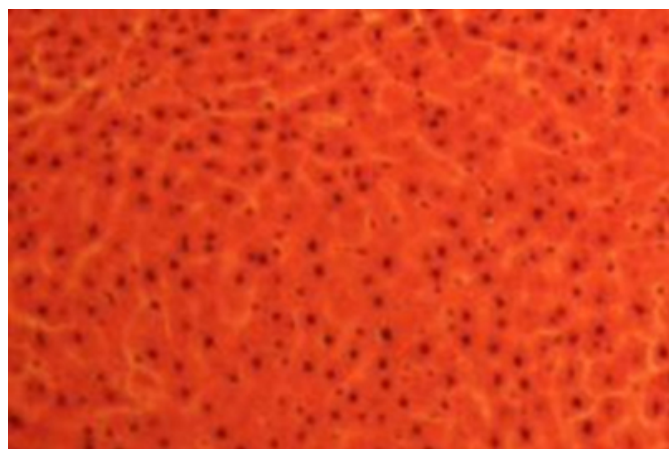


Figure 2

Figure 2: Treatment section of the superior colliculus (3g MSG) (Mag.x400)

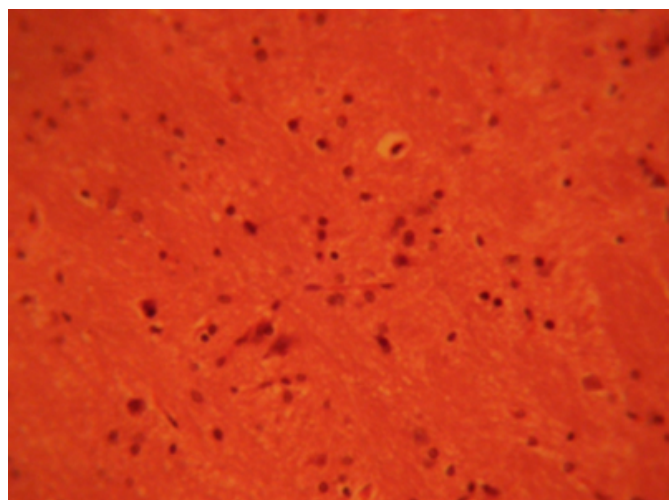
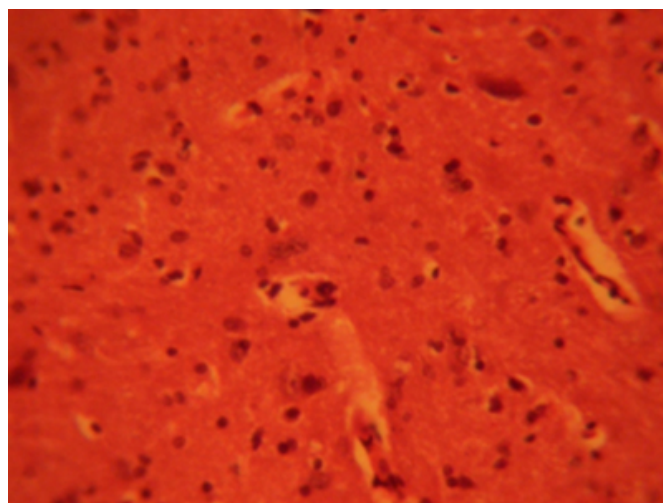


Figure 3

Figure 3: Treatment section of the superior colliculus (6g MSG) (Mag.x400)



DISCUSSION

The results (H & E) revealed that administration of MSG showed some decreased cellular population, degenerative changes, cellular hypertrophy and vacuolations which appeared in the stroma of the treatment groups compared with the control section of the superior colliculus. Neuronal degeneration has been reported to result in cell death, which is of two types, namely apoptotic and necrotic cell death. These two types differ morphologically and biochemically¹⁴. Pathological or accidental cell death is regarded as necrotic and could result from extrinsic insults to the cell such as osmotic, thermal, toxic and traumatic effects¹⁵. It was reported that cell death in response to neurotoxins might trigger an apoptotic death pathway within brain cells¹⁶. Cell death in response to neurotoxins occurs as a controlled event involving a genetic programme in which caspase enzymes are activated¹⁶.

The process of cellular necrosis involves disruption of the membranes structural and functional integrity. Cellular necrosis is not induced by stimuli intrinsic to the cells as in programmed cell death (PCD), but by an abrupt environmental perturbation and departure from the normal physiological conditions¹⁷.

Extensive cell death in the central nervous system is present in all neurodegenerative diseases¹⁶. The type of nerve cell loss and the particular part of the brain affected dictate the symptoms associated with an individual disease¹⁶. In this study MSG may have acted as toxin to the cells of the superior colliculus, affecting their cellular integrity and

causing defect in membrane permeability and cell volume homeostasis.

In cellular necrosis, the rate of progression depends on the severity of the environmental insults. The greater the severity of the insults the more rapid the progression of neuronal injury.¹⁸ The principle holds true for toxicological insult to the brain and other organs.¹⁷ The prime candidates for inducing the massive cell destruction observed in neurodegeneration are neurotoxins.¹⁶ These may be substances present in small amounts in the environment, or even naturally occurring chemicals such as glutamate used by the brain as transmitter's substances.¹⁶ The latter when present at a critical level can be toxic to the brain cells they normally excite.¹⁶ It is inferred from this results that prolonged and high dose of MSG resulted in increased toxic effects on the SC. The decrease in cellular population observed in this study may have been as a result of cell death caused by the toxic effect of MSG.

The vacuolations observed in the stroma of the superior colliculus in this experiment may be due to MSG interference.

CONCLUSION AND RECOMMENDATION

The results obtained in this study following the administration of 3g and 6g per day of MSG to adult Wistar rats, causes spares cellular population, cellular degenerative changes, cellular hypertrophy and vacuolations in the superior colliculus of adult Wistar rats. These results may probably affect the functions of the superior colliculus in visual sensibility in adult Wistar rats. It is recommended that further studies be carried out to corroborate these findings.

References

1. Allen GH. The genetic basis of diseases, in General pathology Churchill Livingstone Medical Division Longman Co. Ltd, N.York. Pp 35056. 1987
2. Moore KL. Congenital malformations due to environmental factors; Developing Humans. W.B. Saunders Co. Ltd, Philadelphia 2nd Ed Chap 8. pp 173-83, 2003
3. Biodun D, Biodun A. A spice or poison? Is monosodium glutamate safe for human consumption? National concord Newspaper;1993 4th Jan. p5.
4. Okwuraiwe PE. The role of food and Drug Administration and control (FDA&C) in ensuring the safety of food and food ingredients: A symposium held at Sheraton Hotel, Lagos. 1st Sept.1992: 6-15.
5. Rogers PP, Blundell JE. Umani and appetite: Effects of monosodium glutamate on hunger and food intake in human subjects. Phsiol. Behav. 1990: 486:801-4.
6. Belluardo M, Mudo G, Bindoni M. Effect of early destruction of the mouse arcuate nucleus by MSG on age dependent natural killer activity: Brain Res.1990, 534:225-333
7. Onakewhor JUE, Oforofuo IAO, Singh SP. Chronic administration of Monosodium glutamate Induces Oligozoospermia and glycogen accumulation in Wister rat testes. Africa J. Reprod Health 1998; 2(2): 190-197.
8. Oforofuo IAO, Onakewhor JUE, Idaewor PE: The effect of chronic admin. of MSG on the histology of the Adult wister rat testes: Bioscience Research Communications. 1997 Vol. 9, No. 2
9. Samuels A. The Toxicity/Safety of MSG; A study in suppression of information. Accountability in Research 1999: 6(4): 259-310.
10. Reczkowski D, Diamond D. Cells of origin of several efficient pathways from the superior colliculus in Galago senegalensis. Brain Research. 1978. 146: 351-357.
11. Altman AS, Bayer CS. Time of Origin of neurons of rat superior colliculus in relation to other components of the visual and visiomotor pathways. Experimental Brain Research.1981, 42: 424-434
12. Siesjo BK. Utilization of substrates by brain tissues. Brain energy metabolism. John Wiley and Sons, USA. 1978 101-130.
13. Drury RAB, Wallington EA, Cameron R: Carleton's Histological Techniques: 4th ed., Oxford University Press NY. U.S.A. 1967 279-280.
14. Wyllie AH. Glucocorticoid-induced thymocyte apoptosis in associated and endogenous endonuclease activation. Nature: London 1980 284:555-556.
15. Farber JL, Chein KR, Mitnacht S. The pathogenesis of Irreversible cell injury in ischemia; Ame J. Path.1981; 102:271-281
16. Waters CM. Glutamate induced apoptosis of striatal cells in rodent model for Parkinsonism. Neuroscience 1994 63:1-5
17. Martins LJ, Al-Abdulla NA, Kirsh JR, Sieber FE, Portera-Cailliau C. Neurodegeneration in excitotoxicity, global cerebral ischaemia and target deprivation: A perspective on the contributions of apoptosis and necrosis. Brain Res. Bull. 1978. 46(4). 281-309
18. Ito U, Sparts M, Walker JR, Warzo I. Experimental Cerebral Ischemia in Magolian Gerbils(1). Light microscope observations. Acta Neuropathology. USA. 32:209-223.

Author Information

A.O. Eweka

Department of anatomy, School of Basic Medical Sciences, College of Medical Sciences, University of Benin

F.A.E. Om'Iniabohs

Department of anatomy, School of Basic Medical Sciences, College of Medical Sciences, University of Benin