

Eagle's Syndrome: A Rare Presentation With Bilateral Otalgia And Review Of Literature

S Lerra, T Nazir, S Qadri, M Kirmani

Citation

S Lerra, T Nazir, S Qadri, M Kirmani. *Eagle's Syndrome: A Rare Presentation With Bilateral Otalgia And Review Of Literature*. The Internet Journal of Otorhinolaryngology. 2008 Volume 9 Number 2.

Abstract

Eagle's syndrome represents a group of symptoms that includes recurrent throat pain, globus pharyngeus, dysphagia, referred otalgia, and neck pain possibly caused by elongation of the styloid process or ossification of the stylohyoid or stylomandibular ligaments. We here present a case of 35 years old male with bilateral otalgia, tinnitus and recurrent throat pain. Diagnosis of bilateral elongated styloid process was made. Surgical shortening of the structure provided definitive relief of the patient's symptoms. We review the anatomy of the peristyloid structures and discuss the etiology, diagnosis, and treatment of Eagle syndrome.

INTRODUCTION

According to the Talmud (fifth century A.D.), the juice of a kidney was the recommended remedy for Otalgia. Eagle's syndrome as a cause of referred otalgia was first described by Watt W Eagle in 1937 into two distinct types—the classic type and the carotid artery type. The classic type is seen after tonsillectomy, when the patient experiences pain that is attributable to the stimulation of cranial nerves V, VII, IX, and X. Eagle theorized that these patients develop scarring near the styloid apex that subsequently compresses or stretches nerve structures in the space surrounding the styloid process. In the carotid artery type, symptoms occur when the elongated styloid process stimulates the sympathetic nerves in the carotid sheath. [12] The diagnosis of Eagle's syndrome is made by radiographic imaging and by physical examination when an elongated and calcified stylohyoid ligament can be palpated in the tonsillar area. We here present a case of Eagle's syndrome who presented with bilateral otalgia and tinnitus as chief complaint. This presentation of Eagle's syndrome is very rare and, to our knowledge, only one such case has been reported in English literature.

CASE REPORT

A 35 years old otherwise healthy male presented to ENT OPD of SKIMS medical college with chief complaints of bilateral otalgia, intermittent tinnitus and recurrent throat pain since two year. Pain was aggravated during swallowing especially solid food. He did not report

hoarseness or changes in his voice or impaired hearing. He had consulted various doctors earlier and was prescribed Tab. Carbamazepine 200mg TID by a neurologist. Initial response to pharmacotherapy was satisfactory but of late the episodes of otalgia and throat pain were getting more frequent and severe and tinnitus more persistent.

Examination- A complete head neck examination was done. Otoscopy; anterior and posterior rhinoscopy; and indirect laryngoscopy were within normal limits. Oropharyngeal examination showed grade II tonsillar enlargement with no sign of acute/chronic infection. On palpation in the tonsillar fossa, there was tenderness bilaterally but tip of the styloid process was not palpable in either of the tonsillar fossa..

Investigations: X-ray skull AP view (Fig.1) and CT scan with 3D reconstruction (Fig.2) were done and revealed bilateral styloid processes of more than 3cm length.

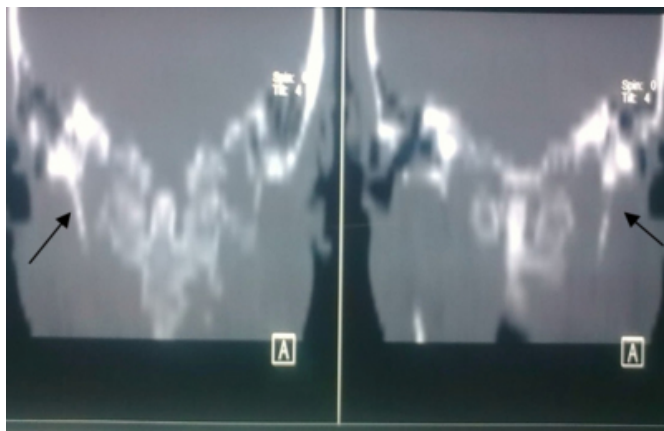
Figure 1

Figure 1: X-ray skull AP view showing bilateral elongated styloid processes (black arrow)

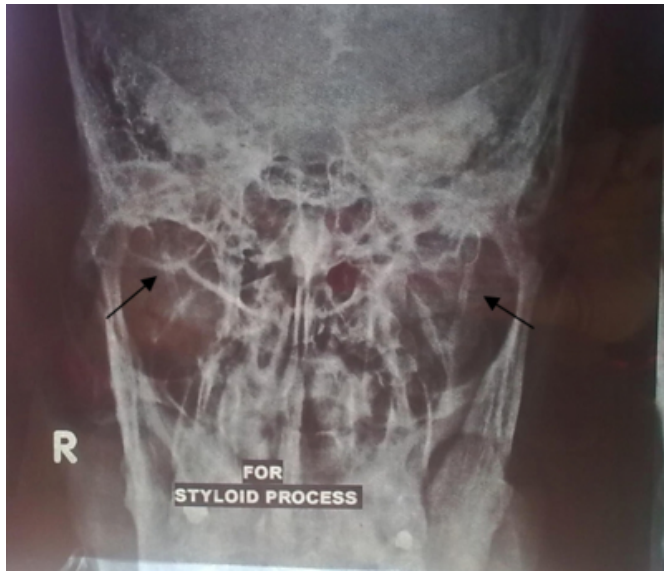

Figure 2

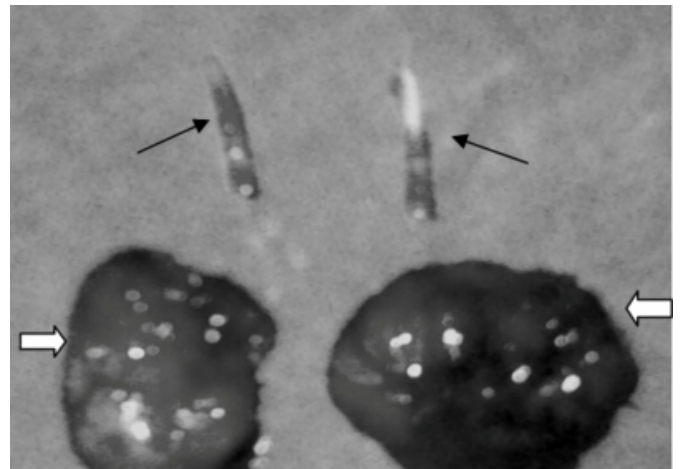
Figure 2: CT scan, reconstructed view, showing bilateral elongated styloid processes of more than 3cm length (black arrows)



X-ray soft tissue neck (AP and lateral)-WNL; Nasal endoscopy was normal. In view of the throat pain, referred otalgia, normal otoscopy and other examinations and radiological findings, the patient was diagnosed with the classic type of Eagle syndrome. Surgical treatment was done via transoral approach and tonsillectomy followed by partial styloidectomy was done bilaterally (Fig.3)

Figure 3

Figure 3: Post surgical specimen showing both the excised tonsils (white arrows) and bilateral styloid processes (black arrows).



Recovery was uneventful and patients' complaints of otalgia and pain throat were relieved and tinnitus was markedly improved at one month follow up.

DISCUSSION

The stylohyoid apparatus, which has a general embryogenesis (develops out of the second Reichert branchial arch), consists of the styloid process, 2 ligaments (stylohyoid and stylomandibular and 3 muscles (stylohyoid, styloglossus and stylopharyngeus) attached to the styloid process. The stylohyoid muscle connects the base of the styloid process to the hyoid bone near its greater horn; it is innervated by cranial nerve XII (hypoglossal). The styloglossus muscle arises from the anterior and lateral surface of the styloid process near the apex and descends forward between the branches of the internal and external carotid arteries. It then divides upon the lateral side of the tongue to blend with the fibers of the longitudinalis inferior linguae muscle and obliquely with the hyoglossus muscle. It is innervated by the facial nerve. The stylopharyngeus muscle traverses the medial aspect of the styloid process to the lateral wall of the pharynx; it is innervated by the glossopharyngeal nerve. The stylohyoid ligament connects the apex of the styloid process and the lesser horn of the hyoid bone, and the stylomandibular ligament extends from the styloid process to the parotidomasseteric fascia between the mandible and the mastoid process. The styloid process is a bony outgrowth of the temporal bone located between the internal and external carotid arteries and juxtaposed near cranial nerves VII, IX, X, XI (accessory), and XII.^[3] Eagle defined the length of a normal styloid process at 2.5-3.0

cm_[12]. Other authors have defined the normal length of styloid process variably as: Kaufman et al- less than 3 cm_[4]; Lindeman- from 2-3 cm_[5]; Montalbetti et al- less than 2.5 cm_[6]; Monsour and Young- less than 4 cm_[7]. An elongated styloid process occurs in about 4 percent; of the general population, while only a small percentage (between 4 - 10.3%;) of these patients are symptomatic. So the true incidence is about 0.16 percent; with a female-to-male predominance of 3:1_[2]. Bilateral involvement is common but bilateral symptoms are rare and the length of the styloid process has not been found to be correlated to the severity of symptoms.

Etiopathogenesis is still being debated. Eagle (1937-1948) considered surgical trauma (tonsillectomy) or local chronic irritation could cause osteitis, periosteitis, or tendonitis of the stylohyoid complex with consequent reactive, ossifying hyperplasia leading to irritation of the structures nearby._[12] Epifanio (1962) considered that the ossification of the styloid process was related to endocrine disorders in women at menopause, accompanied by the ossification of ligaments elsewhere (eg, iliolumbar, thyrohyoid)._[8] Lentini (1975) formulated the hypothesis that persistence of the mesenchymal elements (Reichert cartilage residues) could undergo osseous metaplasia as a consequence of trauma or mechanical stress during the development of the styloid process._[9] Monsour and Young (1986) considered that ossification of the stylohyoid ligament complex, caused contraction of the stylopharyngeal muscle and stretching of the XII cranial nerve _[7]

Clinical presentation of Eagle's syndrome can have two possible expressions. The "classic Eagle syndrome" is typically seen in patients after pharyngeal trauma or tonsillectomy, and it is characterized by ipsilateral dull and persistent pharyngeal pain, centered in the ipsilateral tonsillar fossa, that can be referred to the ear and exacerbated by rotation of the head. A mass or bulge may be palpated in the ipsilateral tonsillar fossa, exacerbating the patient's symptoms. Other symptoms include dysphagia, sensation of foreign body in the throat, tinnitus, or cervicofacial pain. The "second form" of the syndrome, carotid artery type, is characterized by the compression of the internal or external carotid artery (with their perivascular sympathetic fibers) by a laterally or medially deviated styloid process. It is related to a pain along the distribution of the artery, which is provoked and exacerbated by rotation and compression of the neck. It's not correlated with tonsillectomy. In case of impingement of the internal

carotid artery, patients often refer supraorbital pain and parietal headache. In case of external carotid artery irritation, the pain radiates to the infraorbital region

Lateral and AP views of the skull base and orthopantomographic x-rays have been used as adjuncts to diagnose Eagle syndrome. Although not essential, CT of the neck aids in discerning anatomic relationships and may rule out other conditions that produce similar symptoms.

The nonsurgical treatment of Eagle syndrome generally involves local injections of lignocaine with corticosteroid hormones, pharmacotherapy with anticonvulsants (e.g., carbamazepine) or antidepressants (e.g., amitriptyline), and anti-histamine preparations (e.g., diprazine) but results are short-lived as after 6-12 months the disease recrudesces to most of the patients_[10]. Long-lasting symptom relief requires the surgical removal of the elongated portion of the styloid process. Two surgical approaches have been described—*intraoral* and *extraoral*:

Intraoral. The advantages of the *intraoral* approach include less operating time and a more pleasing cosmetic result. The limitations include poor visibility leading to an increased risk of neurovascular injury, oral flora contamination, risk of deep neck space infection and the potential for postoperative airway obstruction secondary to pharyngeal edema

Extraoral. Conversely, the advantages of the *extraoral* approach are good visualization and a reduced risk of infection. The disadvantages are that it requires more surgical time and leaves a visible scar._[3]

In conclusion, Eagle's syndrome should always be considered in the differential diagnosis of bilateral otalgia with tinnitus and throat pain as it provides a chance of definitive cure for this otherwise frustrating symptomatology.

References

1. Eagle WW. Elongated styloid process: Report of two cases. *Arch Otolaryngol* 1937; 25:584–587.
2. Eagle W. Elongated styloid process: Further observation and a new syndrome. *Arch Otolaryngol*. 1948;47:630–640.
3. Kim E, Hansen K, Frizzi J. Eagle Syndrome: Case report and review of literature. *Ear nose and Throat J*. 2008;87(11):631-633
4. Kaufman SM, Elzay RP, Irish EF. Styloid process variation. Radiologic and clinical study. *Arch Otolaryngol*. 1970;91(5):460-463.
5. Lindeman P. The elongated styloid process as a cause of throat discomfort. Four case reports. *J Laryngol Otol* 1985;99(5):505-508.
6. Montalbetti L, Ferrandi D, Pergami P, et al. Elongated styloid process and Eagle's syndrome. *Cephalalgia*. 1995;15(2):80-93.

7. Monsour PA, Young WG. Variability of the styloid process and stylohyoid ligament in panoramic radiographs. Oral Surg Oral Med Oral Pathol 1986;61(5):522-526
8. Epifanio G. Processi stiloidei lunghi e ossificazione della catena stiloidea. Rad Prat. 1962;12:127-132.

9. Lentini A. Gli aspetti clinici e radiologici delle anomalie dell'apparato stilo-joido. Radiol Med. 1975;61:337-364.
10. Albinas Gervickas, Ricardas Kubilius, Gintautas Sabalys. Clinic, Diagnostics and Treatment Peculiarities of Eagle's syndrome Stomatologija, Baltic Dental and Maxillofacial Journal, 2004 6:11-13,

Author Information

Sandeep Lerra, MS (ENT)

Senior Resident, Department Of ENT, SKIMS Medical College

Tanvir Nazir, MS (ENT)

Senior Resident, Department Of ENT, SKIMS Medical College

Sajjad Mir Qadri, MS (ENT)

Senior Resident, Department Of ENT, SKIMS Medical College

Masod A. Kirmani, MS(ENT)

Associate Professor, Department Of ENT, SKIMS Medical College