

Treatment Of Complicated Major Trauma Of The Elbow And Forearm By The Musculo-Cutaneous Latissimus Dorsi Flap With A Skeletonized And Denervated Pedicle

A Bogdanov-Berezovsky, A Korengreen, J Groen, B Courchia, Y Shoham, E Silberstein, Y Krieger

Citation

A Bogdanov-Berezovsky, A Korengreen, J Groen, B Courchia, Y Shoham, E Silberstein, Y Krieger. *Treatment Of Complicated Major Trauma Of The Elbow And Forearm By The Musculo-Cutaneous Latissimus Dorsi Flap With A Skeletonized And Denervated Pedicle*. The Internet Journal of Plastic Surgery. 2009 Volume 7 Number 1.

Abstract

Major complicated injuries of the upper limb that once led to amputation are now being successfully salvaged. The goals of treatment in such cases are rigid fixation of fractures, reliable stable coverage of important structures, preservation of function and an acceptable cosmetic result. There is no consensus in the literature regarding the treatment strategy of upper limb trauma with damage distal to the olecranon. The latissimus dorsi musculocutaneous flap is often used for upper limb reconstruction for functional elbow restoration following different sorts of injuries [1-5]. We report two cases of major trauma of the elbow and forearm distal to the olecranon, that have been successfully treated by skeletonized, pedicled, denervated latissimus dorsi musculo-cutaneous flaps.

INTRODUCTION

Major complicated injuries of the upper limb that once led to amputation are now being successfully salvaged. The goals of treatment in such cases are rigid fixation of fractures, reliable stable coverage of important structures, preservation of function and an acceptable cosmetic result. There is no consensus in the literature regarding the treatment strategy of upper limb trauma with damage distal to the olecranon. The latissimus dorsi musculocutaneous flap is often used for upper limb reconstruction for functional elbow restoration following different sorts of injuries [1-5].

We report two cases of major trauma of the elbow and forearm distal to the olecranon, that have been successfully treated by skeletonized, pedicled, denervated latissimus dorsi musculo-cutaneous flaps.

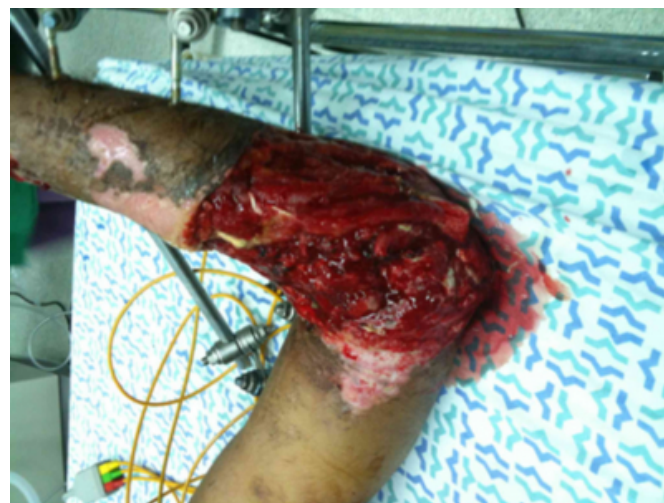PATIENTS AND METHODS

CASE 1

A 24 year old male was admitted to our hospital after being involved in a motor vehicle accident. At admission he was diagnosed as suffering from a crush injury of his right arm with an open comminuted fracture and dislocation of the right proximal radius and ulna (as seen in figure 1), and

fractures of metacarpal bones 4-5.

Figure 1



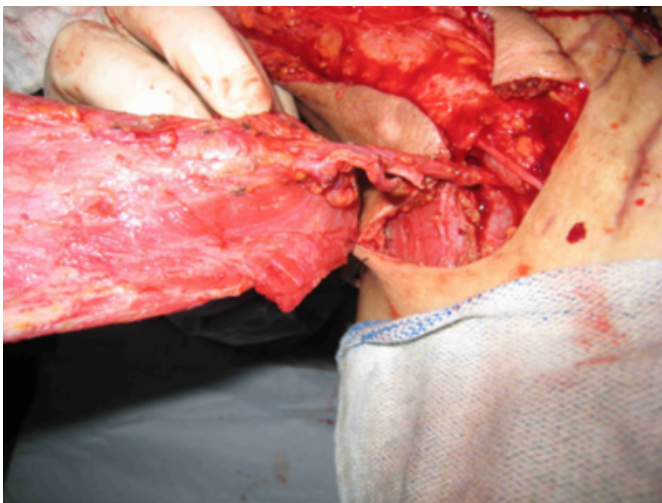
He initially underwent debridement of soft tissues, and a Vacuum Assisted Closure (VAC) device was applied. Afterwards, the patient underwent external fixation of the fractures and multiple sessions of lavage and debridement. One month after admission he underwent additional debridement of soft tissues and reconstruction of the defect by a Latissimus Dorsi (LD) musculo-cutaneous flap. The

flap was raised on its thoracodorsal pedicle and all the muscle attachments were divided. Additionally, the thoracodorsal nerve was divided and the pedicle was further elongated by dissection up to scapular circumflex vessels (as seen in figures 2-3).

Figure 2

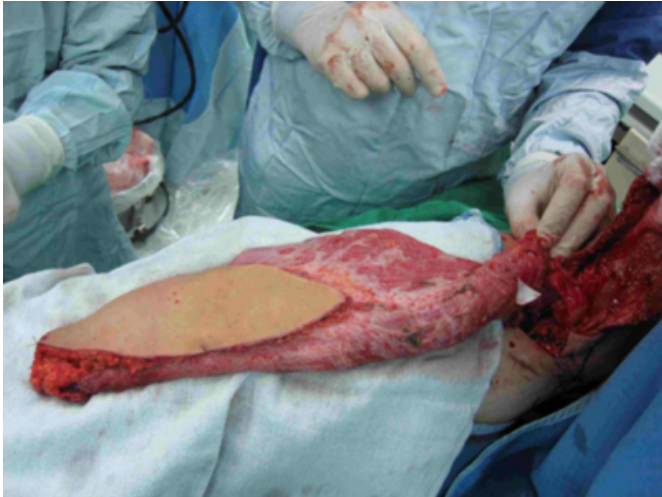

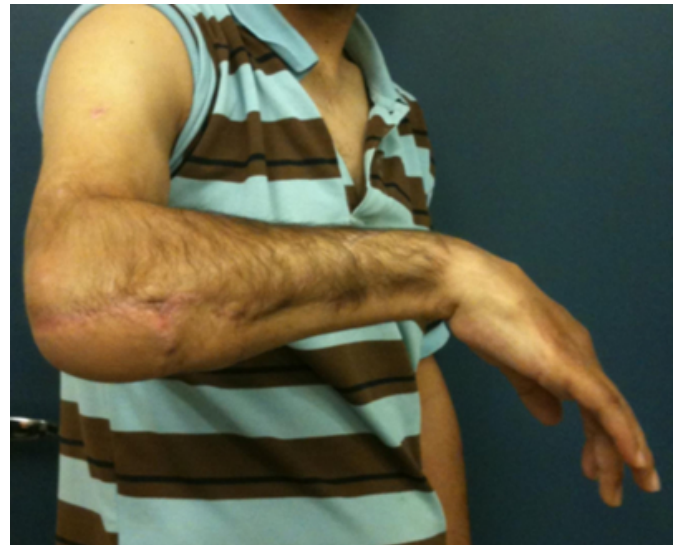Figure 3



Exposed elbow joint and bones were covered by the LD flap skin paddle, and the rest of the wound by the flap's muscle that was then covered by a split thickness skin graft. The wounds healed well, and successful flap coverage was achieved to a point six centimeters proximal to the distal wrist crease. After the successful operation the patient was referred to physiotherapy and occupational therapy. At 12 months follow up the patient has begun using his hand for basic daily activities (see figure 4).

Figure 4



CASE 2

A 32 year old male was admitted to our hospital after being involved in a motor vehicle accident during which his semi-trailer truck rolled over and his left upper limb was trapped under the cabin for approximately 90 minutes. He sustained a crush avulsion injury of his left upper limb with an open fracture dislocation of the elbow, with exposed olecranon and ulna. He initially underwent lavage, debridement and external fixation of the fractures, and the wound was treated by a VAC device. The patient underwent three additional sessions of lavage and debridement of unviable tissues. Eight days after admission the external fixation device was exchanged, reattachment of the triceps muscle was performed, and the elbow was covered by a LD musculo-cutaneous flap. The flap was raised in a similar manner to the one described earlier. The skin paddle was sutured onto the elbow and the rest of the muscle was grafted. The flap reached a point 10cm proximal to the distal wrist crease. After reconstructive surgery the patient continued a rehabilitation program. At 5 months follow up the patient demonstrated basic movement of his right forearm and hand.

DISCUSSION

Considerations for reconstruction of complex elbow and forearm wounds depend on the specific defect, patient demographics, donor site morbidity, and medical center capabilities [6]. Locoregional flap reconstruction is limited by the size of the defect, arc of rotation, and amount of available surrounding tissue. Microsurgical expertise, equipment and time are prerequisites for microsurgical free flap reconstruction. In addition, patient comorbidities and

age can preclude the long anesthetic times and the use of free flap transfer. In these cases, pedicled distant flap reconstruction may offer a satisfactory option for upper extremity limb salvage [7]. The aim of this paper is to describe our use of the LD flap as a pedicled distant flap for reconstruction of the elbow and forearm.

The first use of the LD flap is referred to Tansini in 1896 [8]. In 1956 the LD flap was used for the first time as a muscle transfer and for functional restoration of the elbow [9-10]. Further publications have shown advantages of LD flaps for salvage of major trauma of the elbow and forearm [11]. The LD muscle is a large triangular muscle of the back, averaging 180 cm² based on the pedicle containing the thoracodorsal artery, vein and nerve averaging respective lengths of 9.3, 9.1, and 12.3 cm's [12-13]. Ease of dissection (14) and great mobility afford the surgeon a great deal of coverage around the elbow (1, 2, 4, 5, 15-22).

The remarkable consistency of the LD muscle anatomy and its long arc of rotation around the pedicle allow accurate preoperative planning of reconstructive procedures with this flap [23]. Through careful dissection, planning and execution viable forearm coverage can be accomplished [1-5, 14-17, 23]. The limit of coverage was found to be the junction of the proximal and middle thirds of the forearm [3, 4]. The LD muscle is able to supply well vascularized tissue coverage of the defect, eliminates any dead space, and improves outcome in cases of infection [22, 24].

The donor site is distant from the site of injury, and there is minimal donor site morbidity [25-27]. The operation is performed in one stage thus allowing earlier rehabilitation and improved patient outcomes [14]. Any muscular deficits at the donor site are minimized due to recruitment of synergistic muscles thus minimizing decreases in shoulder strength and motion [27]. Complications are uncommon, including donor site seromas, hematomas, infection and flap distal necrosis [28].

It has been postulated that distal necrosis can be a factor of both stretch of the flap and diminishing cutaneous perforators distally [10]. For these reasons Stevanovic recommended that the LD flap not be used routinely to cover defects more than eight centimeters distal to the olecranon [14]. However, success with LD flap coverage at distances greater than eight centimeters has been previously reported [1, 3-4], and our report concurs with these reports.

In our two reported cases, the pedicle of the flap was

skeletonized and dissected to the scapular circumflex vessels. The thoracodorsal nerve was additionally divided. These measures significantly elongate the distal zone of coverage up to the distal third of forearm.

CONCLUSION

The LD musculo-cutaneous flap is a reliable choice for post-traumatic reconstruction of complicated injuries of the upper limb. It provides stable coverage of the elbow and forearm. In our experience, skeletonization of the thoracodorsal pedicle, dissection to the scapular circumflex vessels and division of the thoracodorsal nerve, significantly elongate the pedicle and permit successful coverage of traumatic injuries as distal as the distal third of the forearm. Reconstruction by the LD flap is a simple and reasonable reconstructive option with minimal complications and minimal donor site morbidity. Due to the above and to the fact that the donor site is located far from the zone of injury, reconstruction by the LD flap may spare free flap coverage thus saving valuable time and expenses.

References

1. Jutte DL, Rees R, Nanney L, Bueno R, Lynch J. Latissimus dorsi flap: a valuable resource in lower arm reconstruction. *South Med J*. 1987; 80:37-40.
2. Delay E, Foyatier JL, El Kollalil R, Comparin JP, Weill E, Latarjet J. Salvage of extensively burned upper limbs by a pedicled latissimus dorsi flap. *Burns*. 1995; 21:449-452.
3. Sherman, R. Soft-tissue coverage for the elbow. *Hand Clin*. 1997; 13: 291-302.
4. Stern PJ, Carey JP. The latissimus dorsi flap for reconstruction of the brachium and shoulder. *J Bone Joint Surg Am*. 1988; 70:526-535.
5. Sadove RC, Vasconez HC, Arthur KR, Draud JW, Burgess RC. Immediate closure of traumatic upper arm and forearm injuries with the latissimus dorsi island myocutaneous pedicle flap. *Plast Reconstr Surg* 1991; 88:115-120.
6. Herter F, Ninkovic M, Ninkovic M. Rational flap selection and timing for coverage of complex upper extremity trauma. *J Plast Reconstr Aesthet Surg* 2007; 60:760-768
7. O'Shaughnessy KD, Rawlani V, Hijjawi JB, Dumanian GA. Oblique pedicled paraumbilical perforator-based flap for reconstruction of complex proximal and mid-forearm defects: a report of two cases. *J Hand Surg Am*. 2010 Jul; 35(7):1105-10. Epub 2010 Jun 11.
8. Lassen M, Krag C, Nielsen I. The Latissimus Dorsi Flap: An Overview. *J of Plast and Reconstr Surg and Hand Surg* 1985; 19: 41-51.
9. Shottstaedt ER, Larsen LJ, Bost FC. Complete muscle transposition. *J Bone Joint Surg*. 1955; 37A: 897.
10. Pierce T, Tomaino M. Use of the Pedicled Latissimus Muscle Flap for Upper-Extremity Reconstruction. *J Am Acad Orthop Surg* 2000; 8:324-331.
11. Peve WC, Hendricks D, Rosenthal MS, Shestak KC, Steed DL, Webster MN. Revascularization of the ischemic limb by use of a muscle pedicle flap: A rabbit model. *J Vasc Surg*. 1991; 13: 385.

12. Hui KCW, Zhang F, Sutkin H, Wu P, Tingley S, Lineaweaver WC. Functional assessment of the shoulder following latissimus dorsi muscle donation in the handicapped. *J Reconst Microsurg.* 1999; 15:101-103.
13. Barlett SP, May JW, Yaremchuk MJ. The latissimus dorsi muscle: a fresh cadaver study of the primary neurovascular pedicle. *Plast Reconstr Surg.* 1981; 67:631.
14. Stevanovic M, Sharpe F, Itamura J. Treatment of soft tissue problems about the elbow. *Clinical orthopaedics and related research.* 2000; 270:127-137.
15. Chang LD, Goldberg NH, Chang B, Spence, R. Elbow defect coverage with a one-staged, tunneled latissimus dorsi transposition flap. *Ann Plast Surg.* 1994 32:496-502.
16. MacKinnon S, Weiland AJ, Godina M. Immediate Forearm Reconstruction with a Functional Latissimus Dorsi Island Pedicle myocutaneous flap. *Plast and Reconstr Surg.* 1983; 71(5):706-710.
17. Minami A, Ogino T, Ohnishi N, Itoga H. The latissimus dorsi musculocutaneous flap for extremity reconstruction in orthopedic surgery. *Clin Orthop.* 1990; 260: 201-206.
18. Axer A, Segal D, Elkon A. Partial transposition of the latissimus dorsi. A new operative technique to restore elbow and finger flexion. *J Bone Joint Surg Am.* 1973; 55:1259-1264.
19. Bostwick J, Nahai F, Wallace JG, Vasconez LO. Sixty latissimus dorsi flaps. *Plast Reconstr Surg.* 1979; 63:31-41.
20. Pruzansky M., Kelly M., Weinberg H. Latissimus dorsi musculocutaneous flap for elbow extension. *J Surg Oncol.* 1991; 47:62-66.
21. Angrigiani C, Grilli D, Siebert J. Latissimus dorsi musculocutaneous flap without muscle. *Plast Reconstr Surg.* 1995; 96:1608-1614.
22. Brones MF, Wheeler ES, Lesavoy MA. Restoration of elbow flexion and arm contour with the latissimus dorsi myocutaneous flap. *Plast Reconstr Surg.* 1982; 69; 329-332.
23. Ma C, Tu Y, Wu C, Yen C, Yu S, Kao F. Injury. *Int. J Care Injured.* 2008; 3954:S67-S74.
24. Calderon W, Chang N. Mathes SJ. Comparison of the effect of bacterial inoculated in musculocutaneous and fasciocutaneous flaps. *Plast Reconstr Surg* 1986; 77:785-94.
25. Gustilo RB, Mendoza RM, Williams DN. Problems in the management of type III (severe) open fractures: a new classification of type III open fractures. *J Trauma.* 1984; 24:742-746.
26. Pierce TD, Tomaino MM. Use of the pedicled latissimus muscle flap for upper-extremity reconstruction. *J Am Acad Orthop Surg.* 2000 8:324-311.
27. Russell RC, Pribaz J, Zook EG, Leighton WD, Eriksson E, Smith, CJ. Functional evaluation of latissimus dorsi donor site. *Plast Reconstr Surg.* 1986; 78:336-344.
28. Jensen M, Moran S. Soft tissue coverage of the elbow: A reconstructive Algorithm. *Orthopedic clinics of North America.* 2008; 39(2):251-264.

Author Information

Alex Bogdanov-Berezovsky

Department of Plastic and Reconstructive Surgery, Soroka University Medical Center

Amir Korengreen

Department of Orthopedic Surgery, Soroka University Medical Center

Jeremiah Groen

Faculty of Health Sciences, Ben-Gurion University of the Negev

Benjamin Courchia

Faculty of Health Sciences, Ben-Gurion University of the Negev

Yaron Shoham

Department of Plastic and Reconstructive Surgery, Soroka University Medical Center

Eldad Silberstein

Department of Plastic and Reconstructive Surgery, Soroka University Medical Center

Yuval Krieger

Department of Plastic and Reconstructive Surgery, Soroka University Medical Center