

# Fetal Megacystis At 10-14 Weeks Of Gestation Associated With Normal Nuchal Translucency And Normal Karyotype: A Case Report

? Apostolodis, C Karidas, ? Tantsis, I Stamatellos, S Pepes, A Athanasiadis, J Bontis

## Citation

? Apostolodis, C Karidas, ? Tantsis, I Stamatellos, S Pepes, A Athanasiadis, J Bontis. *Fetal Megacystis At 10-14 Weeks Of Gestation Associated With Normal Nuchal Translucency And Normal Karyotype: A Case Report*. The Internet Journal of Gynecology and Obstetrics. 2005 Volume 6 Number 1.

## Abstract

We present a congenital megacystis case which was diagnosed at the 13th gestational week during ultrasound scan examination for nuchal translucency in a primigravida. The discussion is about the diagnostic possibilities of the congenital megacystis in the first trimester of gestation and the increased risk of chromosomal anomalies in correlation to the maximal longitudinal diameter of the urine bladder.

## INTRODUCTION

Ultrasound scan at 11-14 weeks of gestation has led to the early diagnosis of many congenital fetal anomalies, which raises the need for earlier genetic consulting to give a more appropriate intervention to these anomalies. One such congenital anomaly is the fetal megacystis, which has only an incidence of 0.06 – 0.3 %, but it represents a management dilemma to its treatment. Megacystis is defined as a condition in which the maximal longitudinal diameter of the bladder is 7 mm or more. Very few research works refer to the presence of megacystis in the first trimester of gestation.

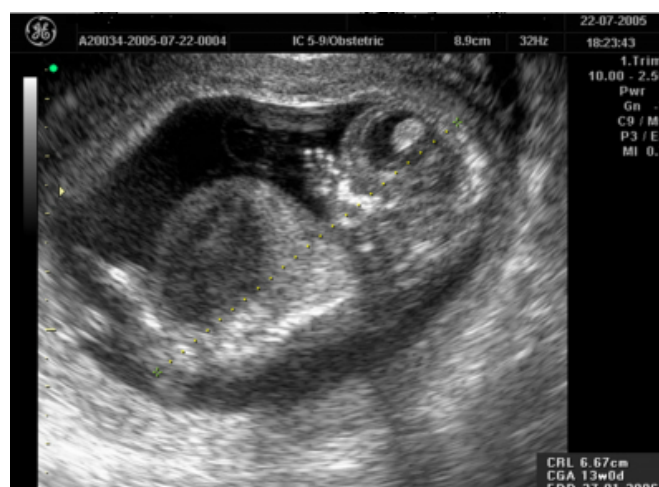## CASE REPORT

A 36 year old lady, with no significant obstetric history, had an ultrasound scan at 13 weeks of gestation. The gestation was the result of IVF with microfertilisation.

The fetal biometry corresponded to a 13+2 weeks, with a CRL of 67,3 mm. NT was 2,33 mm (Figures 1,2) In the ultrasound scanning of the abdominal region a cystic structure was detected with a maximum longitudinal diameter of 35.6 mm, extending from the pelvis to the diaphragm, and in absence of any ascitic fluid collection or any other fetal abnormalities. (Figure 3)

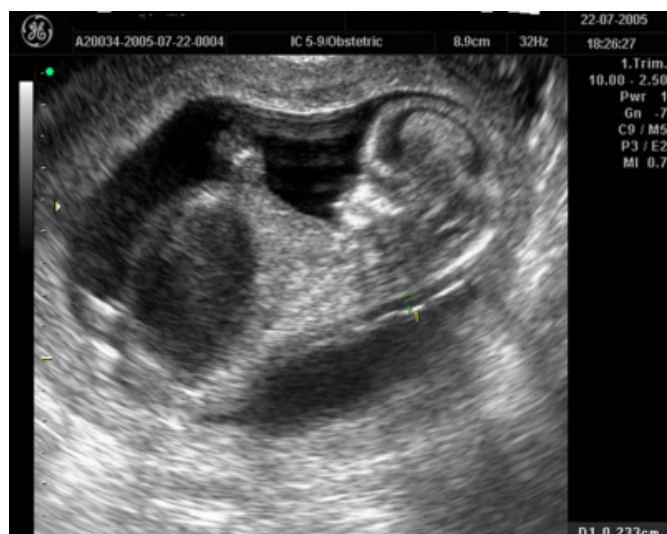## Figure 1

Figure 1: Fetal CRL



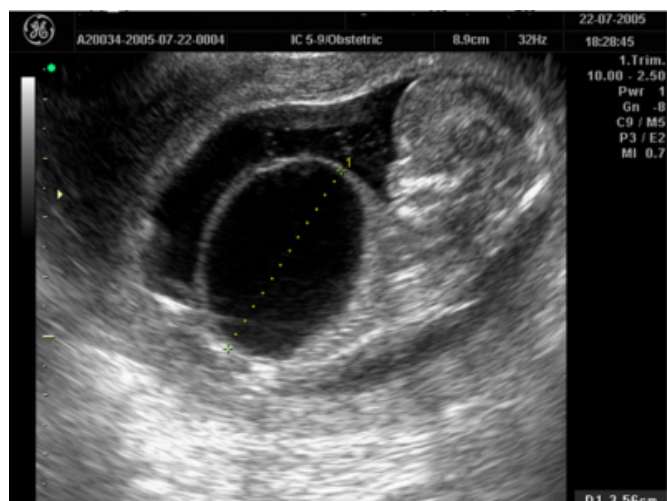
**Figure 2**

Figure 2: Nuchal translucency of the fetus.



**Figure 3**

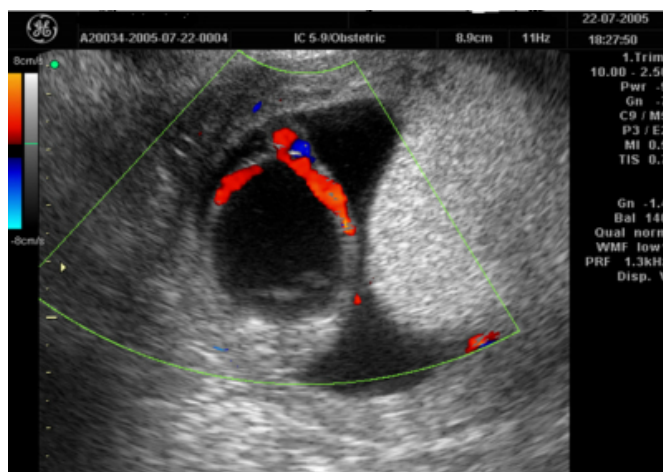
Figure 3: Diameter of the cystic structure.



On the colour Doppler the characteristic bifurcation of the umbilical vessels around the bladder was visualised after entering the anterior abdominal wall, confirming the diagnosis of congenital megacystis. (Figure 4)

**Figure 4**

Figure 4: Doppler ultrasound scan of the cystic structure with the presence of the separation of the umbilical artery after its entrance in the abdominal wall.



The possibility of chromosomal abnormality, poor outcome of the pregnancy and the chance of terminating the pregnancy, were explained and discussed. Minimal invasive prenatal diagnosis such as chorionic villous sampling biopsy or amniocentesis has been also discussed for chromosome and karyotype control of the fetus. The parents decided for chorionic villous sampling (CVS) biopsy which has been performed two days after the ultrasound scan control. A 20 mm needle has been used for transabdominal CVS and adequate chorionic villous sample was acquired for karyotyping.

During CVS, paracentesis of the cystic structure was performed and 18 cc of clear yellowish fluid were acquired. Biochemical analysis of the sample was performed, and showed that Na concentration was 120 mmol/l. The fetal karyotype by PCR within 48 hours as well as by cell culture of the fetal chorionic villous cells showed normal female fetus.

One week later, at the 14/40, on the ultrasound scan control, the size of the cyst seemed to be normal. On a repeated ultrasound scan control at the 16 weeks, intra uterine death was ascertained and artificial pharmaceutical abortion was induced. The parents did not consent for post-mortem examination and thus this was not performed for the fetus.

## DISCUSSION

Various second trimester urinary tract defects, such as, megacystis, hydroureter, hydronephrosis and their association with chromosomal defects and renal damage are

well described in the literature. Only few studies describe fetal megacystis in the first trimester. It is a rare malformation of the bladder between 10 – 14 weeks and it is defined by a longitudinal bladder diameter of 7 mm or more. Normally fetal bladder at this gestational age is measured less than 6 mm and the diameter/CRL ratio is <10%.

Fetal megacystis at 10-14 weeks has a prevalence of 1-1500 pregnancies. In the study of Liao et al, it was observed that fetuses with a longitudinal bladder diameter between 7-15 mm have a risk of chromosomal defects, mainly trisomy 13 and 18, of about 25%. In this bladder diameter range and in absence of chromosomal defects, the megacystis will resolve in about 90% of the fetuses without any obvious adverse consequences on the development of the fetal urinary tract (1). This could be possibly explained by the anatomic structure of the bladder until the 13<sup>th</sup> week of gestation which does not include any contractile elements, but only urothelium covered by connective tissue (2, 3). In contradiction to the above, fetal megacystis with longitudinal bladder diameter of >15mm had a chromosomal defect risk of 10% only and the chromosomally normal group had an increased risk of progressive Low Obstructive Uropathy (4)

Similar results were shown by Sebire et al in their study which had a prevalence of 1-1600 pregnancies. In their study visualisation of the bladder has also been examined and the bladder diameter was compared with the fetal CRL. The control group showed a significant increase of bladder length with CRL, but at 10-14 weeks the bladder diameter was <6 mm and the diameter/CRL ratio <10%. Fetal bladder was always visible when CRL was >67mm which was not the case in 9% of fetal bladders with fetal CRL between 38-67mm. These results are similar to those of Green and Hobbins who visualised the bladder by TAS in all cases at the 13<sup>th</sup> gestational week but only in 50% at the 10<sup>th</sup> gestational week (5). Using TAS and TVS, fetal bladder can be visualised in 98% of the cases (6). In this study megacystis was reported in 15 cases. In 3/15 of the cases, chromosomal abnormalities were detected. In the correspondent group without chromosomal defects, 7/15 megacystic cases where normally resolved and 4/15 cases progressed to severe Low Obstructive Uropathy. In all cases where megacystis resolved the bladder diameter was 8-12 mm. and the diameter/CRL ratio was 13-22%, which was the fact only in one case with progressive megacystis. In contrast, the other 3 progressive megacystis with Low

Obstructive Uropathy had a bladder length of >16 mm and a diameter/CRL ratio >28 % (4).

Favre et al reported an incidence of 1- 400 of megacystis in unselected population. Chromosomal defects such as trisomy 13, 18, 21 where found in 4/5 of the fetuses in his study of megacystis with bladder length between 9-15 mm, although none in his 10 cases with measurements of bladder diameter >15 mm (7).

Megacystis is also associated with other fetal abnormalities such as increased NT, which was observed in 75% of fetuses with chromosomal abnormalities and only in 30% of fetuses without chromosomal defects (8). This could be possibly explained by the thoracic compression due to the megacystis, which is also observed in other fetal defects, such as diaphragmatic hernia and skeletal dysplasias associated with narrow thoracic cage (8). Further more, other fetal abnormalities such as exomphalos, ventriculomegaly and chromosomal defects, are more commonly associated with milder degrees of megacystis (6), as well as malformation such as anorectal atresia and intestinal volvulus (7, 10).

Animal studies performed by Glick et al have demonstrated that Low Obstructive Uropathy can cause renal dysplasia. The extend of the renal damage depends on the onset point of the obstruction as well as its duration. These studies also described that shunting operations could improve the function of the urinary tract, reducing the degree of the renal damage (11, 12).

However the results of studies from vesicoamniotic shunting performed in human fetuses where not conclusive about the benefits of the operation. The reasons being, that irreversible renal damage was already established at the time of operation at the mid trimester and that such operations are associated with increased risk of miscarriage, which would outweigh any potential benefits (12, 13, 14).

## CORRESPONDENCE TO

Dr Apostolidis Aristotelis Obstetrician-Gynaecologist 16 Pavlou Mela str Diagonios Thessaloniki-54622 GREECE  
Tel/Fax: +2310244929 Mob: +6944500197 E mail: telis60@yahoo.gr

## References

1. W. Liao, N. Sebire, L. Geerts, S. Cicero and K. H. Nikolaides. Megacystis at 10-14 weeks of gestation: Chromosomal defects and outcome according to bladder

- length. *Ultrasound Obstetrics and Gynaecology* 2003; 21: 338-341
2. Gilpin SA, Gosling JA. Smooth muscle in the wall of the developing human urinary bladder and urethra. *Journal anatomy* 1983; 137: 503-512
3. Newman J, Antonakopoulos GN. The fine structure of the human fetal urinary bladder: development and maturation. *Journal Anatomy* 1989 ;166 :135-150
4. N. J. Sebire, C.von Kaisenberg, C. Rubio, R. J. M. Snijders and K. H. Nikolaides Fetal megacystis at 10-14 weeks of gestation. *Ultrasound Obstetrics and Gynaecology* 1996; 8: 387-390
5. Green J.J., and Hobbins J.C. Abdominal ultrasound examination of the first trimester fetus. *American Journal of Obstetrics and Gynaecology*, 1998; 159:165-175
6. Braithwaite, J.M. Armstrong M.A. and Economides D.L. Assessment of fetal anatomy at 12 to 13 weeks of gestation by transabdominal and Transvaginal sonography. *British Journal Obstetrics and Gynaecology*, 1996; 103: 82- 85
7. R. Favre, M. Kohler, B. Gasser, F.Muller and I. Nissand. Early fetal megacystis between 11-15 weeks of gestation. *Ultrasound Obstetrics and Gynaecology* 1999; 14: 402- 406
8. Souka AP, Snijders RJ, Navakov A, Soares W, Nikolaides KH. Defects and syndromes in chromosomally normal fetuses with increased nuchal translucency thickness at 10-14 weeks of gestation. *Ultrasound Obstet Gynecol.* 1998; 11: 391- 400.
9. K. H. Nicolaides, R. J. Snijders, C. M. Gosden, C. Berry, S Campbell. Ultrasonographically detectable markers of fetal chromosomal abnormalities. *The Lancet* 1992; 340:704 - 707.
10. Bierkens AF, Feitz WFJ, Nijhuis JG, de Wildt MJAM, Flos MSJ, de Vries JDM. Early Urethral Obstruction Sequence: a lethal entity? *Fetal diagnosis Therapy* 1996; 11: 137- 145.
11. P. L. Glick, M. R. Harrison, R. A. Noall and R. L. Villa. Correction of congenital Hydronephrosis in Utero III. Early mid - trimester Ureteral Obstruction produces renal dysplasia. *Journal of paediatric surgery* 1983; 18: 681- 687.
12. M. R. Harrison, D. K. Nakayama R. A. Noall and A. A. de Lorimer. Correction of congenital hydronephrosis in Utero. II. Decompression reverses the effect of obstruction on the fetal lung and urinary tract. *Journal of paediatric surgery* 1982; 17: 965 - 974.
13. P. L. Glick, M. R. Harrison, N. S. Adzick, R. A. Noall and R. L. Villa. Correction of congenital hydronephrosis in Utero. IV. In utero decompression prevents renal dysplasia. *Journal of paediatric surgery* 1984; 19: 649 - 57.
14. S. G. M. Carroli, P. W. Shoothill, J. Tizard and P. M. Kyle. Vesicocentesis at 10-14 weeks of gestation for treatment of fetal megacystis. *Ultrasound Obstetrics and Gynaecology* 2001; 18: 366-370.

**Author Information**

**†ristotelis Apostolodis**

"Genesis" Gynecological Clinic

**Christos Karidas**

"Genesis" Gynecological Clinic

**†ntonios Tantsis**

First University Department of Obstetrics and Gynaecology, Papageorgiou General Hospital, Periferiaki Odos Neas Eukarpias

**Ioannis Stamatellos**

First University Department of Obstetrics and Gynaecology, Papageorgiou General Hospital, Periferiaki Odos Neas Eukarpias

**Spiros Pepes**

"Genesis" Gynecological Clinic

**Apostolos Athanasiadis**

First University Department of Obstetrics and Gynaecology, Papageorgiou General Hospital, Periferiaki Odos Neas Eukarpias

**John Bontis**

First University Department of Obstetrics and Gynaecology, Papageorgiou General Hospital, Periferiaki Odos Neas Eukarpias