Splenic torsion, an unusual cause of acute abdominal pain.

M Murthy, S Rajani, K Bhagheerathi

Citation

M Murthy, S Rajani, K Bhagheerathi. *Splenic torsion, an unusual cause of acute abdominal pain.*. The Internet Journal of Radiology. 2008 Volume 10 Number 2.

Abstract

Torsion of spleen is a rare cause of acute abdominalpain leading to splenic infarction. We report a case of splenic torsion in a middle aged female and highlight the role of CT in its diagnosis.

CASE HISTORY

A 36 yrs old female reported to the Casualty

Department with complaints of severe abdominal pain all over the

abdomen of few hours duration. Clinical examination revealed

nondistended abdomen with tenderness and guarding in the left

hypochondrium. USG revealed moderately enlarged spleen in a

more anterior location in left hypochondrium. Plain CT showed an

enlarged spleen in ectopic position anterior to stomach (Fig. 1)

Figure 1

with a hyperdense foci in the vascular pedicle of spleen [black

arrow in (Fig. 2)].

Figure 2

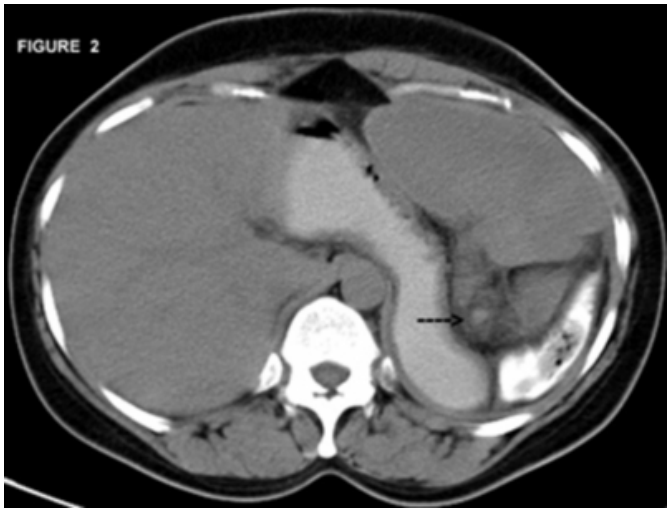

representing acute thrombus secondary to stasis. CECT scan

revealed a nonenhancing enlarged spleen in the ectopic

position (Fig. 3)

Figure 3

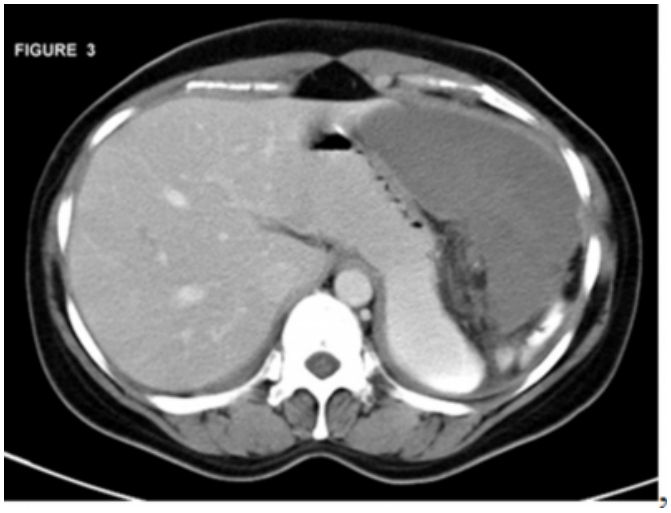

with a classical whorled appearance of the splenic vascular pedicle

[black arrows in (Fig 4)].

Figure 4

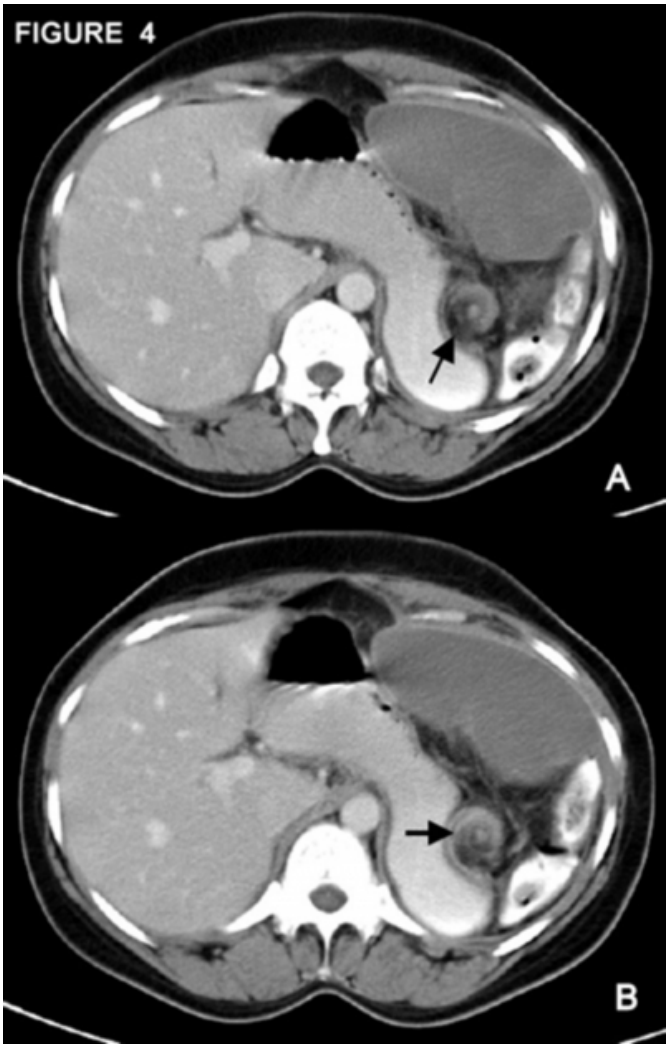

suggesting torsion with infarction. In view of these findings

laprotomy and splenectomy was done. Intraoperatively the splenic

vascular pedicle was twisted at least to 540 degrees.

DISCUSSION

Splenic torsion is a rare cause of acute abdominal

pain due to hypermobile wandering spleen. It has been diagnosed

in approximately 0.3 % of 1,413 cases of splenectomy in a study

by Eraklis et al [1] . Wandering spleen is an uncommon condition

characterized by laxity of the supporting ligaments [2] . Incomplete

development/laxity of the anchoring ligaments of spleen –

gastrolienal, lienorenal ligaments leads to the hypermobility

resulting in wandering of spleen to an ectopic position and

subsequently torsion [3,4] . The laxity of ligament is due to the

incomplete fusion of dorsal mesogastrium with the peritoneum that

overlies the left kidney leading to the development of long vascular

pedicle contributing to hypermobility [5] .

In adults especially women, splenic torsion is attributed to acquired

abnormality such as ligament laxity, splenomegaly, trauma and

hormonal effects of pregnancy.[6]

Symptoms vary with the degree of torsion 90 – 2160 degrees,

presenting as an incidental mass on physical examination, mild

abdominal pain due to vascular congestion, acute abdomen due to

torsion of splenic pedicle with infarction [5] . Pain is usually caused

by the capsular stretching and local peritonitis [6] .

In plain radiograph, it may appear as an abdominal mass with
absence of splenic shadow in left upper quadrant or as a large mass

in the left flank[7] . Ultrasound reveals splenomegaly with

heterogenous echotexture in ectopic position. Color Doppler shows

decreased perfusion due to torsion [8]. CECT reveals the ectopic

position of the enlarged spleen with little or no contrast

enhancement [5,8]. Swischuk et al[3] described the whorled

appearance of the twisted vascular pedicle of spleen as a valuable

finding in making the diagnosis.

The current treatment for splenic torsion with infarction is

Splenectomy [4,7].

References

1. Eraklis AJ,Filler RM. Splenectomy in childhood: a review of
1413 cases. J Pediatr Surg 1972:382-388.
2. Abell J. Wandering spleen with torsion of the pedicle. Ann
Surg 1933;98:722-735.
3. Swischuk LE, Williams JB, John SD. Torsion of wandering spleen : the whorled appearance of the splenic pedicle on CT. Pediatr Radiol 1993; 23:476-477.
4. Balm R, Willekens FGJ.Torsion of wandering spleen. Eur J Surg 1993;159:249-251.
5. Thomas E. Herman and Marilyn J. Siegel. CT of acute splenic torsion in children with wandering spleen. AJR Am J Roentgenol 1991;156:151-153.
6. Peitgen K, Schweden K. Management of intermittent splenic torsion (“wandering spleen”): a review. Eur J Surg 1995; 161:49-52.
7. Gordan DH, Burrell MI, Levin DC, Mueller CF, Becker JA. Wandering spleen: the radiological and clinical spectrum. Radiology 1977;125:39-46.
8. Nemcek AA,Miller FH, Fitzgerald SW. Acute torsion of wandering spleen: diagnosis by CT and duplex Doppler and color flow sonography. AJR Am J Roentgenol 1991;157:307-309.

Author Information

MGK Murthy, MD, DNB
Consultant radiologist Yashoda Hospital, Hyderabad, Andhra Pradesh , India.

S. Rajani, DNB
Consultant radiologist, Prime and Yashoda Hospital , Hyderabad, Andhra Pradesh, India

K. Bhagheerathi, DNB
Radiology Resident , Yashoda Hospital, Hyderabad, Andhra Pradesh, India