

Primary Intramuscular Hydatids In Vastus Lateralis And Adductor Magnus Muscles

A Hakeem, H Shafi, T Gojwari, S Rasool, M Ahmad

Citation

A Hakeem, H Shafi, T Gojwari, S Rasool, M Ahmad. *Primary Intramuscular Hydatids In Vastus Lateralis And Adductor Magnus Muscles*. The Internet Journal of Orthopedic Surgery. 2007 Volume 10 Number 2.

Abstract

Hydatid disease is a zoonosis and is caused by *Echinococcus granulosus*. Infected dogs release eggs through feces which infect humans through food and water. Most common locations of hydatid cysts are liver and lungs however intra muscular involvement though rare can be encountered. We report a case of primary intramuscular hydatid cyst in vastus lateralis and adductor magnus muscle.

CASE REPORT

A 54 year old woman presented to the department of surgery with a slow growing swelling in the medial aspect of her right thigh for last 11 months. The swelling was painless without any association with fever or weight loss. On physical examination the swelling was firm, free from underlying bone, non pulsatile, nontender and cystic fixed to the deep soft tissue having smooth surface. The swelling was 4 x 4 cms in dimension. The ipsilateral hip and knee movements and distal pulses were normal. No definite groin lymphadenopathy was seen. The remainder of the physical examination was unremarkable. Her hemogram, liver function tests and indirect hemagglutination test were normal. Patient was sent to department of radiology for soft tissue ultrasonography which showed cystic lesion with internal membrane like structure. Subsequently patient's whole abdominal ultrasound was done which was normal except for a small uterine fibroid. Further, contrast enhanced CT Scan of thigh was done on 64 slice multidetector row CT scan which showed two cystic lesion in right thigh with out any wall enhancement, largest one arising from adductor magnus muscle and another arising from vastus lateralis (fig. 1, 2 & 3).

Figure 1

Figure 1: coronal contrast enhanced MDCT image showing a hypodense cystic lesion without any wall enhancement in right adductor magnus muscle.

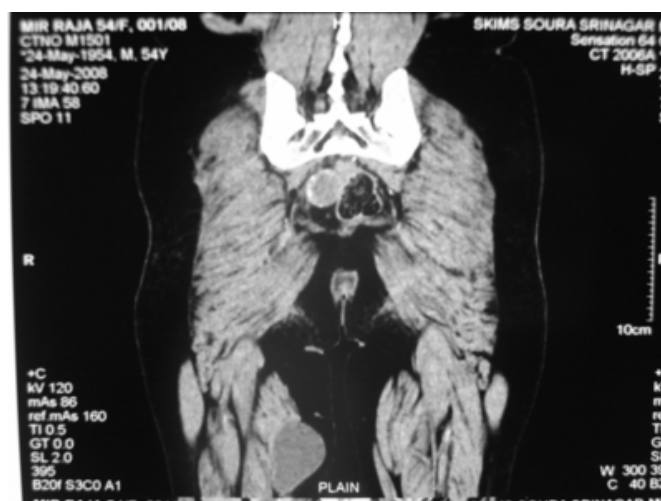

Figure 2

Figure 2: axial contrast enhanced MDCT image showing a hypodence cystic lesion without any wall enhancement in right adductor magnus muscle

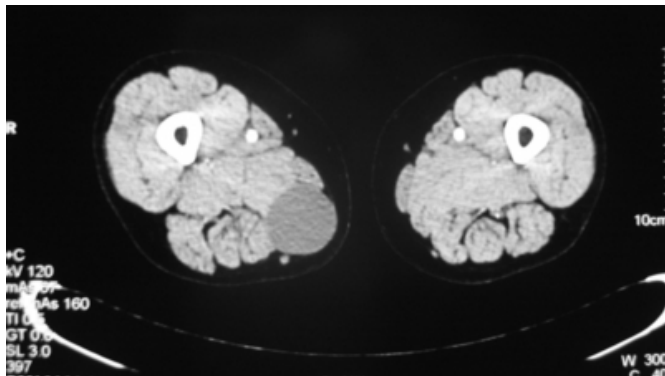
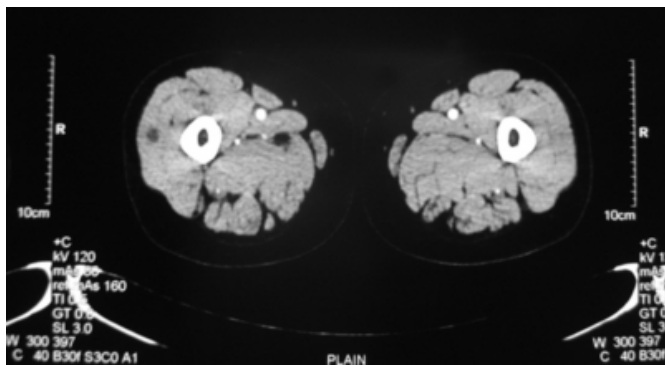


Figure 3

Figure 3: axial contrast enhanced MDCT image showing another small hypodence cystic lesion without any wall enhancement in right vastus lateralis muscle



Patient underwent MRI on Avanto Siemens 1.5 tesla MRI which showed two cystic lesions at same sites as seen on CT scan with one cyst showing a hypointense irregular linear structure on T2W images.(fig.4 & 5)

Figure 4

Figure 4: coronal T2W MR image showing a hyperintense lesion with a hypointense internal membrane in right adductor magnus muscle

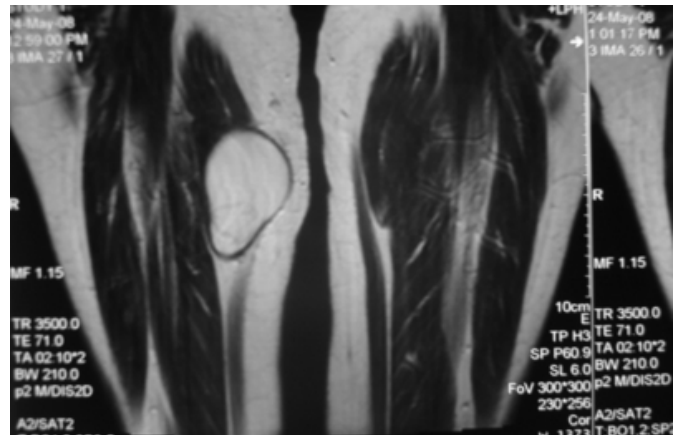
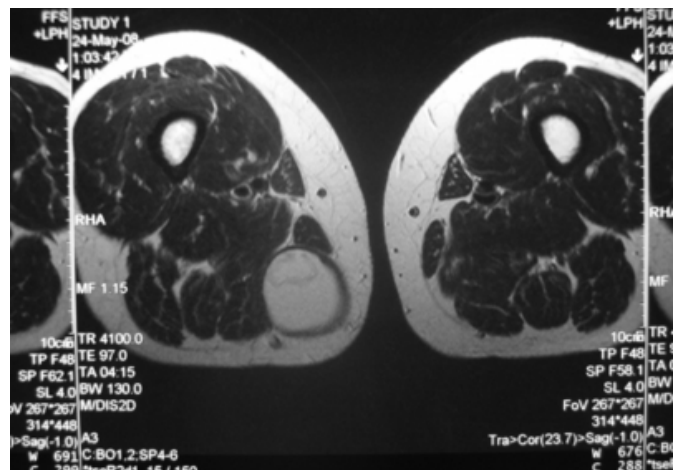


Figure 5

Figure 5: axial T2W MR image showing a hyperintense lesion with a hypointense internal membrane in right adductor magnus muscle



With these features a preliminary diagnosis of intramuscular hydatid was made. Complete excision of the cysts with irrigation of the cyst cavities with hypertonic saline was done; post operative course in hospital was uneventful. Subsequent histopathology confirmed the nature of cysts as hydatid.

DISCUSSION

The infection known as hydatidosis is a zoonotic infection caused by echinococcus granulosus species belonging to cestoda class. The organism lives in the small intestine of the definitive hosts like canines (1). Kashmir is an endemic area for hydatid disease. Literature supports the musculoskeletal involvement in less than 3% of cases though most common

sites of involvement are liver and lung.⁽²⁾ It has been said that the presence of lactic acid does not allow the growth of hydatid cyst in muscle. The hydatid cysts have involved a variety of muscles as per literature; biceps brachii⁽³⁾, sartorius^(4, 5), gluteus⁽⁶⁾, pterygoideus⁽⁷⁾ and soleus muscles⁽⁸⁾, however lower limb involvement is very rare and only few cases have been reported^(9,10,11).

It has been hypothesized that the reason for rarity of primary muscle localization could be due to bypassing through precapillary anastomosis(between pre- and post parenchyma circulation)in liver .⁽¹²⁾ Though the muscle environment is not favourable for hydatid cysts the volume of the muscle mass and its excessive blood supply could explain the rare localization in the proximal muscles of the lower limbs.⁽¹³⁾

Hydatid cysts are best treated by complete excision of the intact cyst wall and so preoperative localization and diagnosis is a must. However large cysts are drained intraoperatively and irrigated with a scolecidal agent such as hypertonic saline and then excised.. If the cyst ruptures and enters circulation it gets disseminated via circulation to distant parts of body.⁽¹⁴⁾ A chance of anaphylactic reaction can develop if the cyst ruptures with leakage of cyst contents⁽¹⁵⁾. Therefore the excision of an intact cyst is usually curative whereas cyst rupture may be fatal.

Ultrasound, CT scan and MRI are used preoperatively to diagnose the hydatid disease. On ultrasound examination it shows a thin or thick wall with internal echoes. Multiple echogenic foci due to hydatid sand may give the “snow storm” sign apperance however the simple cysts may not give this appearance. CT scan can show well-defined cystic lesion with or without daughter cysts and septae or debris and without any enhancement on intravenous contrast. A low signal intensity rim representing the outer pericyst is seen on Magnetic resonance imaging .This low signal is supposed to be due to collagenous nature of this pericyst.⁽¹⁶⁾

Casoni's test is now not used routinely due to false positivity of the test⁽¹⁷⁾.

The recommended treatment of Echinococcus is complete excision of the cyst lining. Thorough irrigation of the cyst cavity with hypertonic saline to decrease the risk of recurrence is done. During surgical intervention all precautions like colored packs, antiscolicidal solutions along with meticulous surgical technique go a long way in the prevention of recurrence of this disease.

The purpose of our case report is that in an area where hydatid disease is a common entity if any patient comes with soft tissue cystic swelling without associated fever, lymphadenopathy, tenderness, or skin changes, the possibility of hydatid cyst should be kept in differentials. Intramuscular infestation may mimic a soft tissue tumor and if we go for hasty open biopsy it can lead to inappropriate cyst rupture with the attendant risks of anaphylaxis and dissemination to other organs. Open biopsy should be avoided. Percutaneous needle biopsy is also not recommended because of the possibility of introducing scolices into the needle tract.

CORRESPONDENCE TO

Dr Aijaz Ahmad Hakeem MD, RADIOLOGIST Deptt.of Radio- diagnosis, SK Institute of Medical Sciences, Srinagar,Kashmir, India 190011. Phone:91 0194-2494265 E-mail: aijazhakeem@yahoo.com

References

1. Eckert J, Deplazes P: Biological, Epidemiological and Clinical Aspects of Echinococcosis, a Zoonosis of Increasing Concern. Clin Microbiol Rev 2004; 17:1, 107-135.
2. Singh CM. Hydatid Cyst of adductor longus. J Indian Med Assoc 1990;88:288.
3. Duncan GJ, Tooke SM. Echinococcus infestation of the biceps brachii. A case report. Clin Orthop Relat Res. 1990;261:247-50.
4. Duygulu F, Karaoglu S, Erdogan N, Yildiz O. Primary hydatid cyst of the thigh: a case report of an unusual localization. Turk J Pediatr. 2006;48:256-9.
5. Tatari H, Baran O, Sanlidag T, Gore O, Ak D, Manisali M, Havitcioglu H. Primary intramuscular hydatidosis of supraspinatus muscle. Arch Orthop Trauma Surg. 2001;121:93-94. doi: 10.1007/PL00013775.
6. Combalia A, Sastre-Solsona S. Hydatid cyst of gluteus muscle. Two cases. Review of the literature. Joint Bone Spine. 2005;72:430-2. doi: 10.1016/j.jbspin.2004.11.007. Epub 2005 Aug 2.
7. Turki I, Turki A, Khochtali H, Bakir D, Bakir A. Pterygoidien hydatid cyst. Rev Stomatol Chir Maxillofac. 2005;106:27-9.
8. Togrul E, Kalaci A, Sarpel Y, Koltay IS, Ozbarlas S. What's your diagnosis? Solitary hydatid cyst of the soleus muscle. Ann Saudi Med. 2004;24:288, 307-9.
9. Chevalier X, Rhamouni A, Bretagne S, Martigny J, Piet BL. Hydatid Cyst of the Subcutaneous Tissue Without Other Involvement: MR Imaging Features. AJR. 1994;163:645-646.
10. Orhan Z, Kara H, Tuzuner T, Sencan I, Alper M. Primary subcutaneous cyst hydatid disease in proximal thigh: an unusual localisation: a case report. BMC Musculoskelet Disor. 2003;7:4-25.
11. Kazakos CJ, Galanis VG, Verettas DA, Polychronidis A, Simopoulos C. Primary hydatid disease in femoral muscles. J Int Med Res. 2005;33:703-6.
12. Verasaci A, Scuderi G, Rosato A, Angio LG, Oliva G, Sfuncia G, et al. Rare localizations of echinococcosis ; personal experience. ANZ J Surg 2005;75:986-91.

13. Mseddi M, Mtaoumi M, Dahmene J, Ben Hamida R, Siala A, Moula T, et al, hydatid cysts in muscles: eleven cases. *Rev Chir Orthop Reparatrice Appar Mot* 2005;91:267-71
14. Schiller, C.F.: Complication of Echinococcus cyst rupture, *JAMA* 195: 158, 1966.
15. Heinze, J. Junginger, W., Muller, G., and Gaebel, G. Anaph. Shock during extirpation of an E.G. cyst of the thigh. *Anesthesist* 36: 659, 1987.
16. Pedrosa I, Saiz A, Arrazola J, Ferreiros J, Pedrosa CS. Hydatid disease: Radiological and pathological features and complications. *Radiographics* 2000;20:795-817.
17. Barnes SA, Lillemo KD. Liver abscess and hydatid disease. In: Schwasy Z and Ellis, editors. *Maindot's abdominal operations* 10 th ed. Appleton and Lange: 1997. p. 1534-44.

Author Information

Aijaz Hakeem, MD

Department of Radio- diagnosis, SK Institute of Medical Sciences

Hakim Shafi, MD

Department of General medicine, SK Institute of Medical Sciences

Tariq A. Gojwari, MD

Department of Radio- diagnosis, SK Institute of Medical Sciences

Shubana Rasool, MD

Department of General medicine, SK Institute of Medical Sciences

Muneer Ahmad, MS

Department of Cardio vascular & thoracic surgery, SK Institute of Medical Sciences